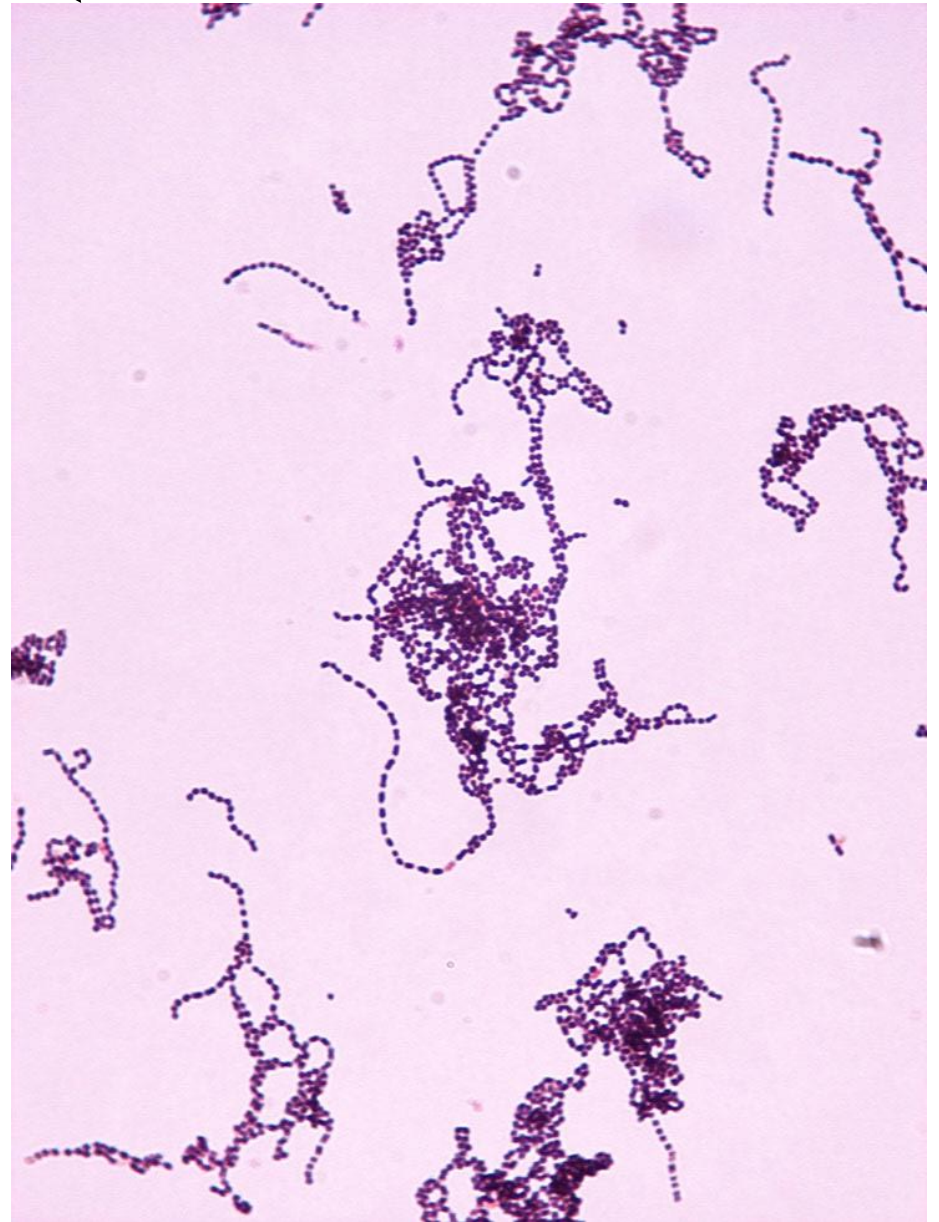
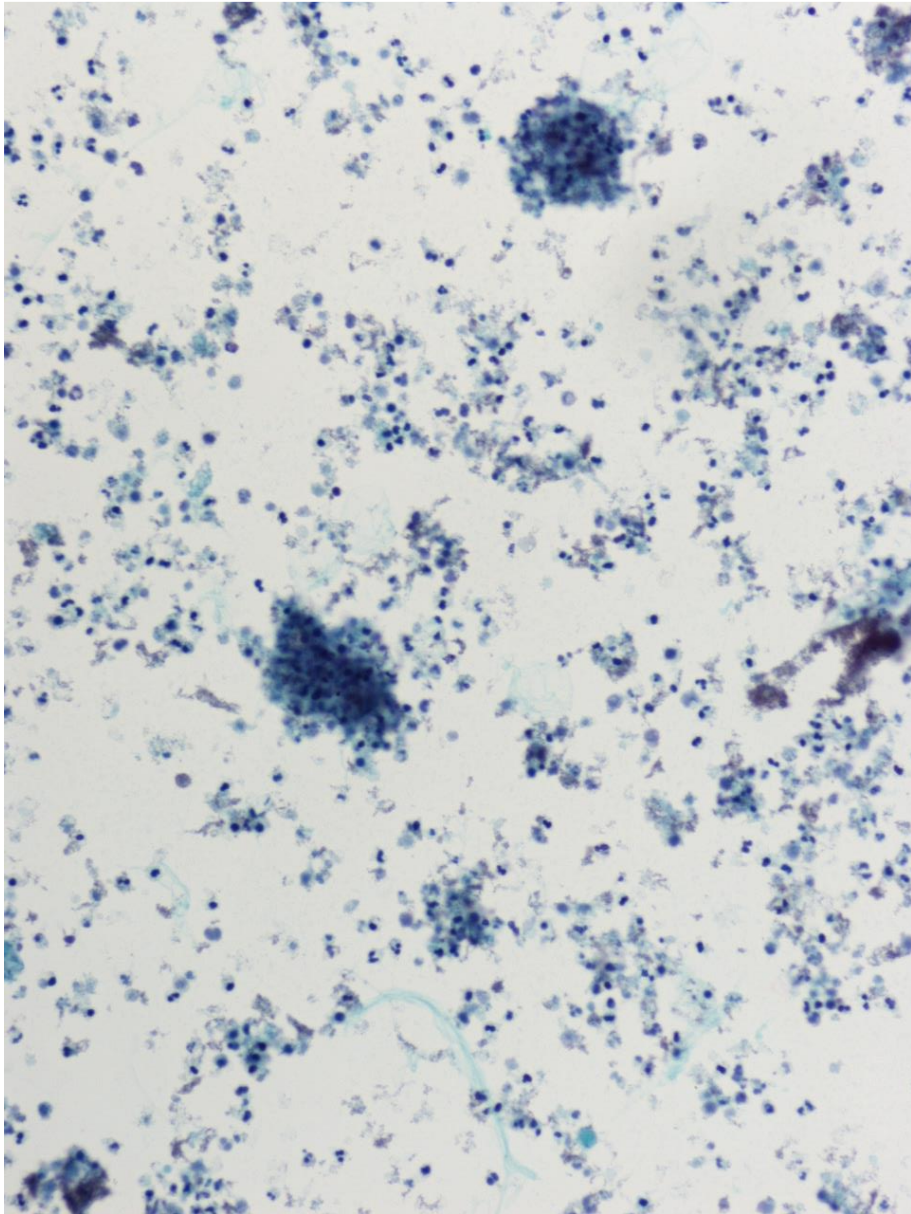


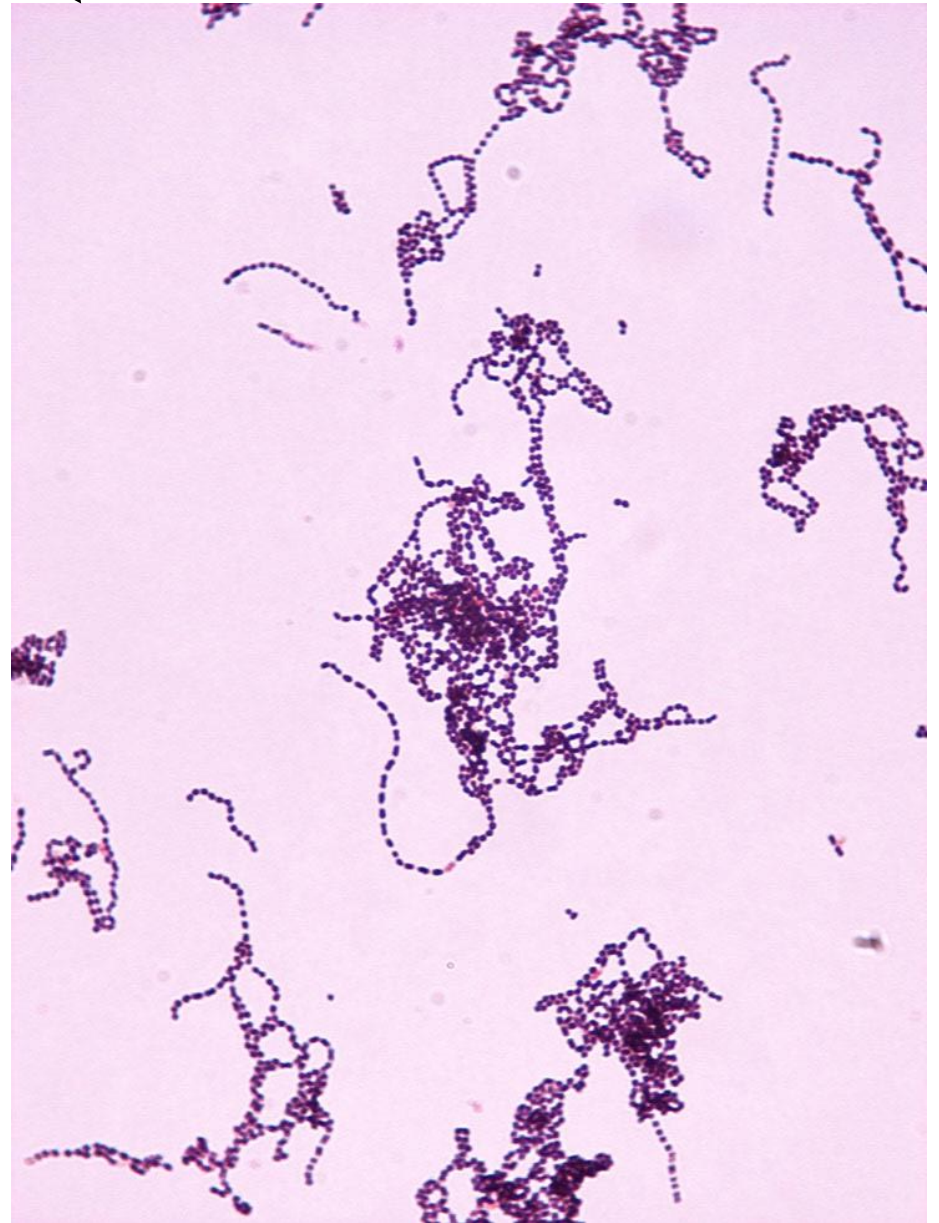
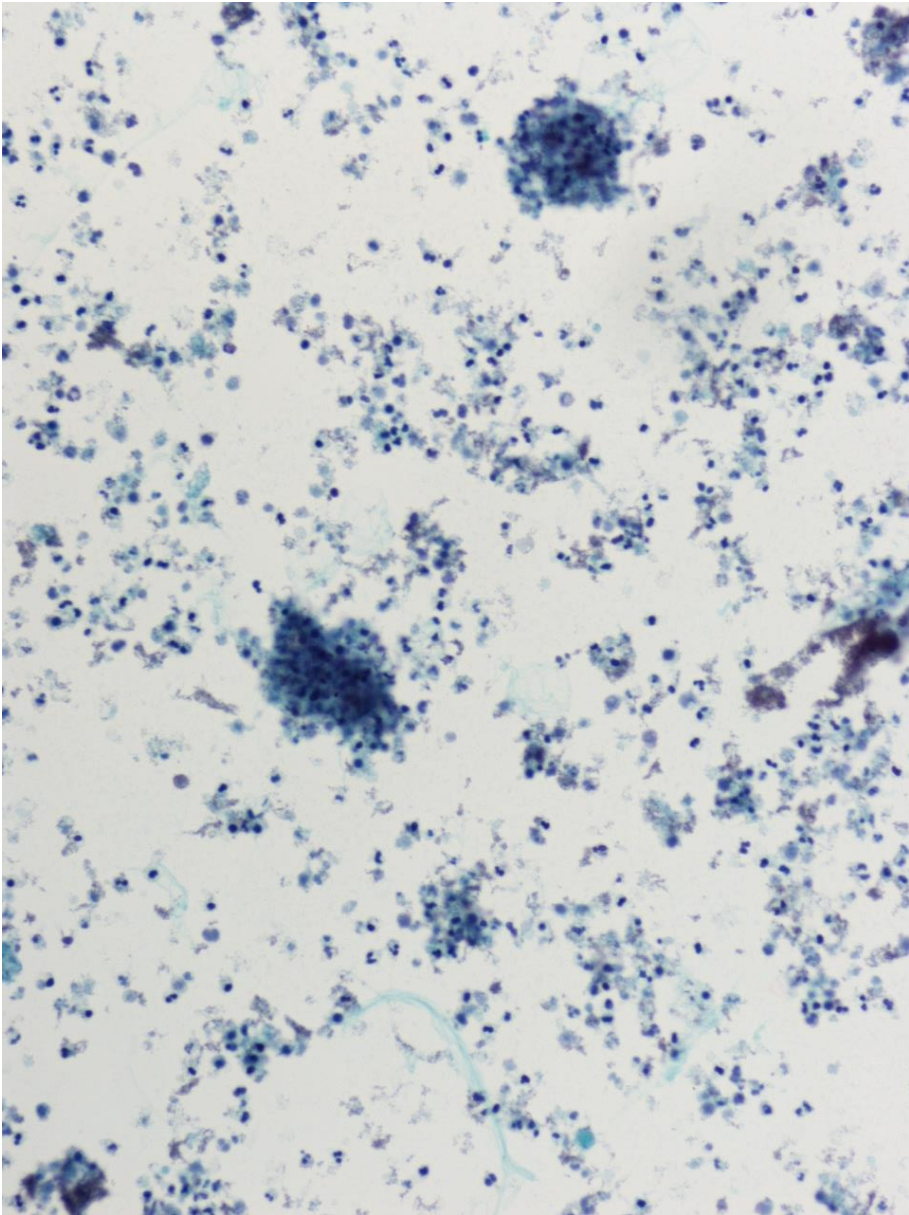
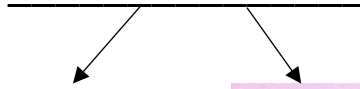
# BACTERIA SLIDES

Cocci





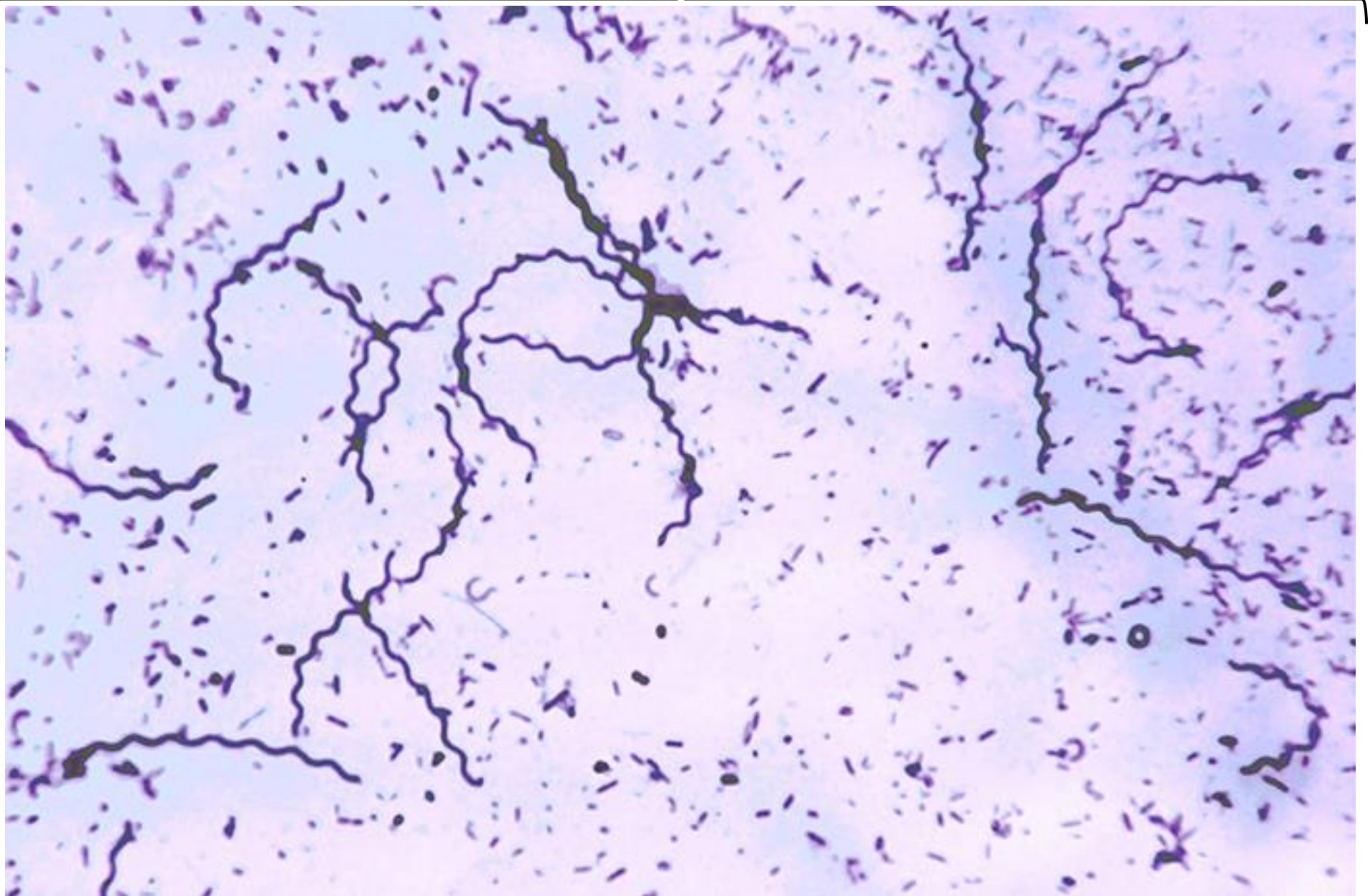
## BACTERIA SLIDES





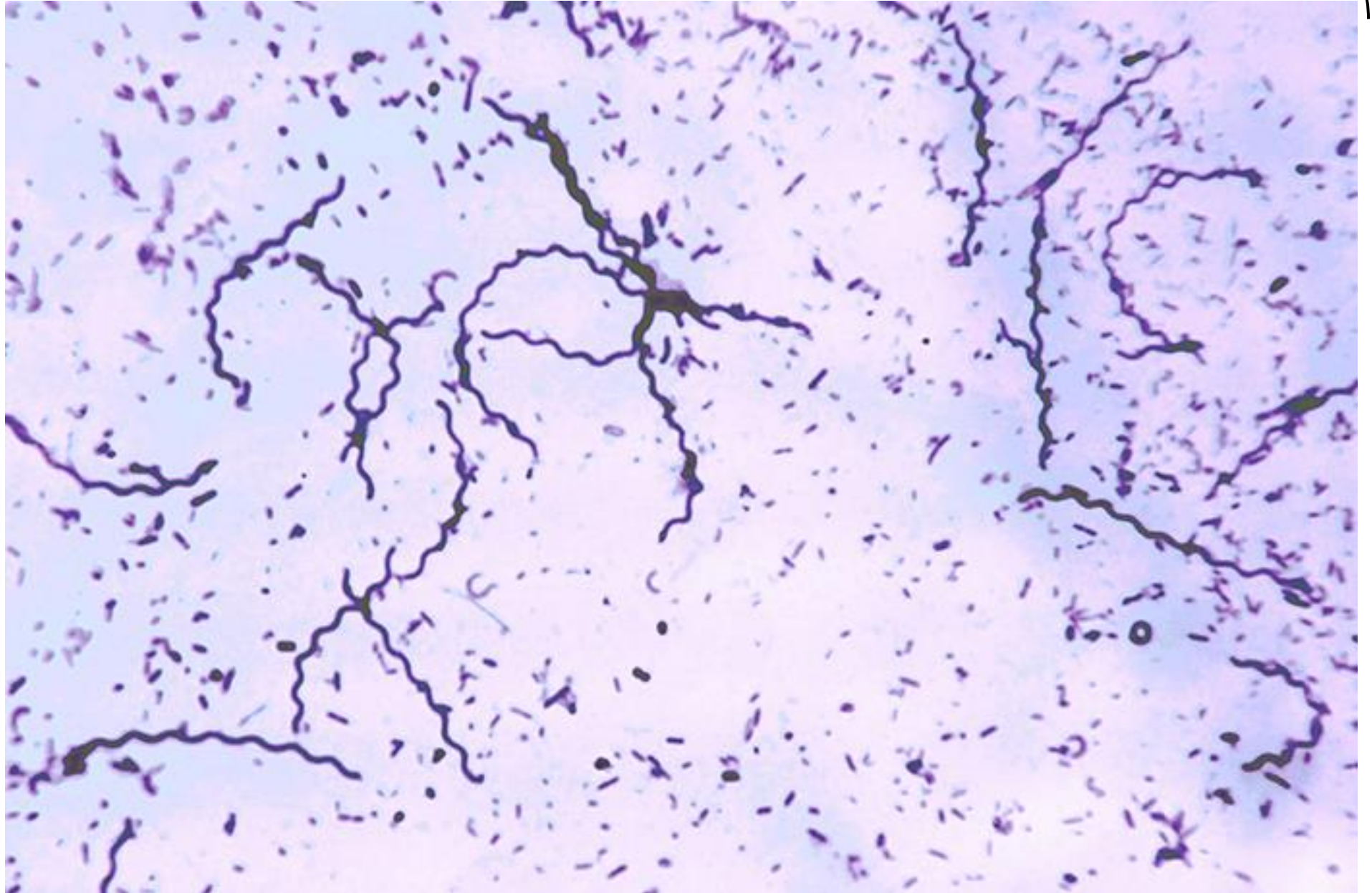
# BACTERIA SLIDES

Spirilla



## BACTERIA SLIDES

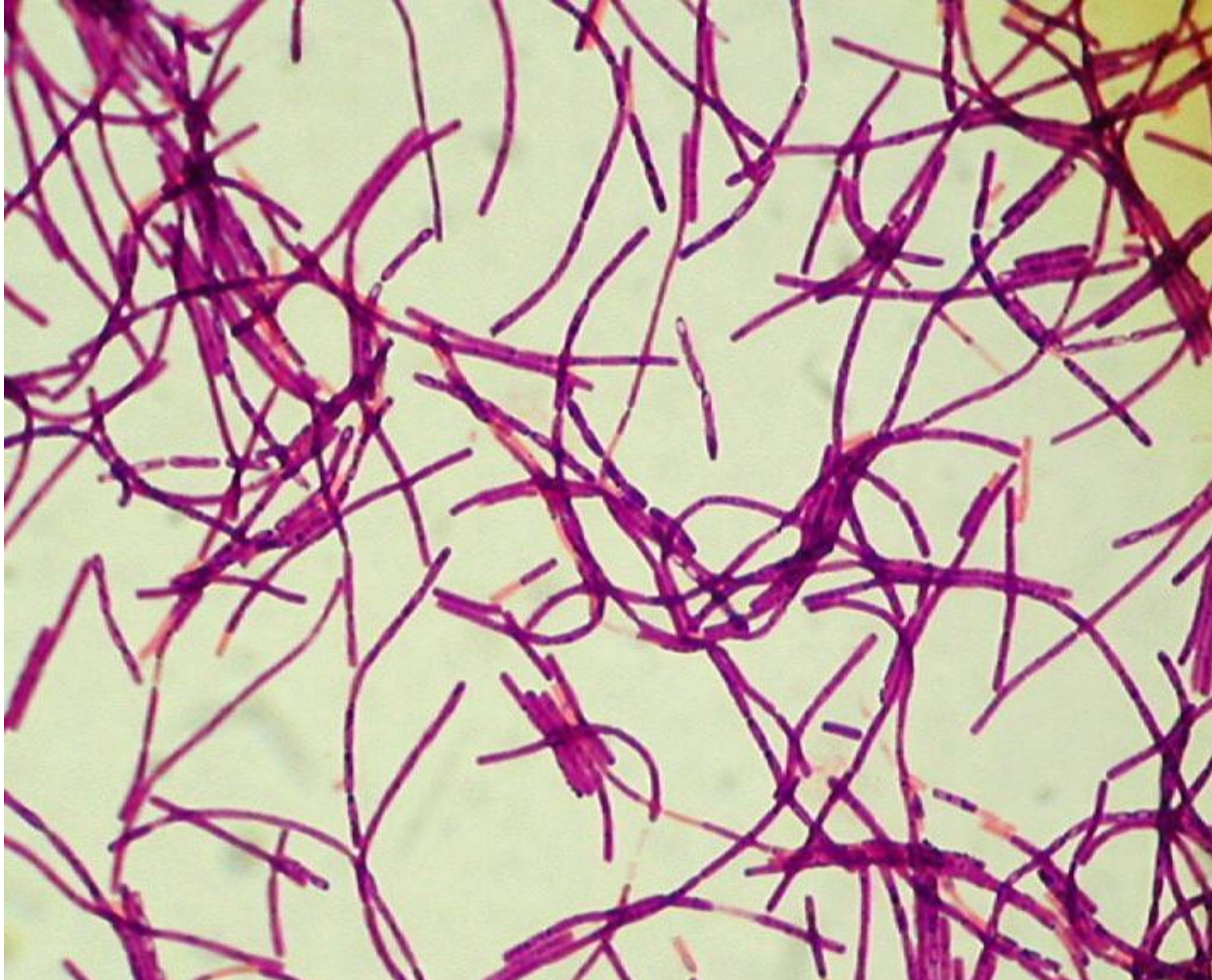---





# BACTERIA SLIDES

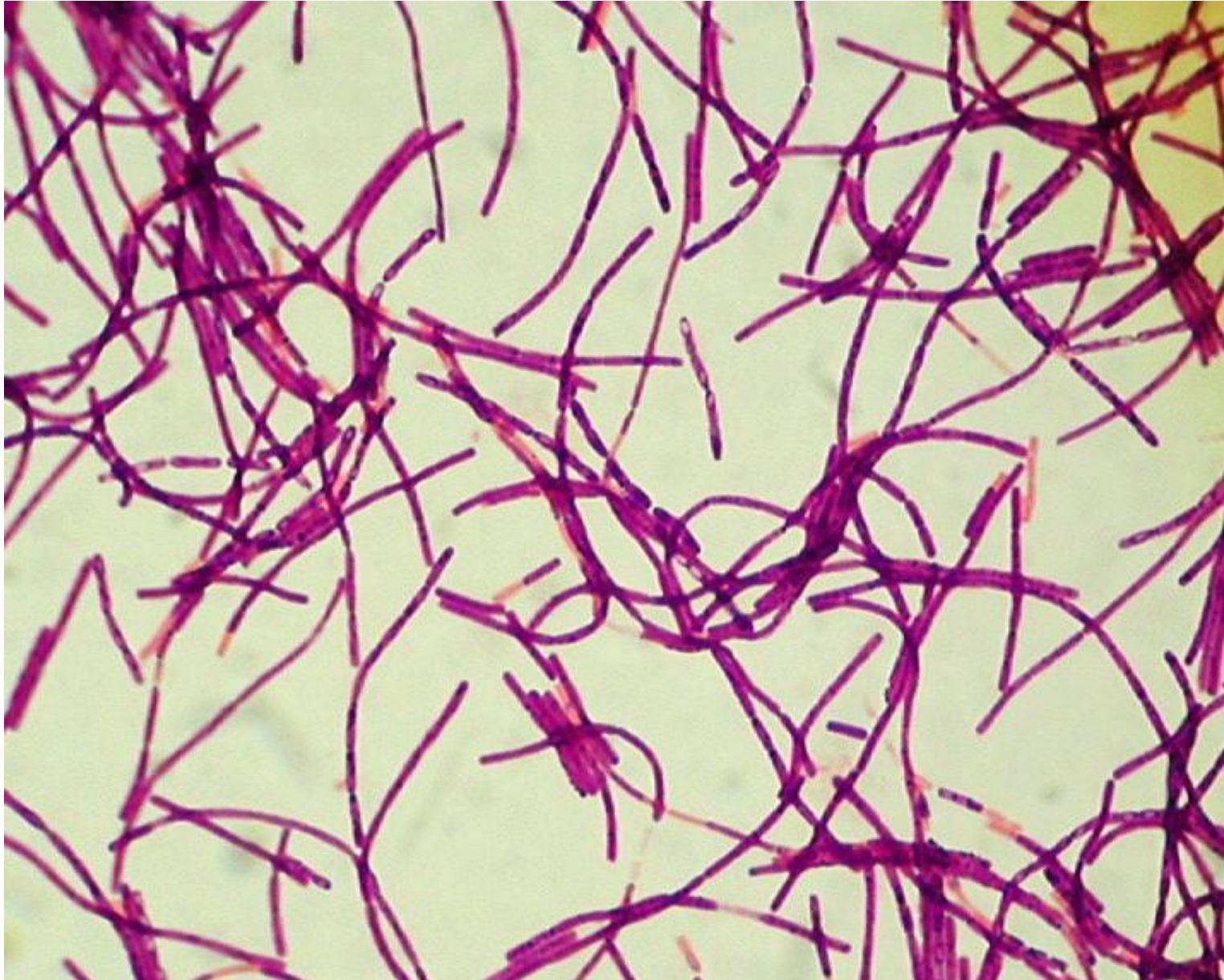
Bacillus





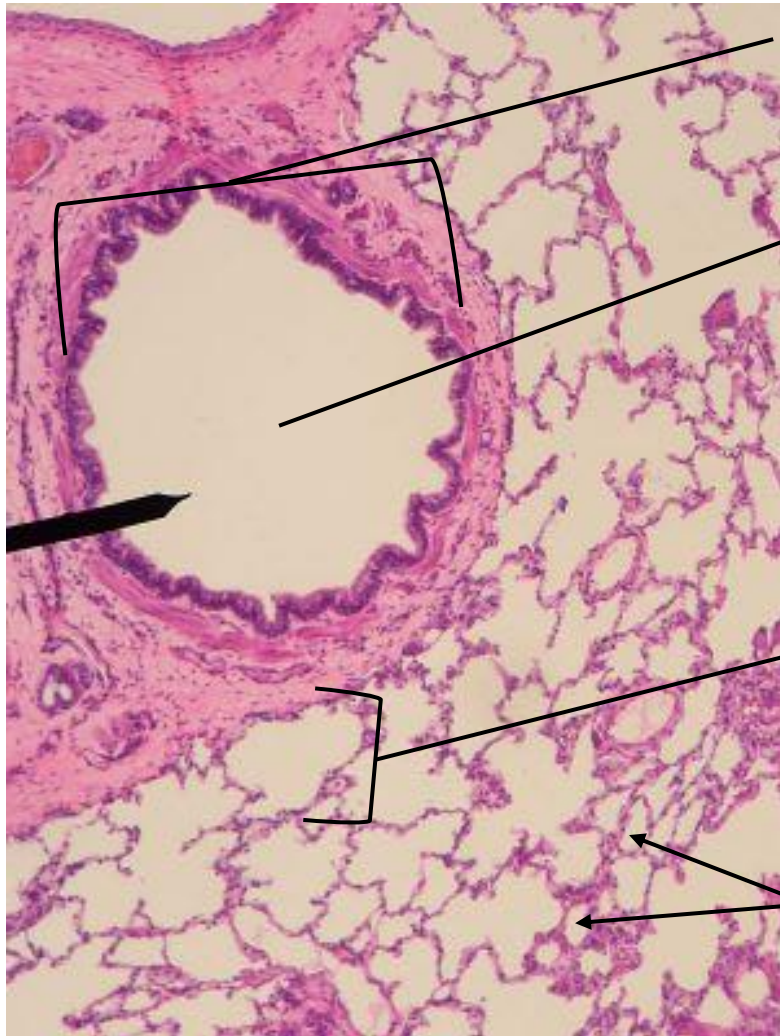
## BACTERIA SLIDES

---





## LUNG SLIDE



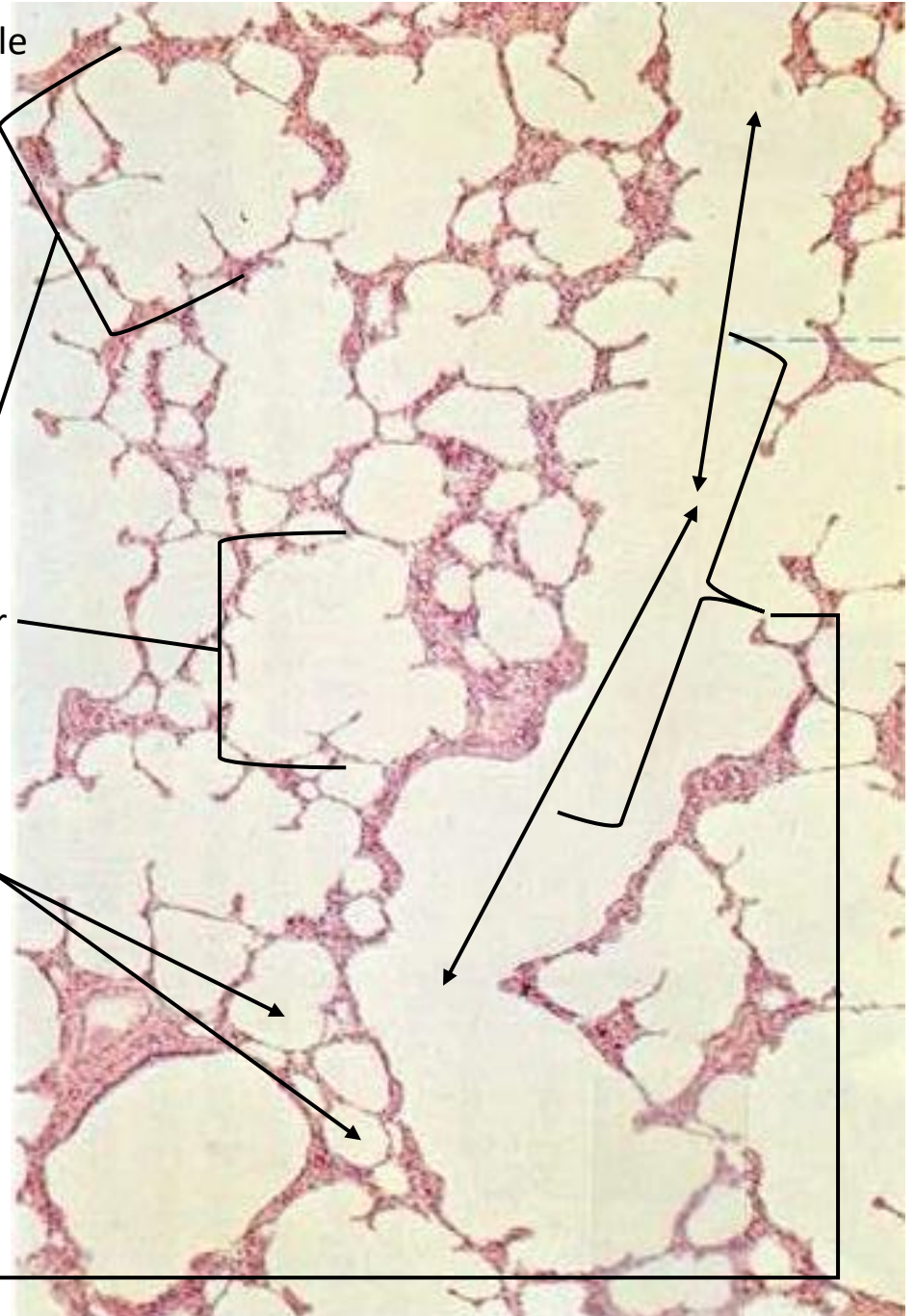
Bronchiole

Lumen

Alveolar  
Sac

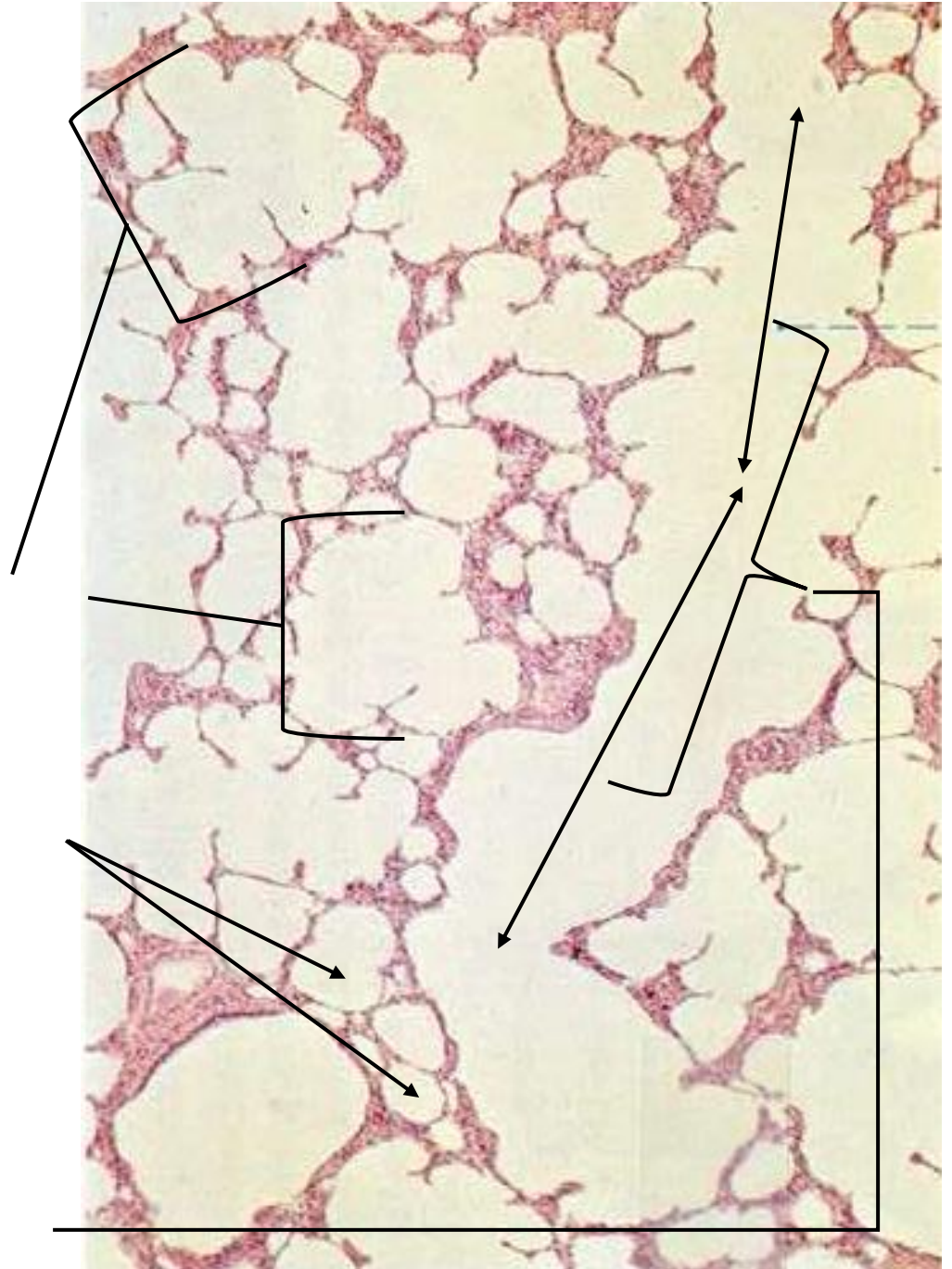
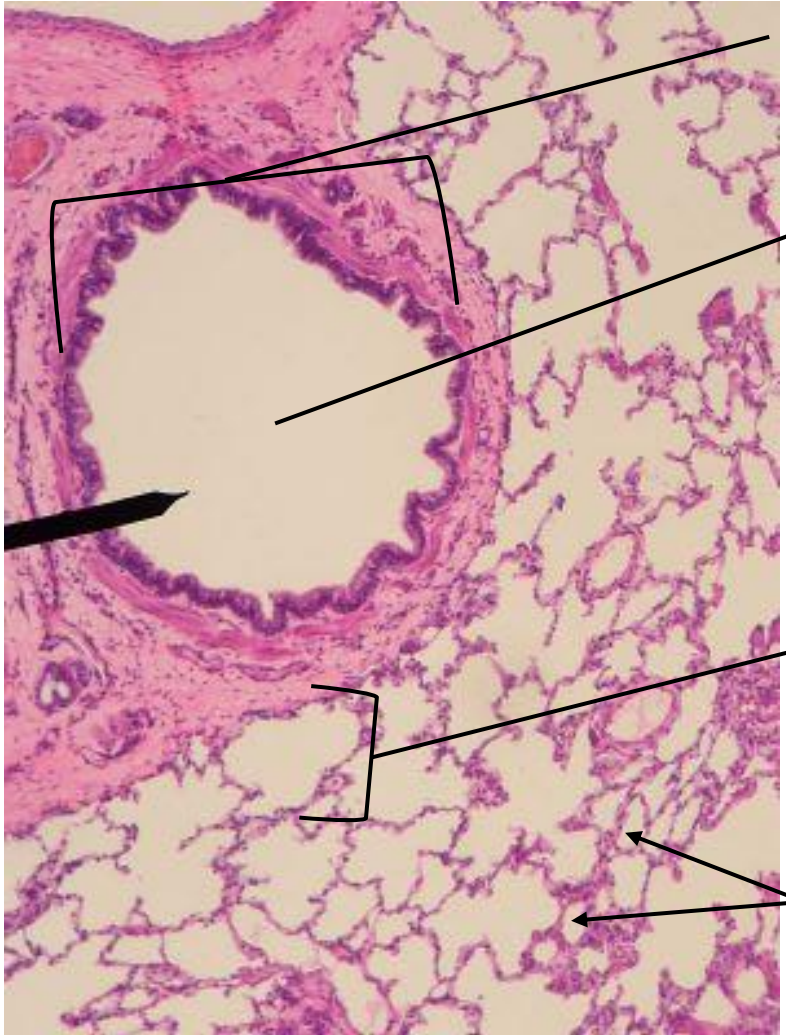
Alveoli

Alveolar  
Duct



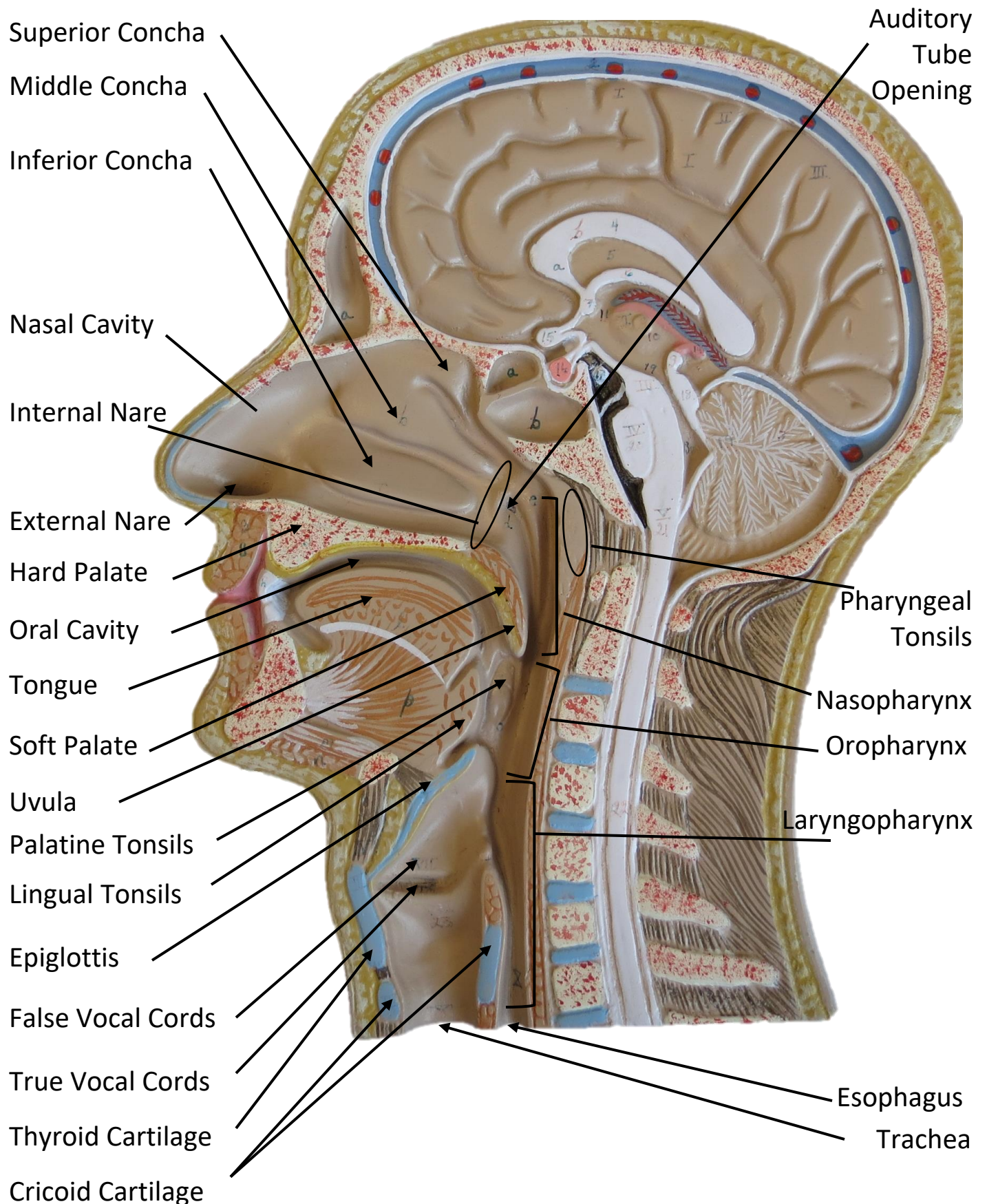


## LUNG SLIDE



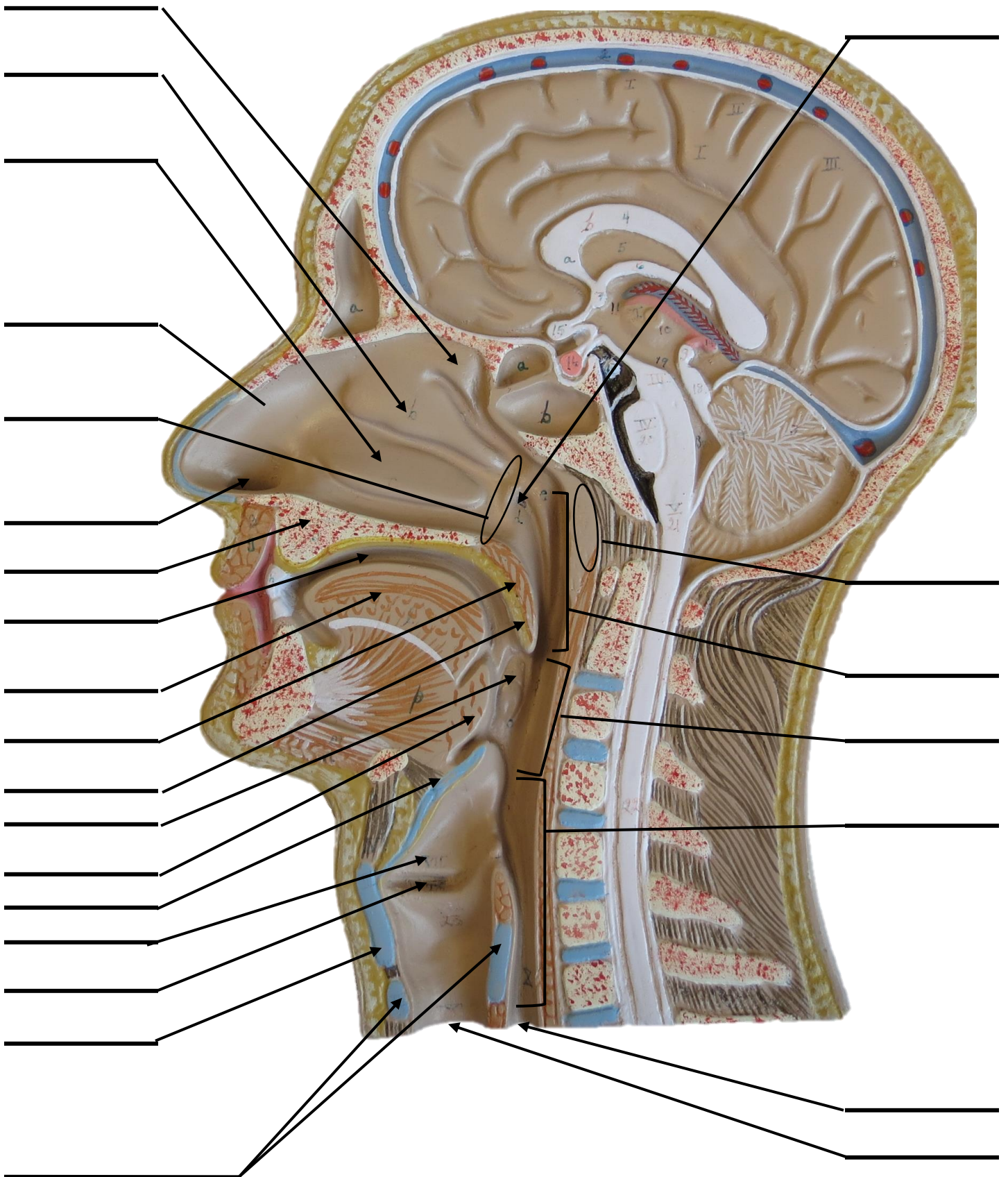


# SAGITTAL SECTION OF HUMAN HEAD MODEL





# SAGITTAL SECTION OF HUMAN HEAD MODEL

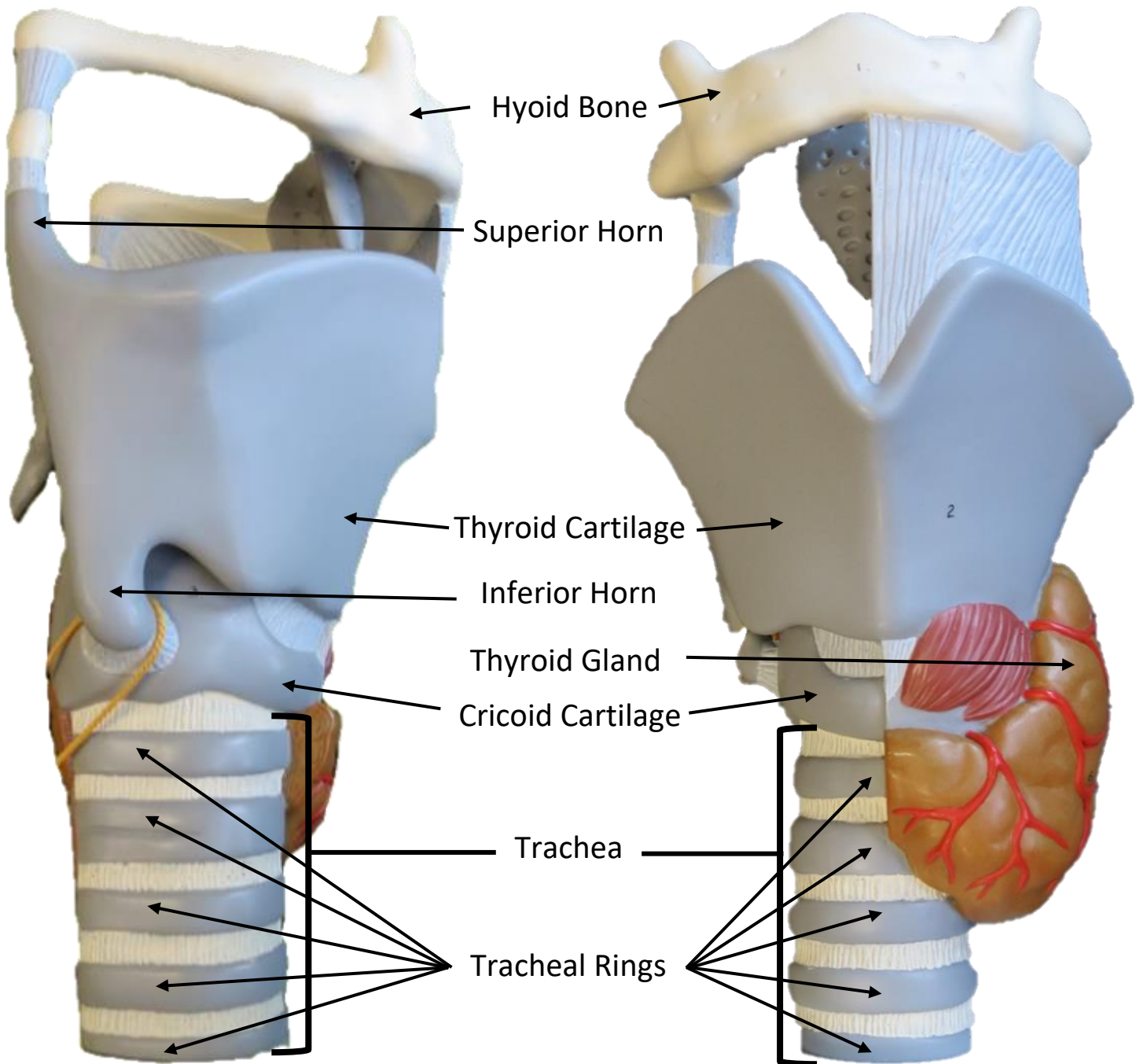




# LARYNX MODEL

**Side View**

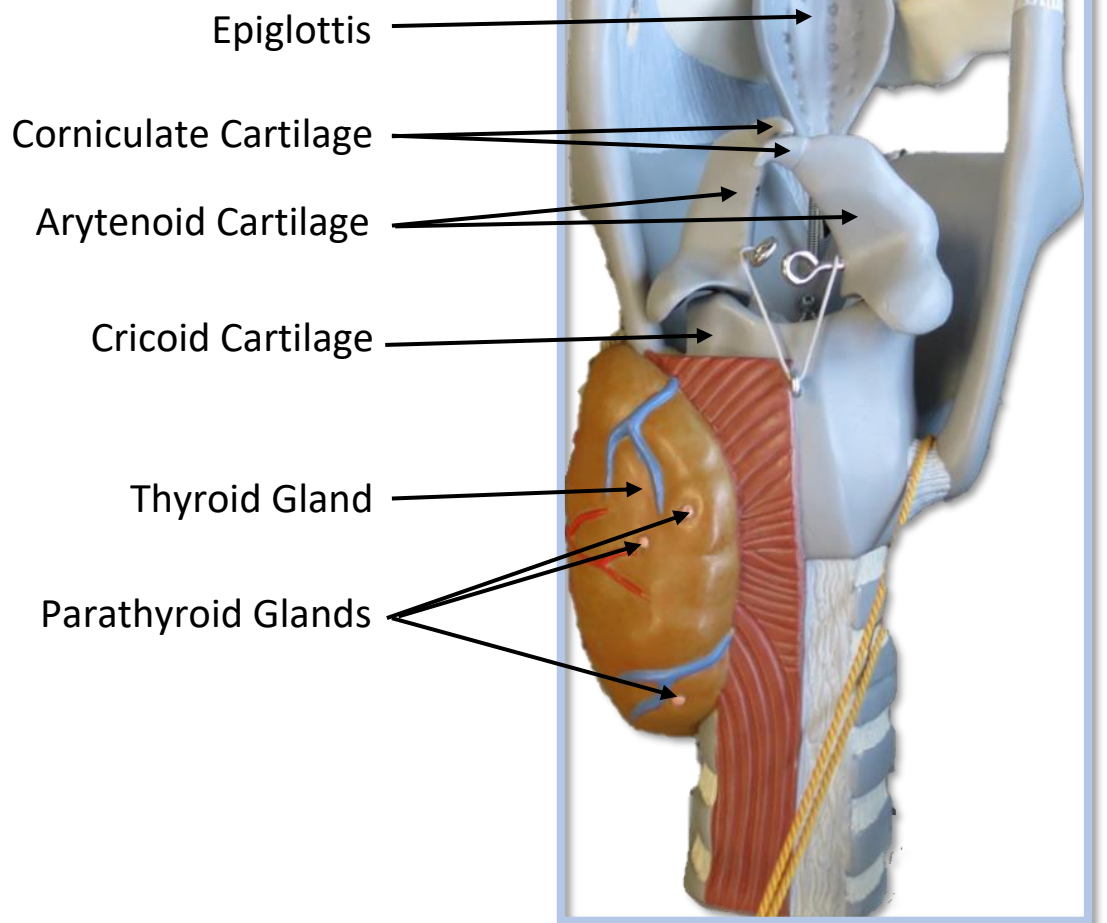
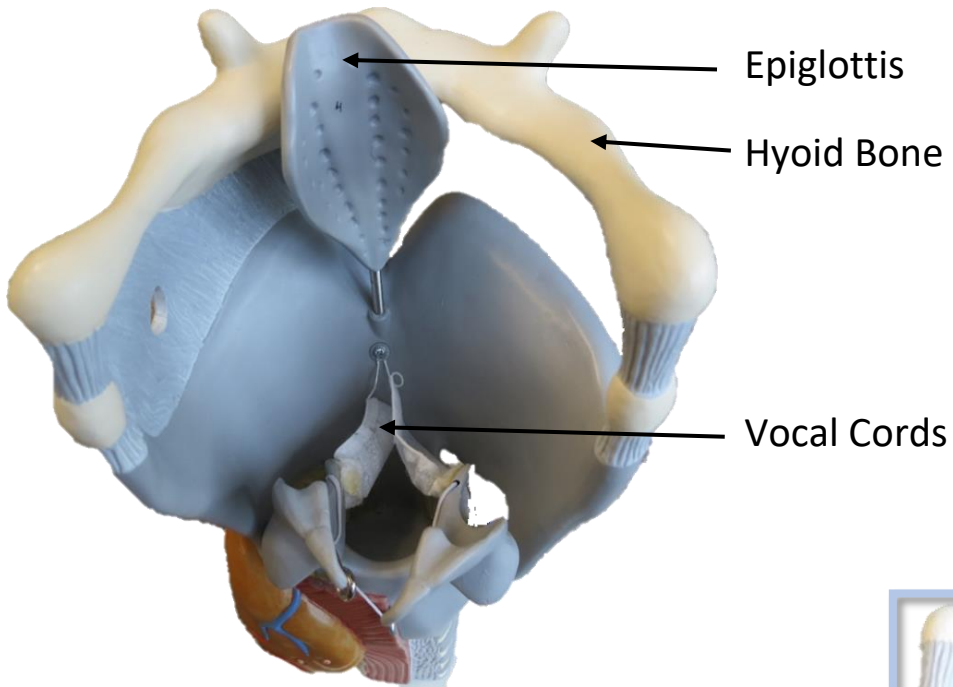
**Anterior View**





# LARYNX MODEL

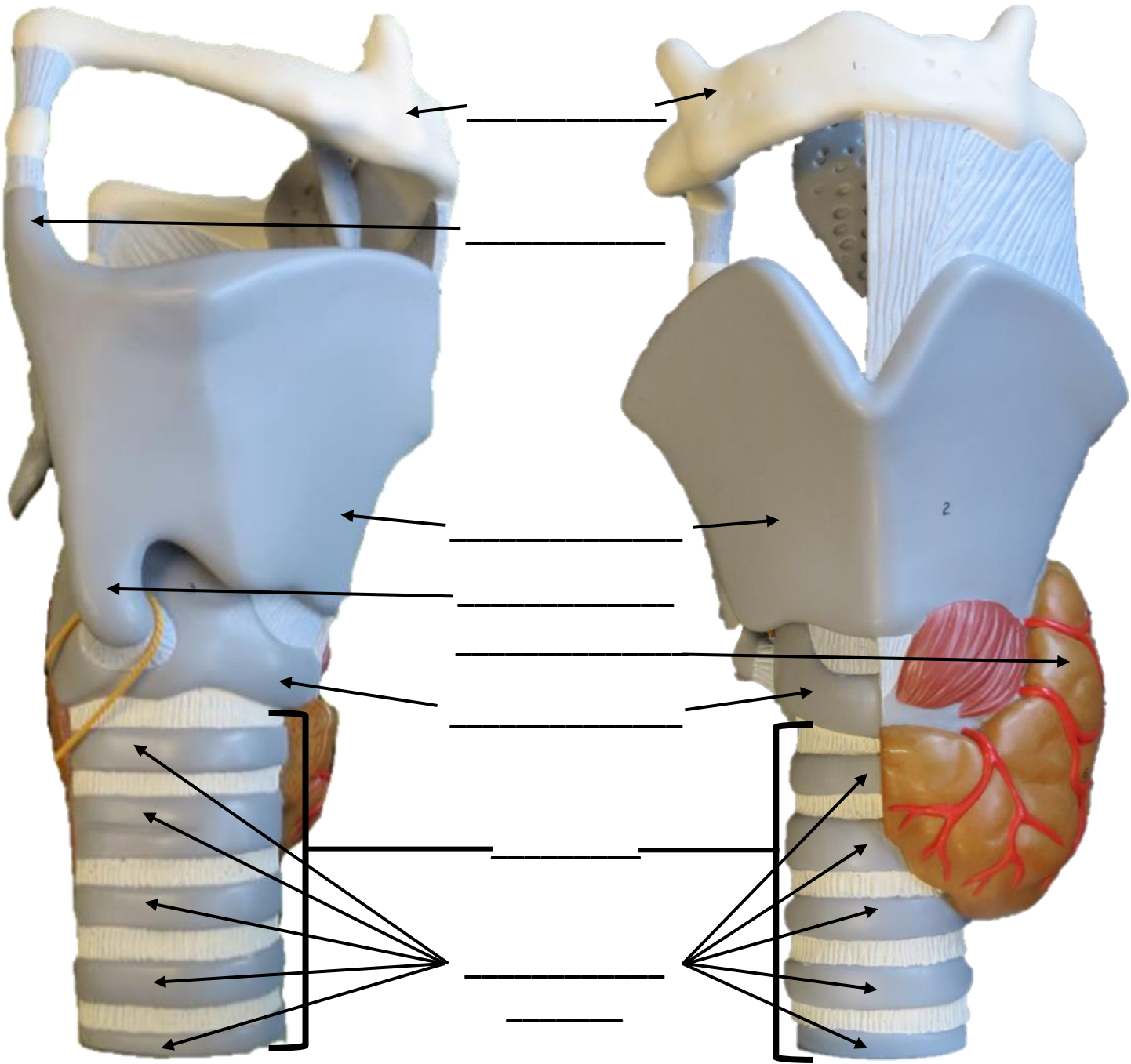
## Posterior View



# LARYNX MODEL

Side View

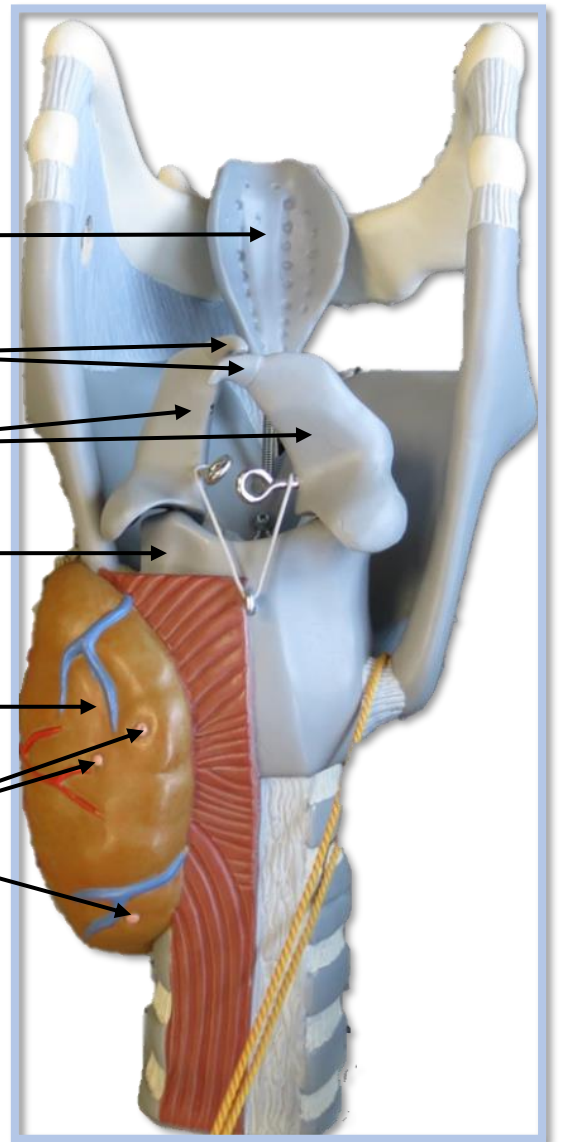
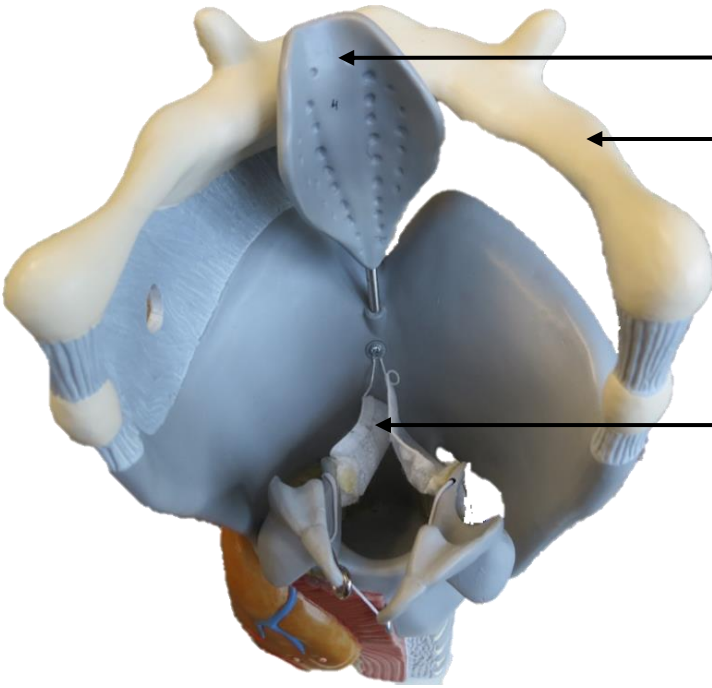
Anterior View





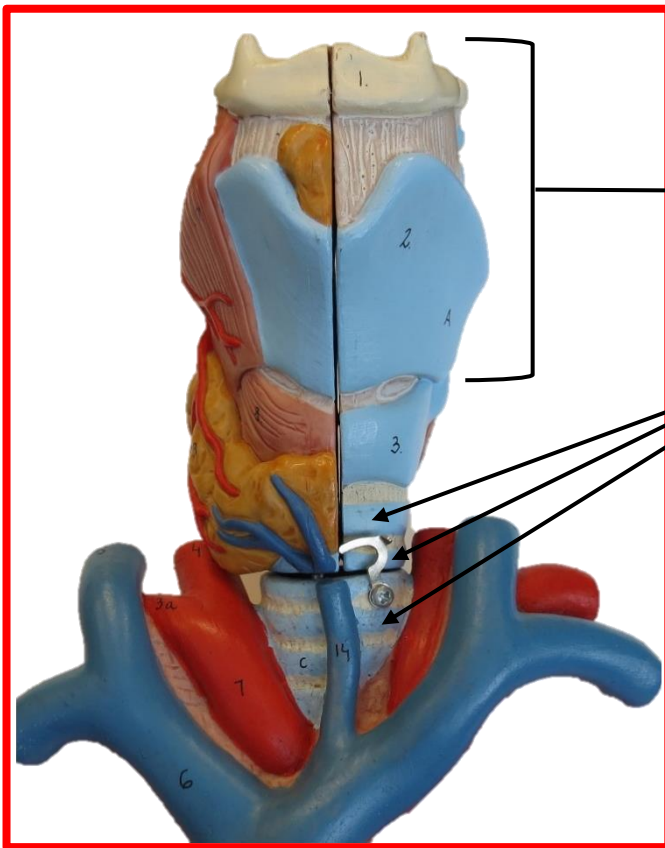
# LARYNX MODEL

## Posterior View



- 1. Epiglottis
- 2. Aryepiglottic fold
- 3. Arytenoid cartilage
- 4. Cricoid cartilage
- 5. Thyroid cartilage
- 6. Trachea
- 7. Cricoid cartilage
- 8. Thyroid cartilage
- 9. Trachea
- 10. Cricoid cartilage

# HUMAN HEART & LUNGS MODEL



Larynx

Tracheal Rings Found on the Trachea

Left Superior Lobe

Left Inferior Lobe

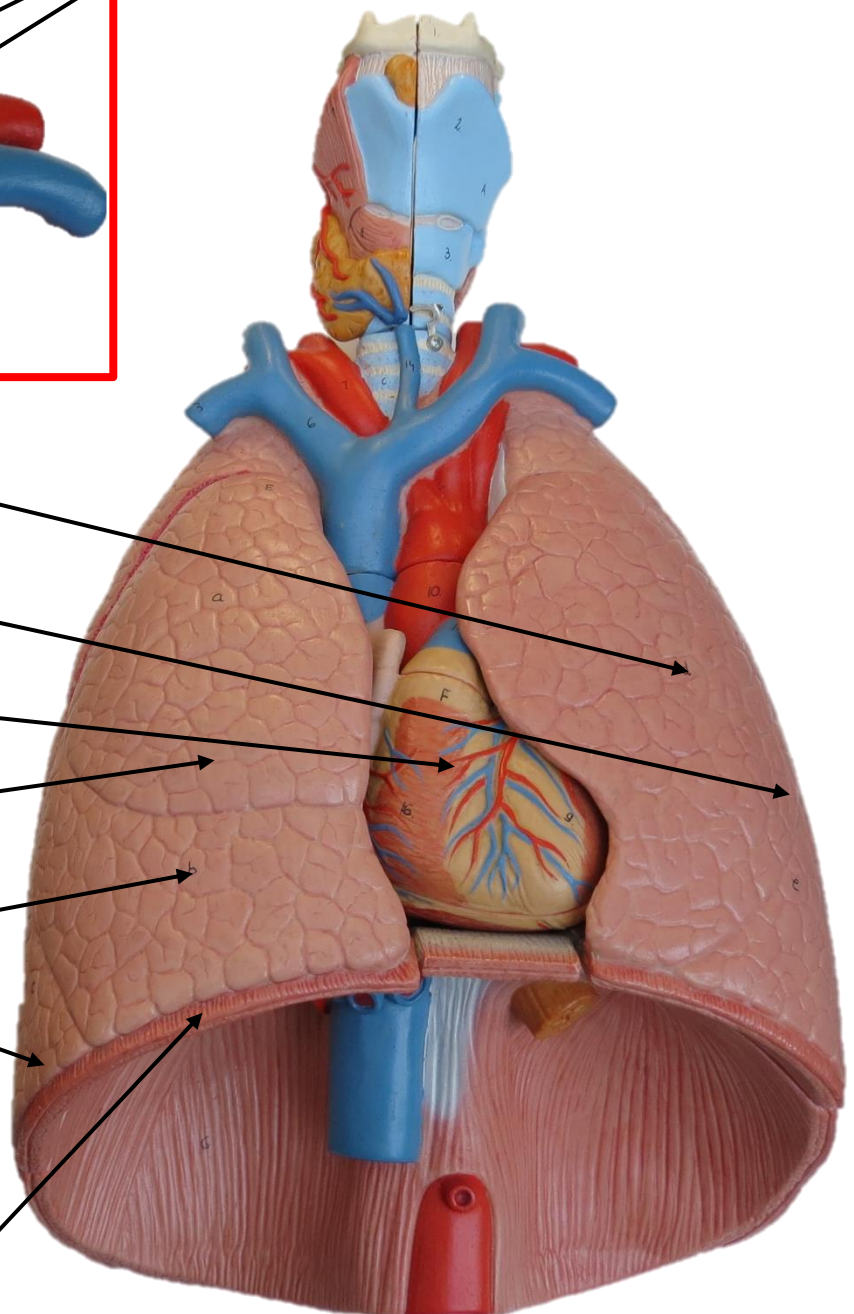
Heart

Right Superior Lobe

Right Middle Lobe

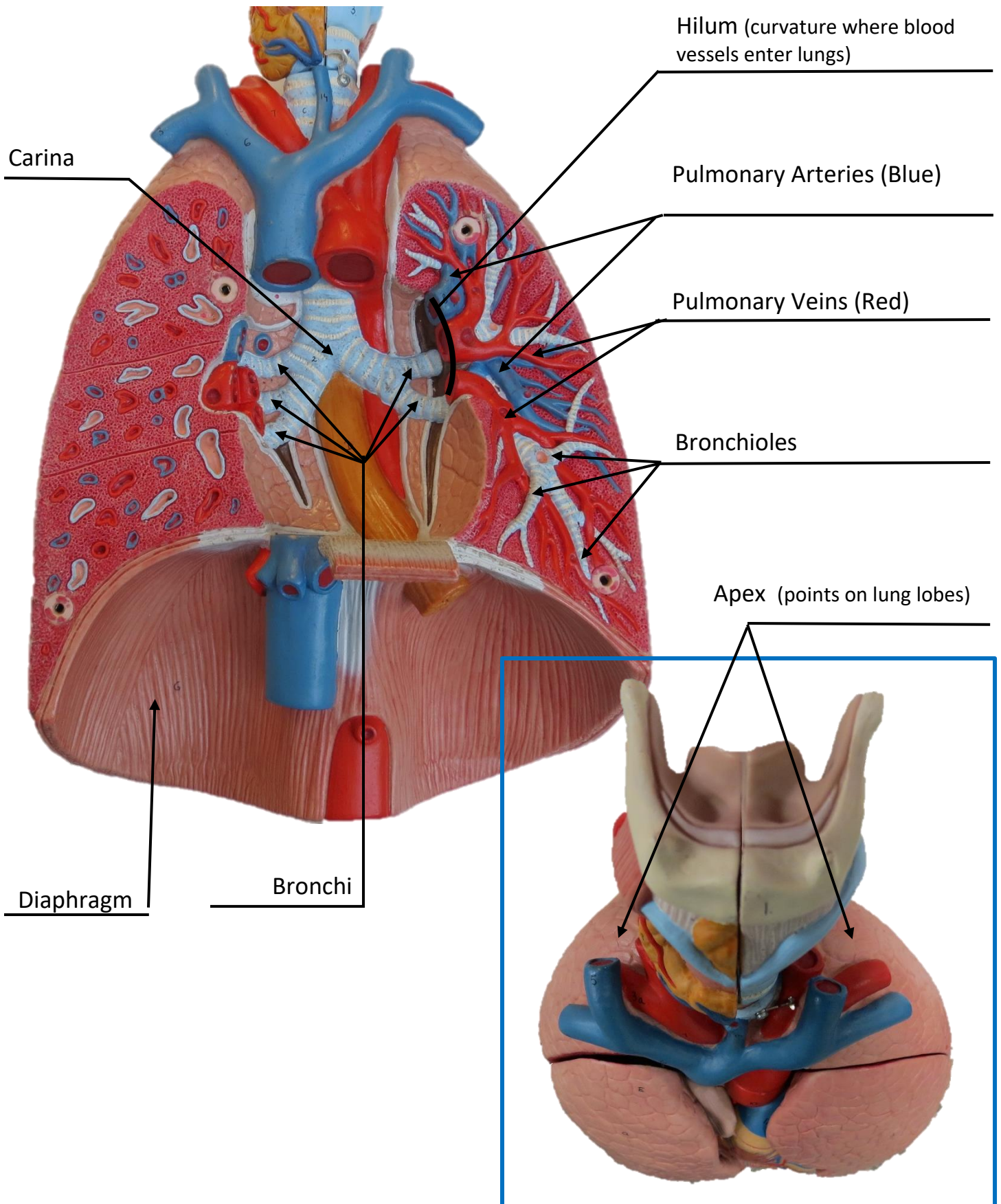
Right Inferior Lobe

Diaphragm



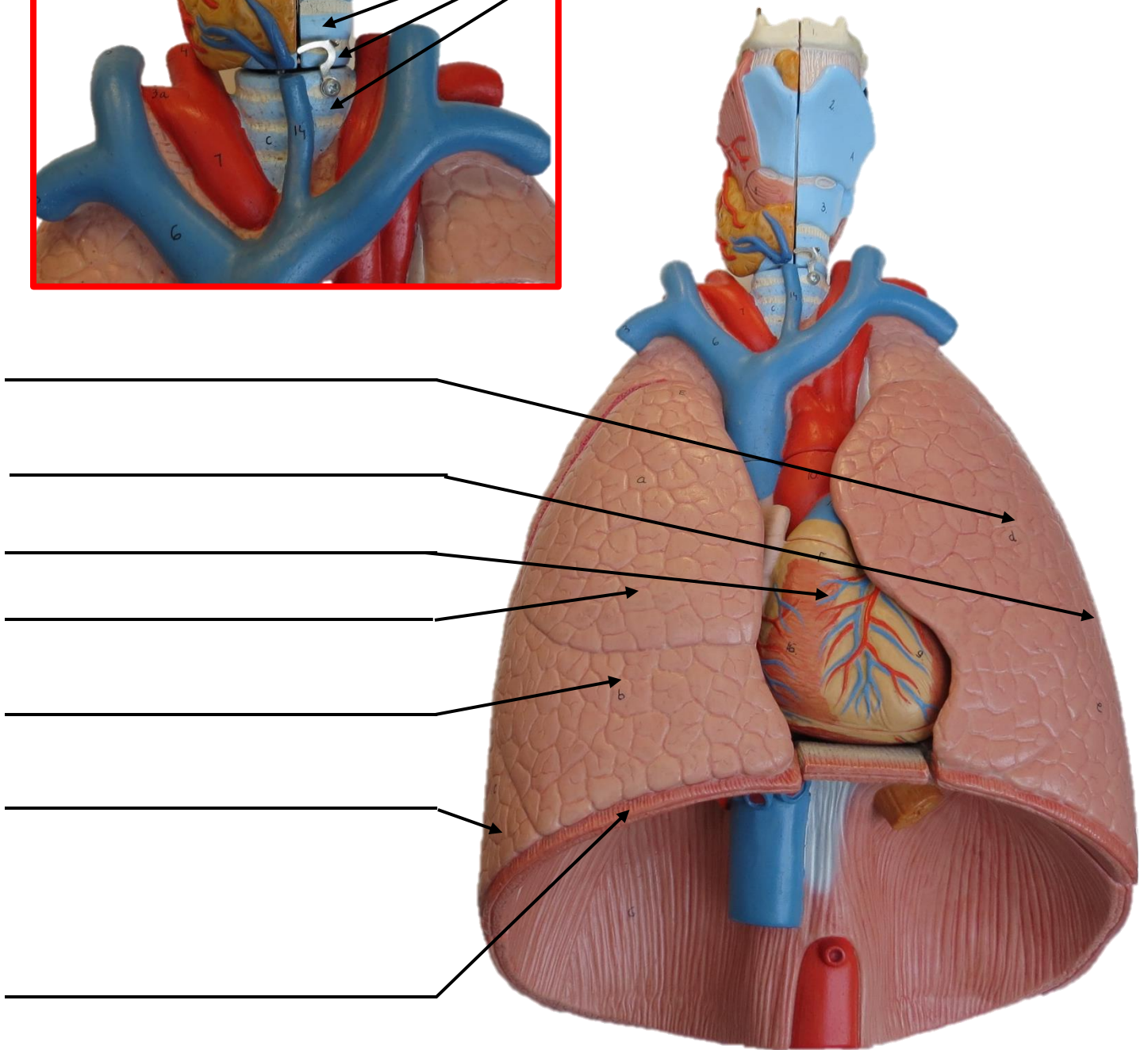
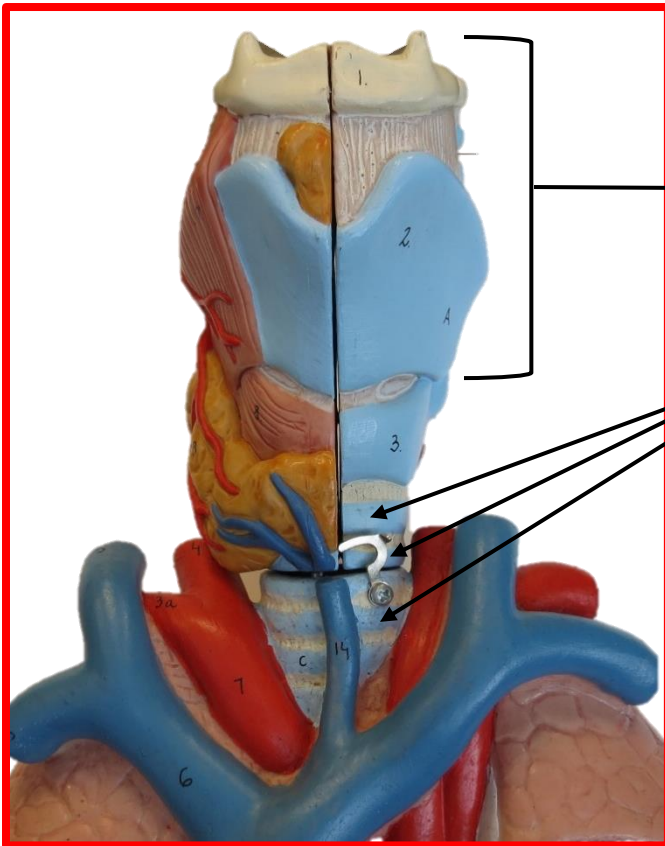


# HUMAN HEART & LUNGS MODEL



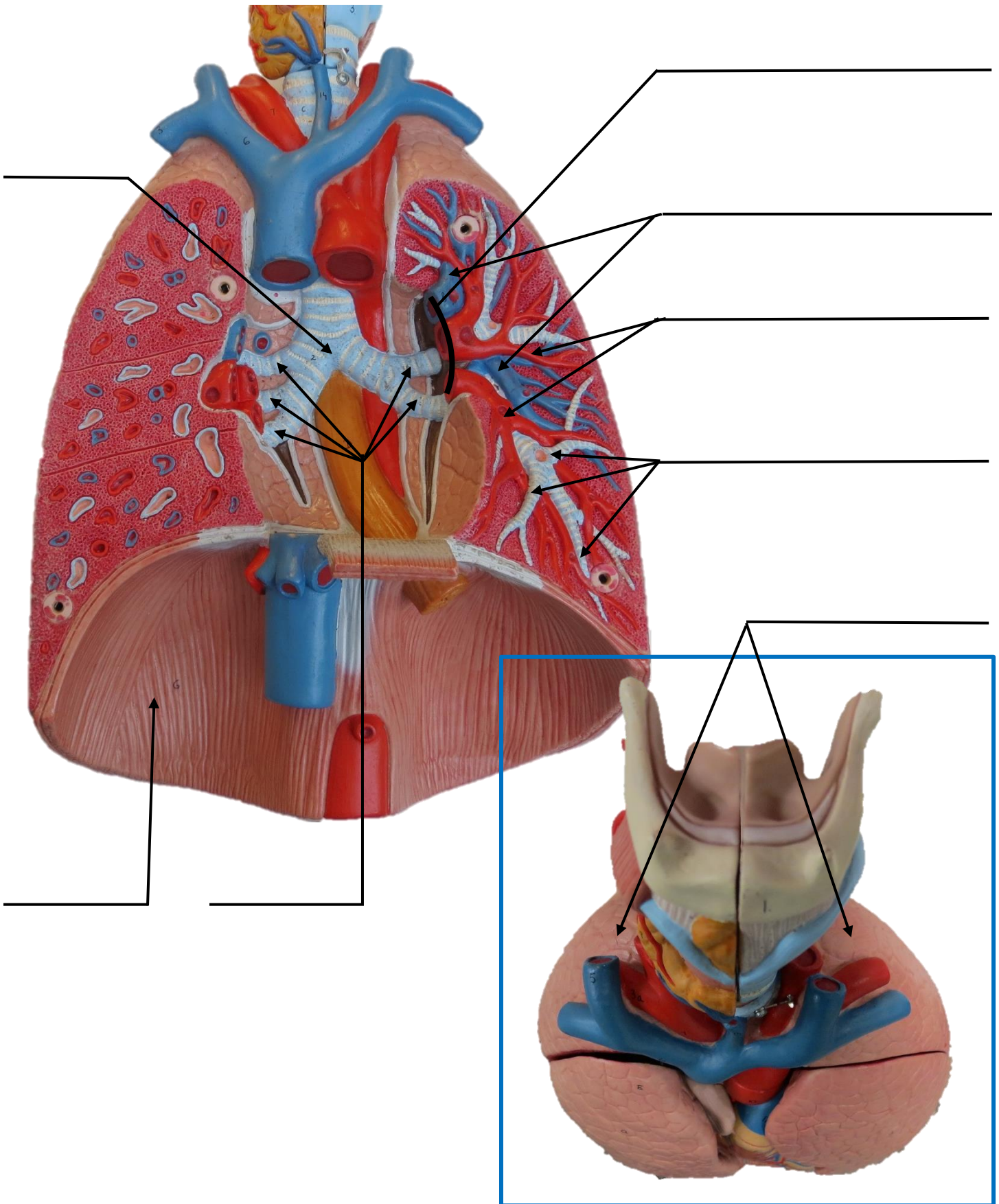


# HUMAN HEART & LUNGS MODEL

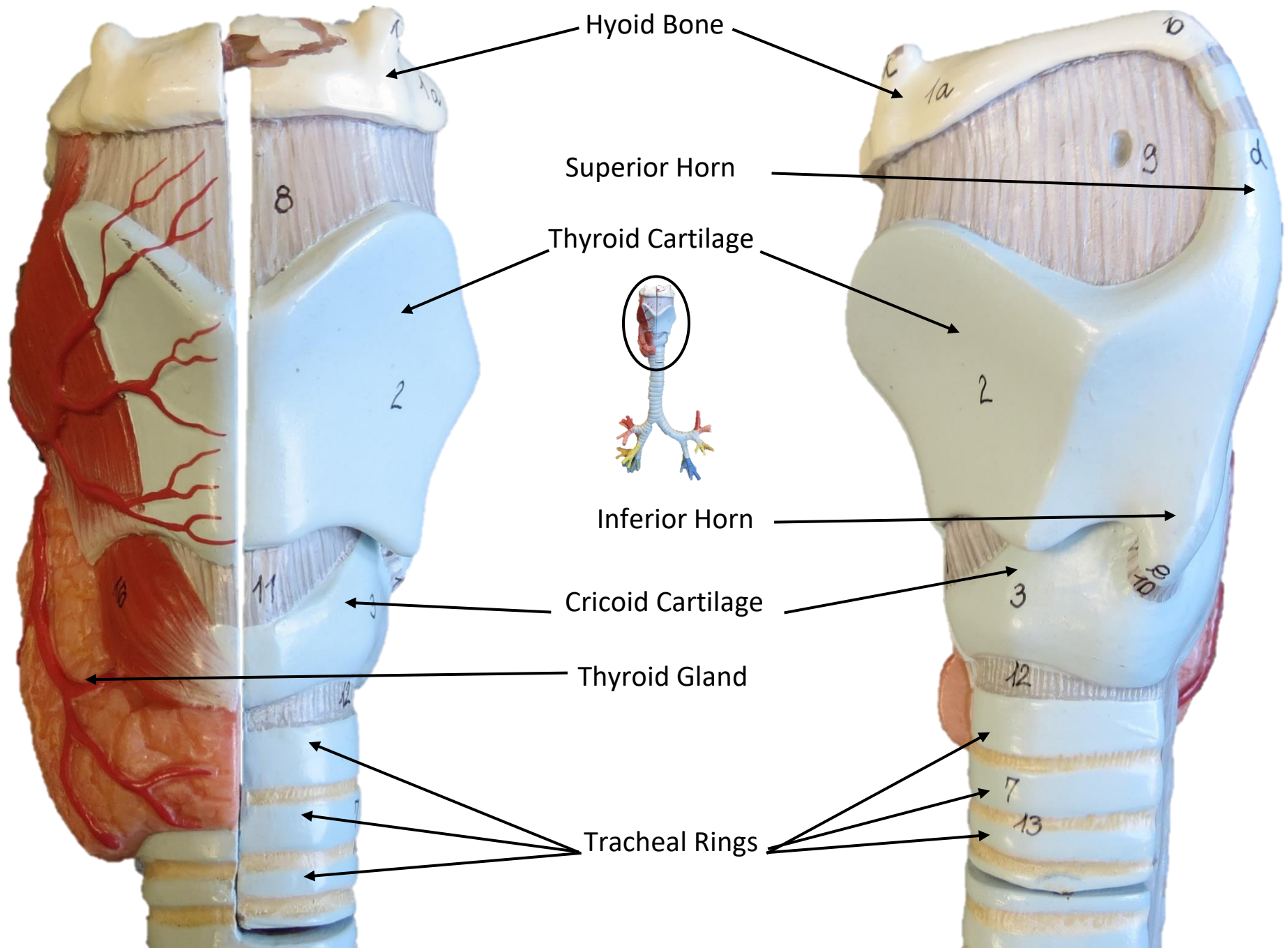




# HUMAN HEART & LUNGS MODEL



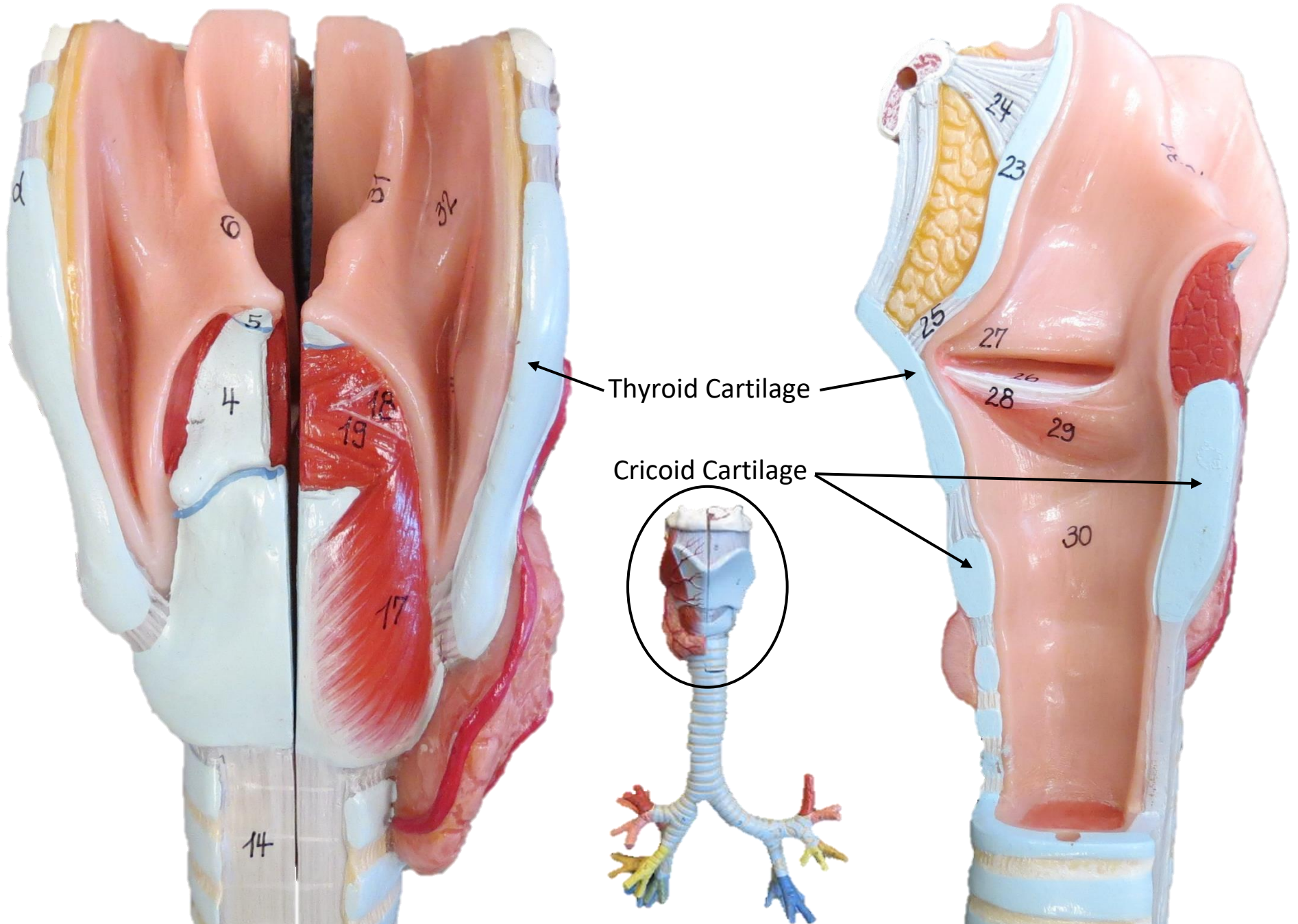
# TRACHEA MODEL





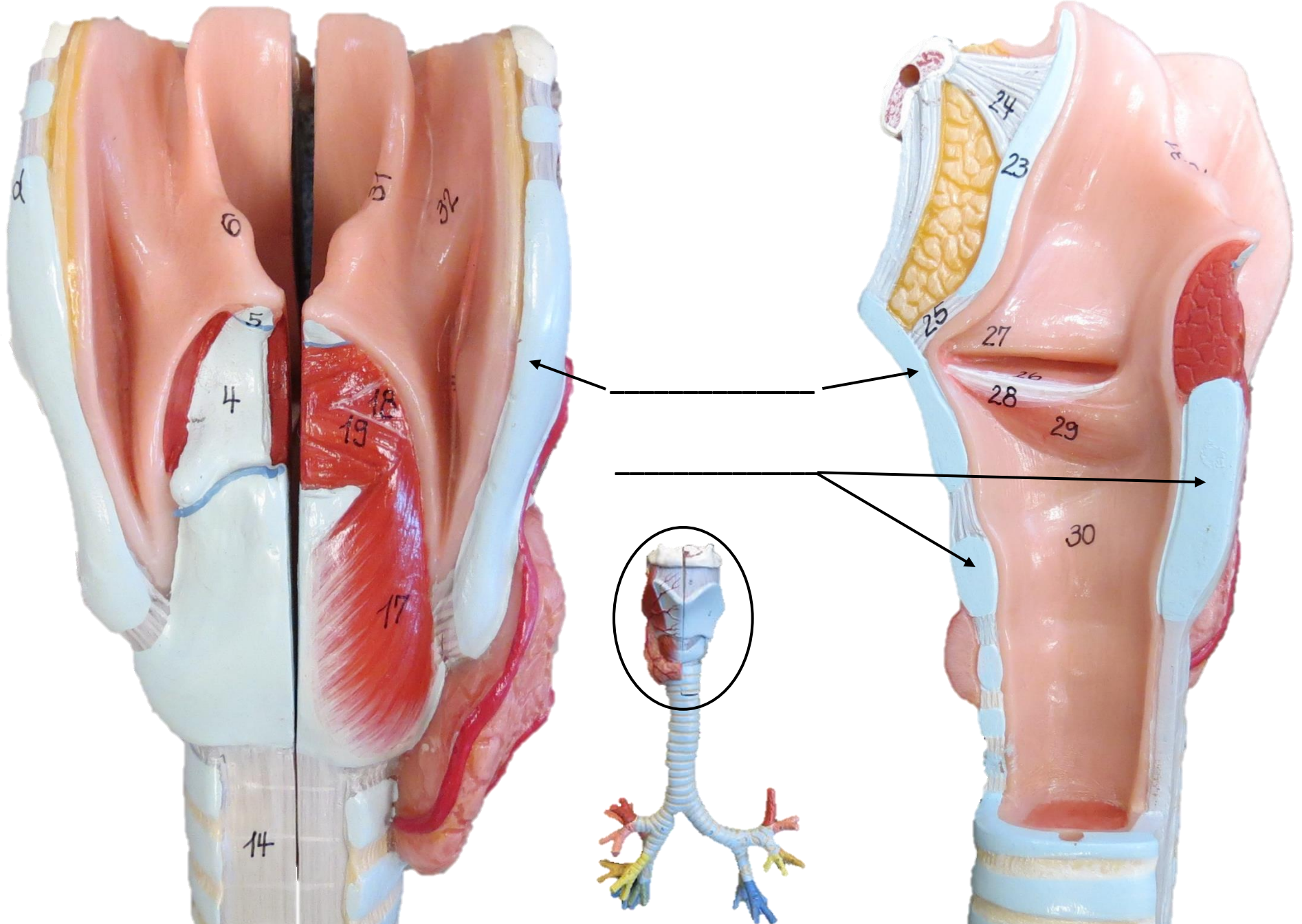
This anatomical model illustrates the larynx and trachea. The larynx is shown in a sagittal section, revealing the vocal folds (labeled 1 and 1a), the epiglottis (labeled 2), and the aryepiglottic folds (labeled 3). The trachea is shown in a sagittal section, revealing the cartilaginous rings (labeled 4, 5, 6, 7, 8, 9, 10, 11, 12, 13) and the tracheal wall (labeled 14). The model is color-coded: the vocal folds and epiglottis are pink, the aryepiglottic folds are yellow, the tracheal cartilage is light blue, and the tracheal wall is dark blue. Arrows point from the numbered labels to the corresponding structures on the model.

# TRACHEA MODEL

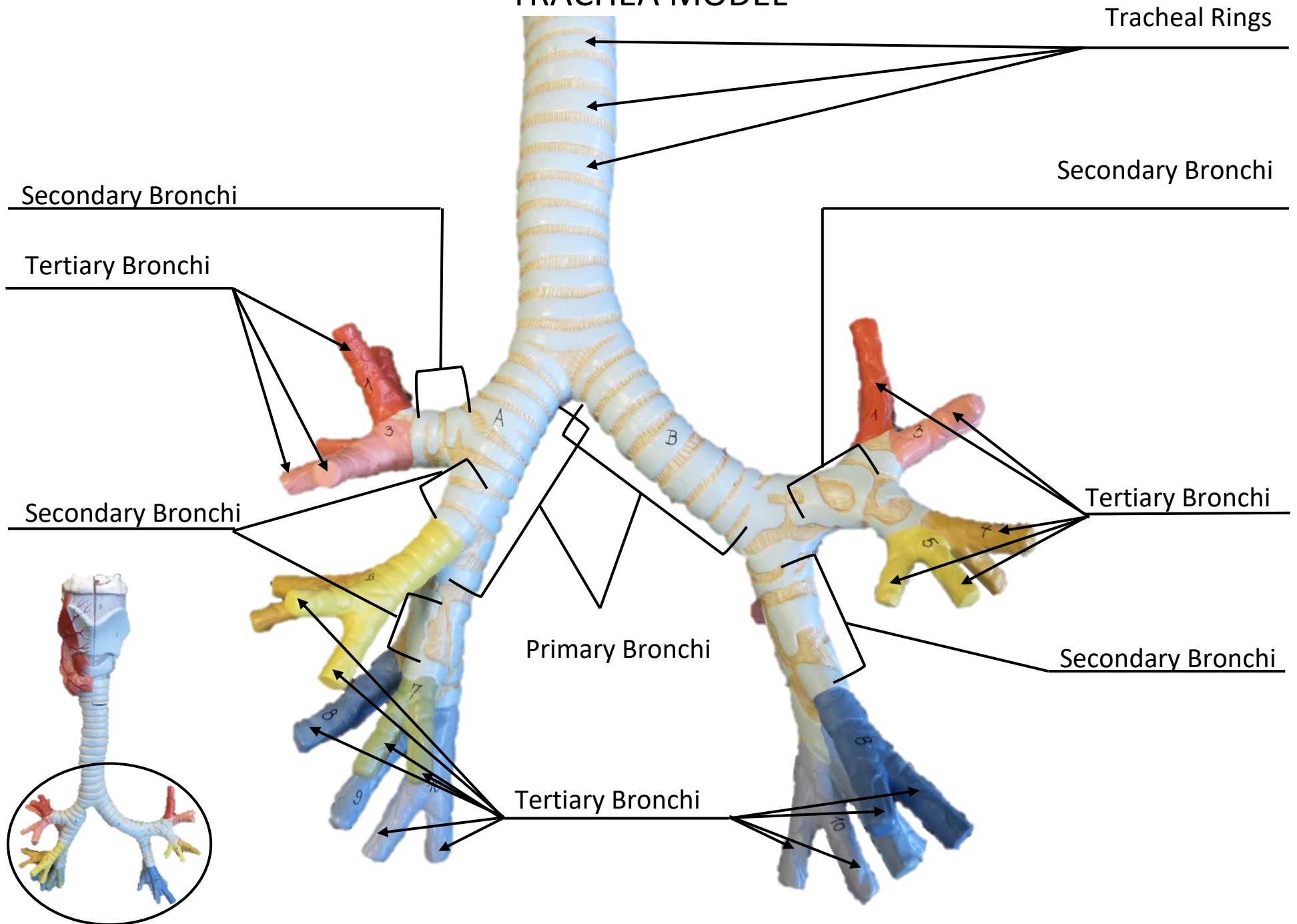




# TRACHEA MODEL

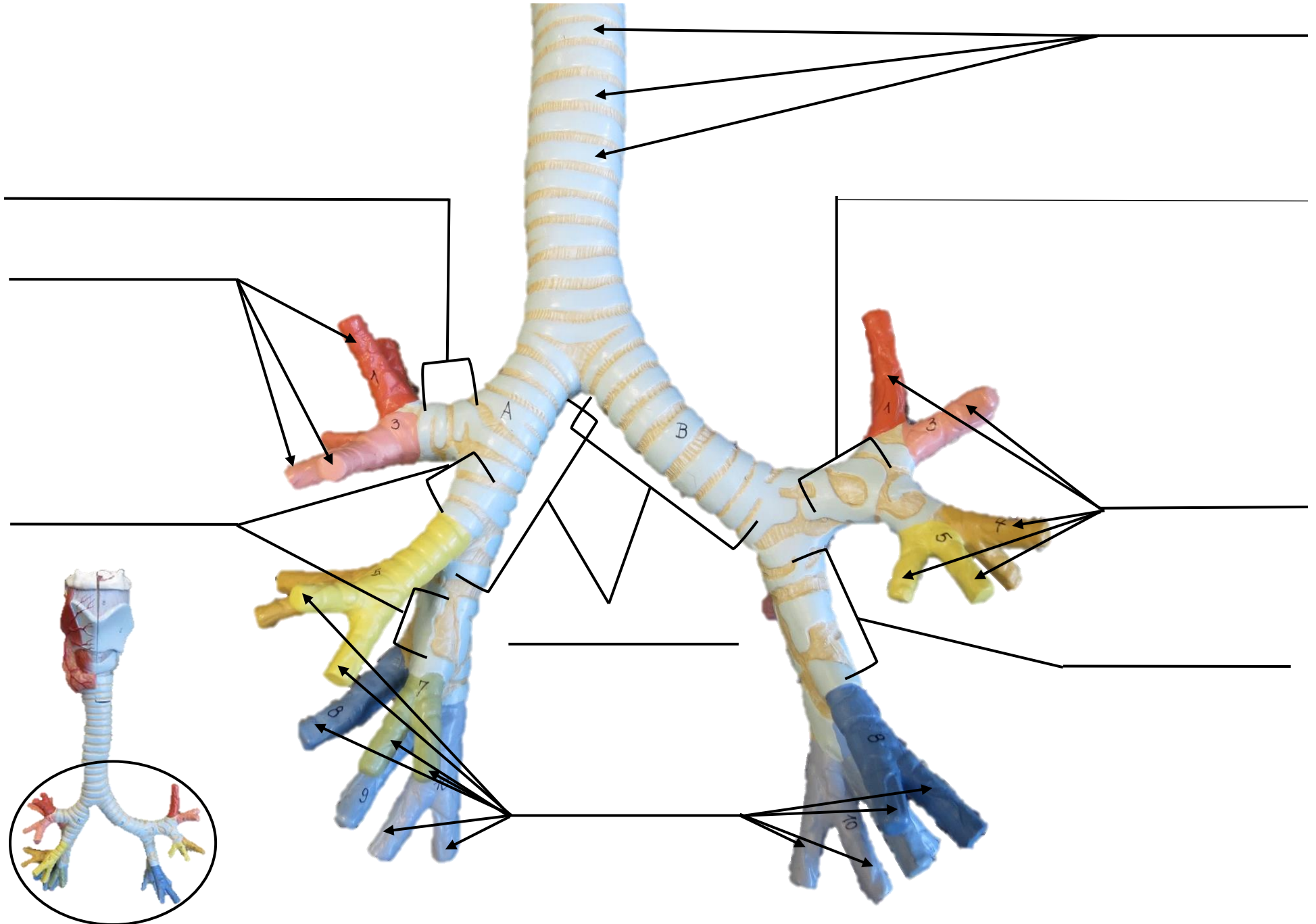


# TRACHEA MODEL

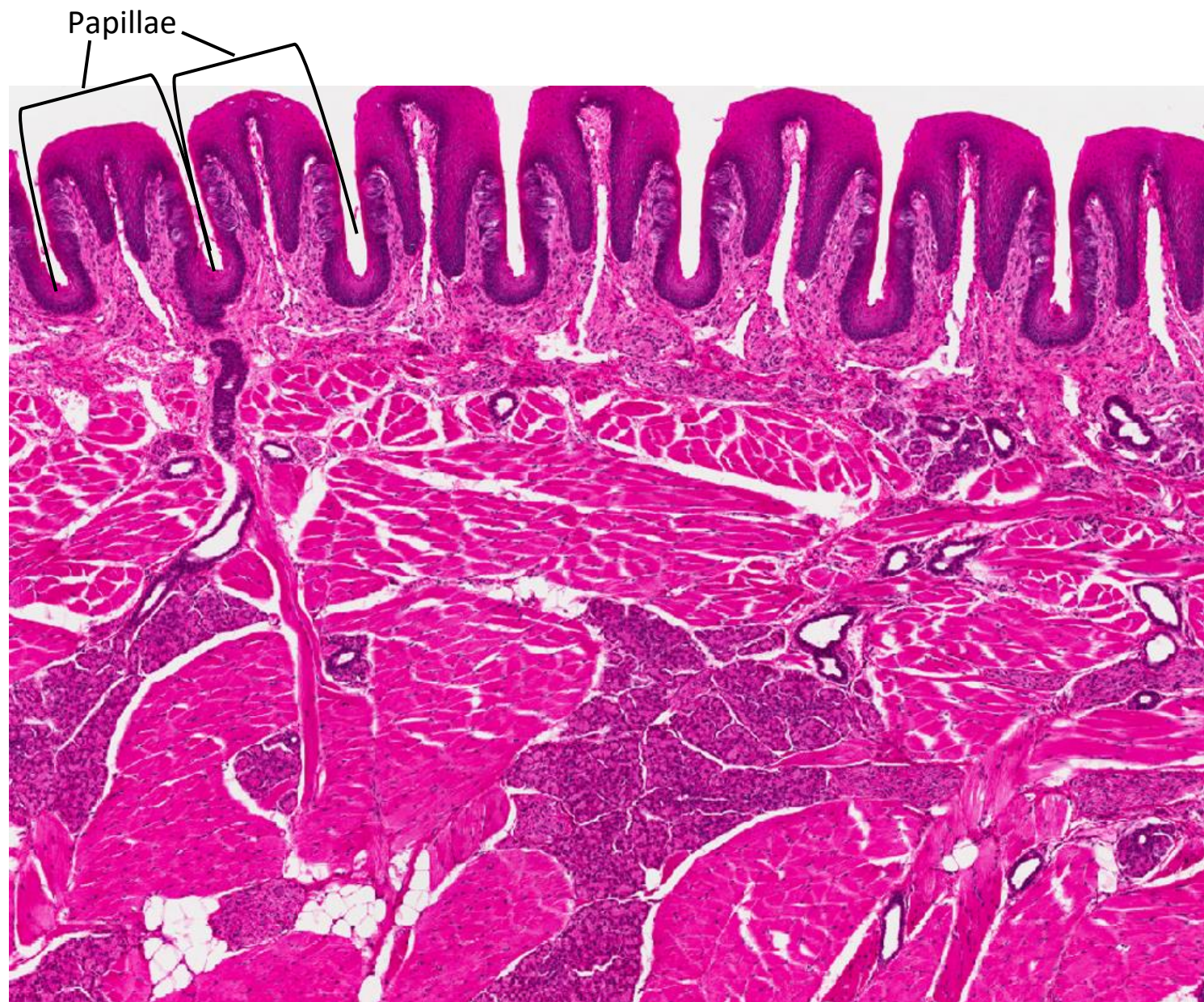



# TRACHEA MODEL

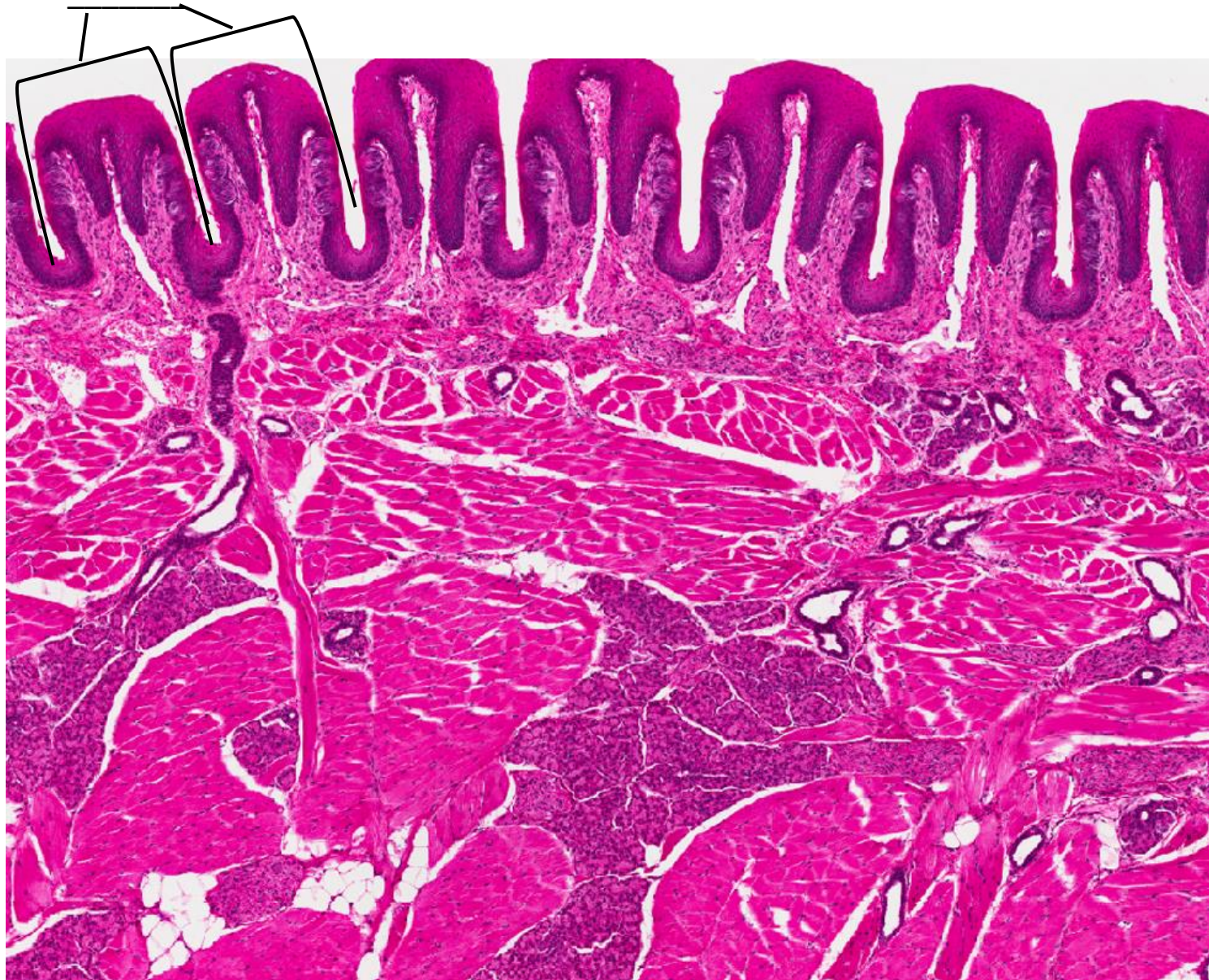


## TONGUE SLIDE



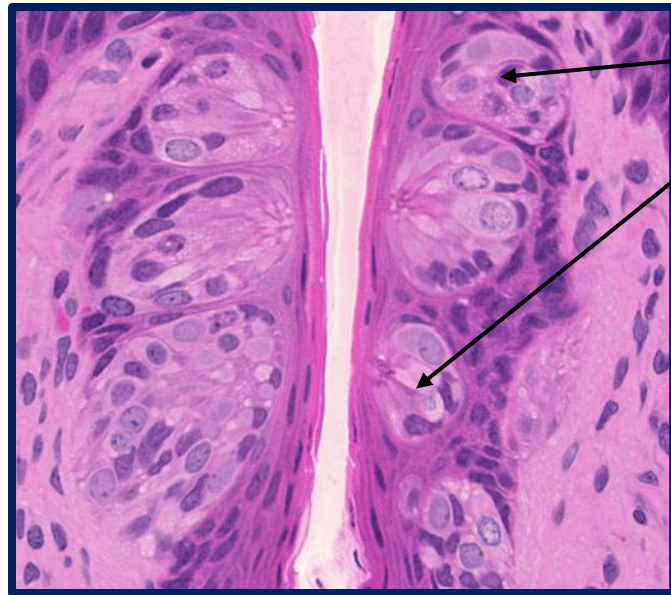


## TONGUE SLIDE



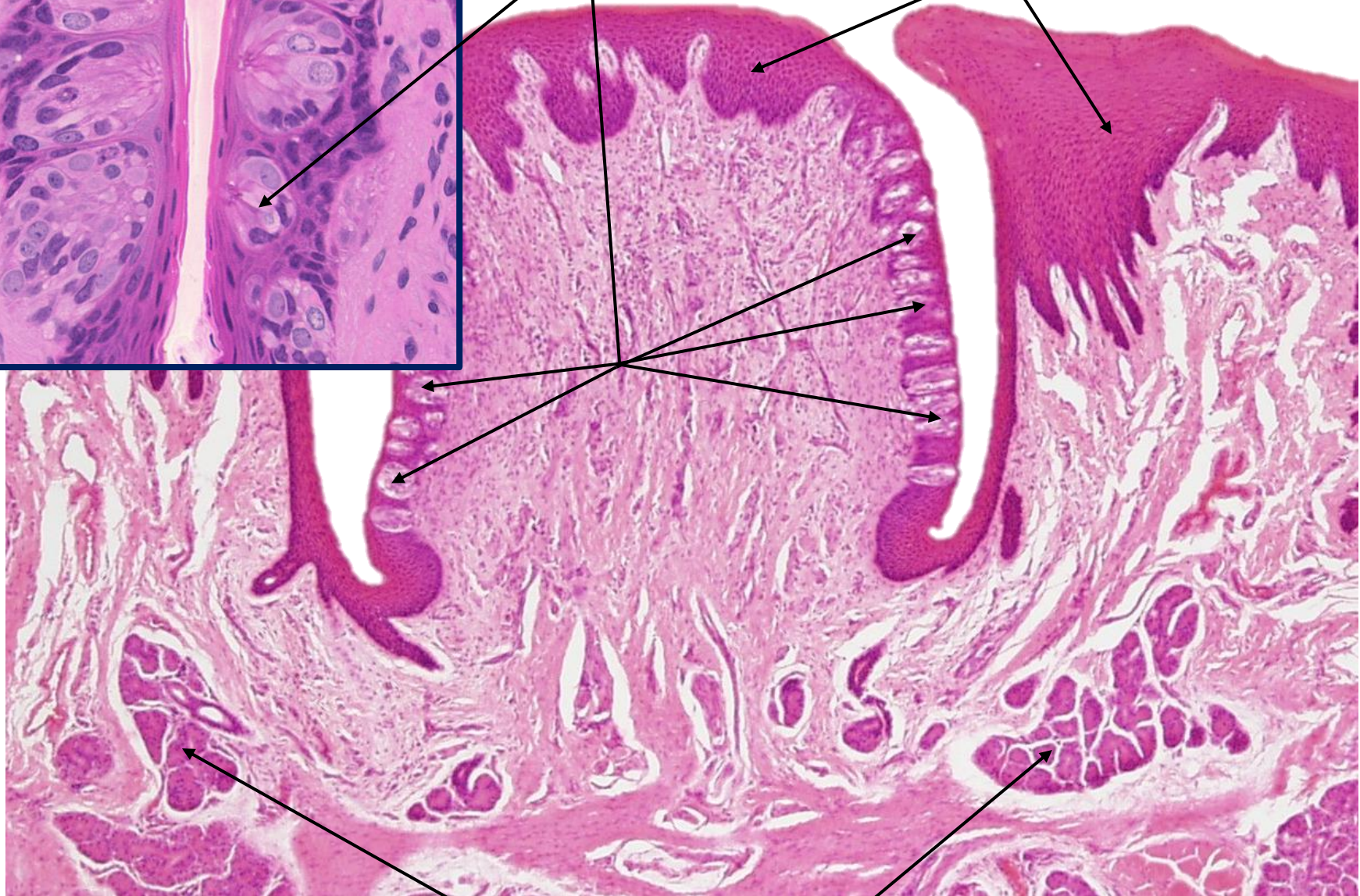


## TONGUE SLIDE



Taste Buds

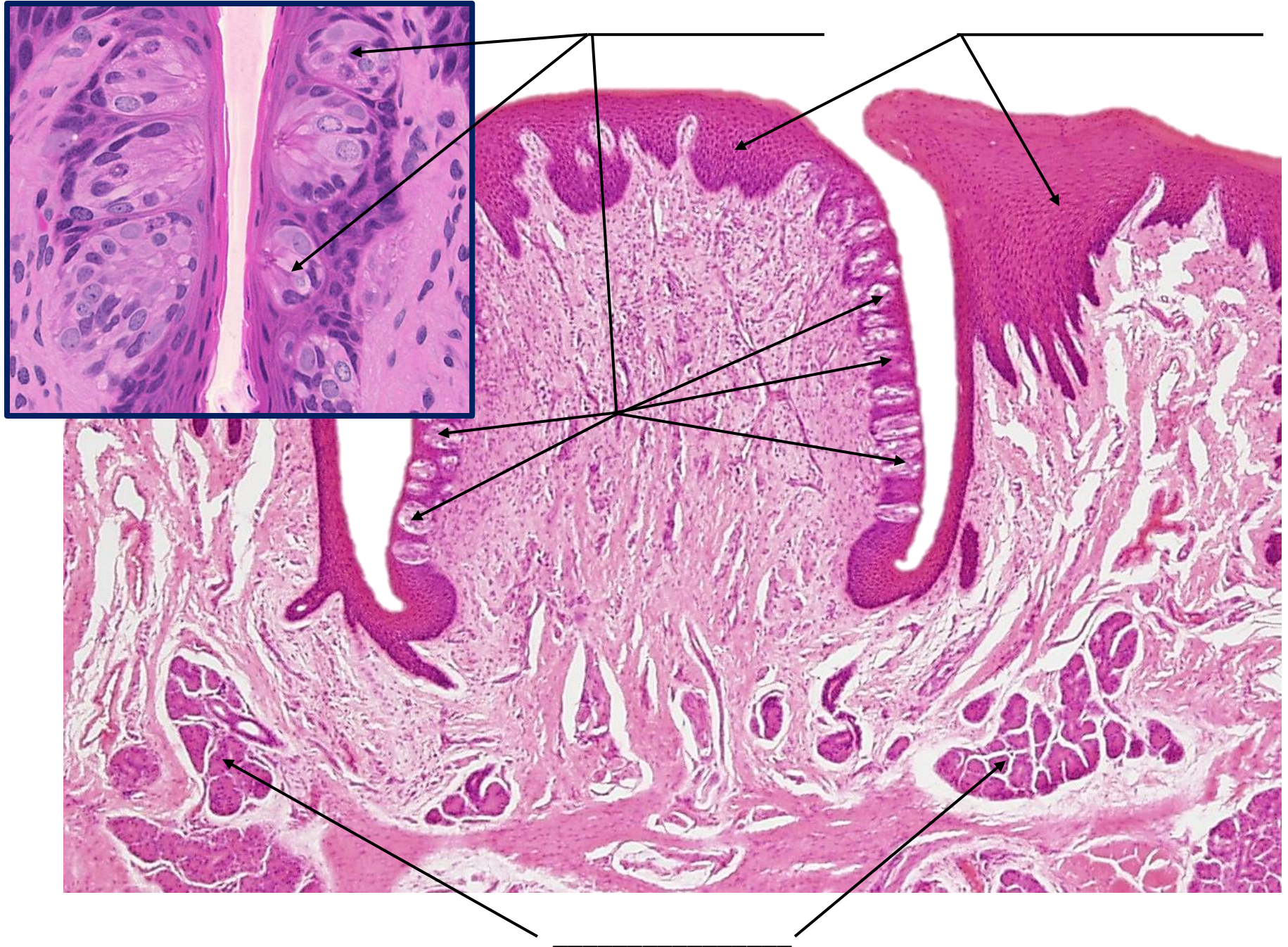
Stratified Squamous Epithelium



Von Ebners Glands



# TONGUE SLIDE

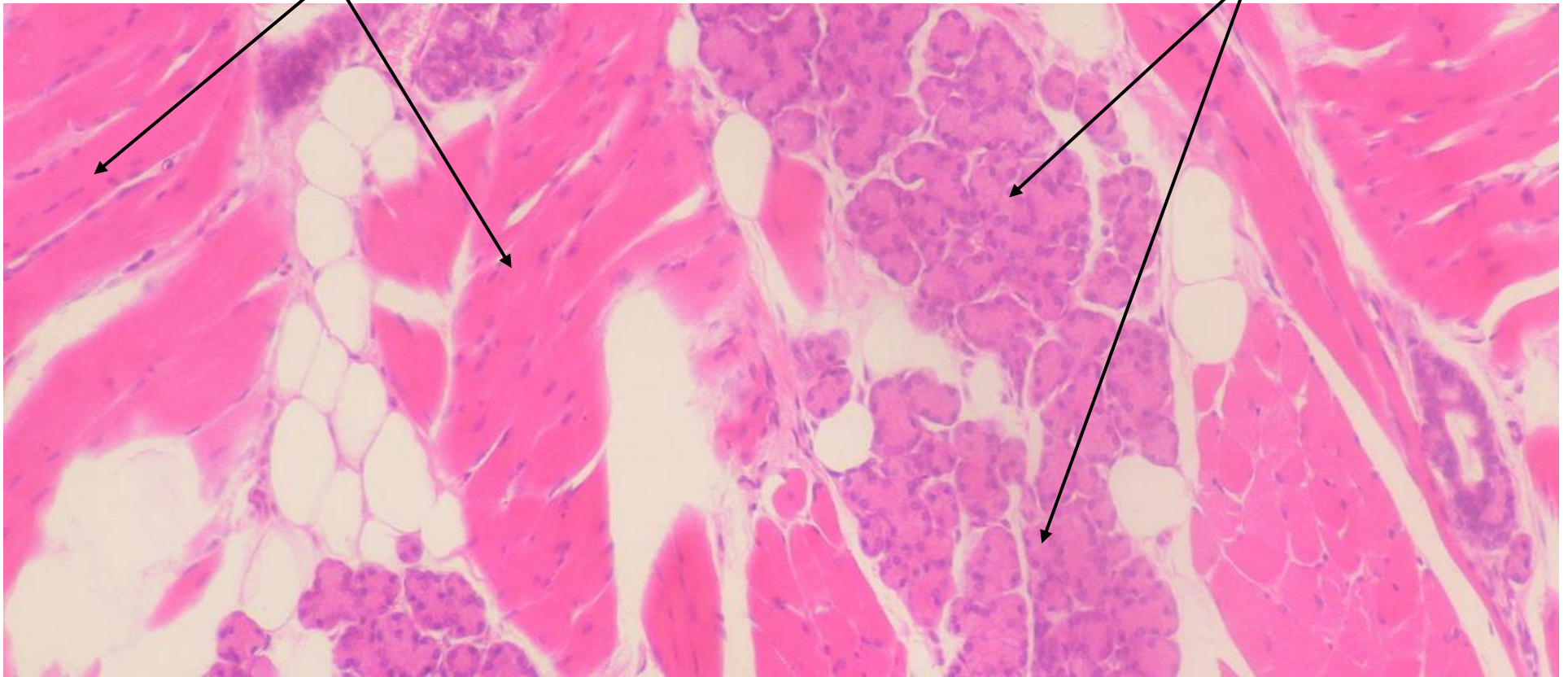




# TONGUE SLIDE

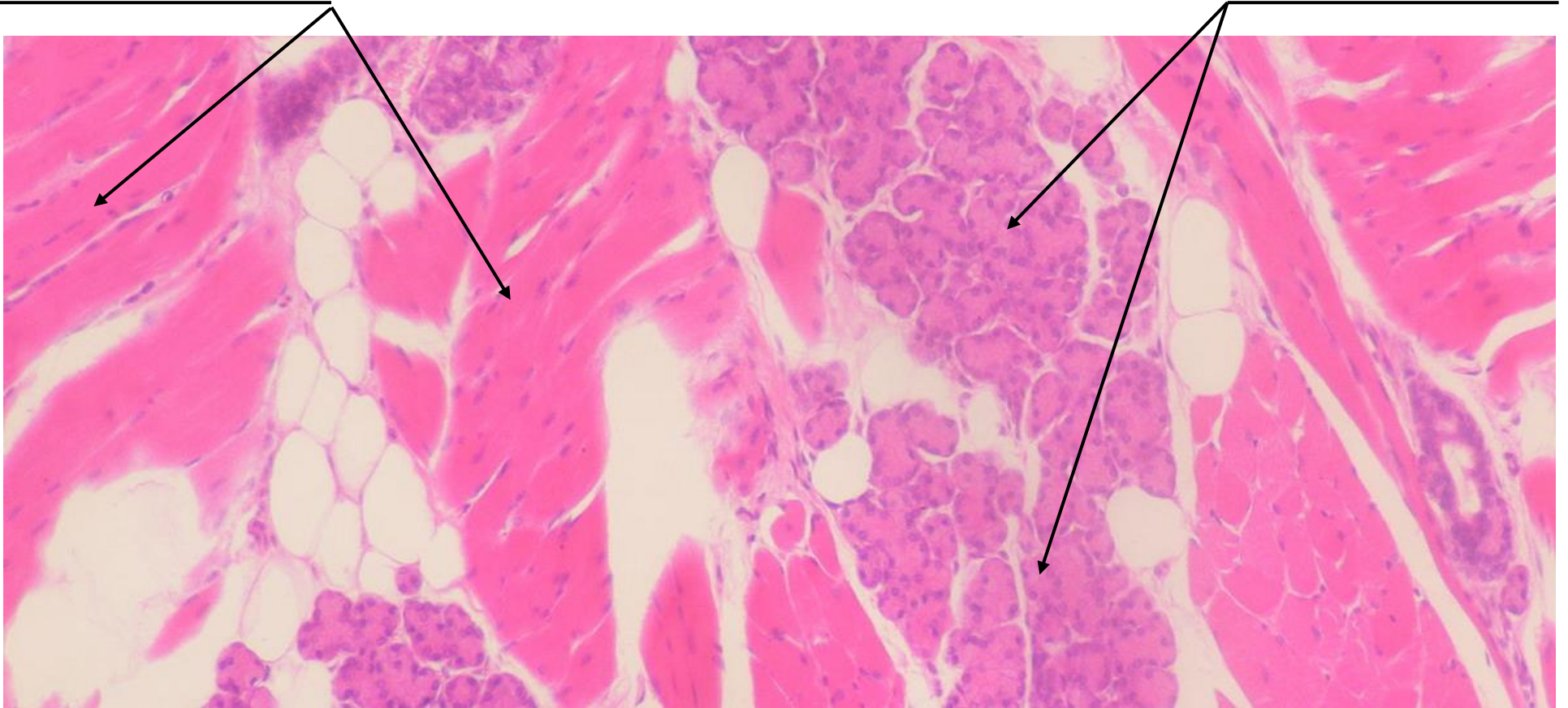Skeletal Muscle Fibers

Von Ebners Glands

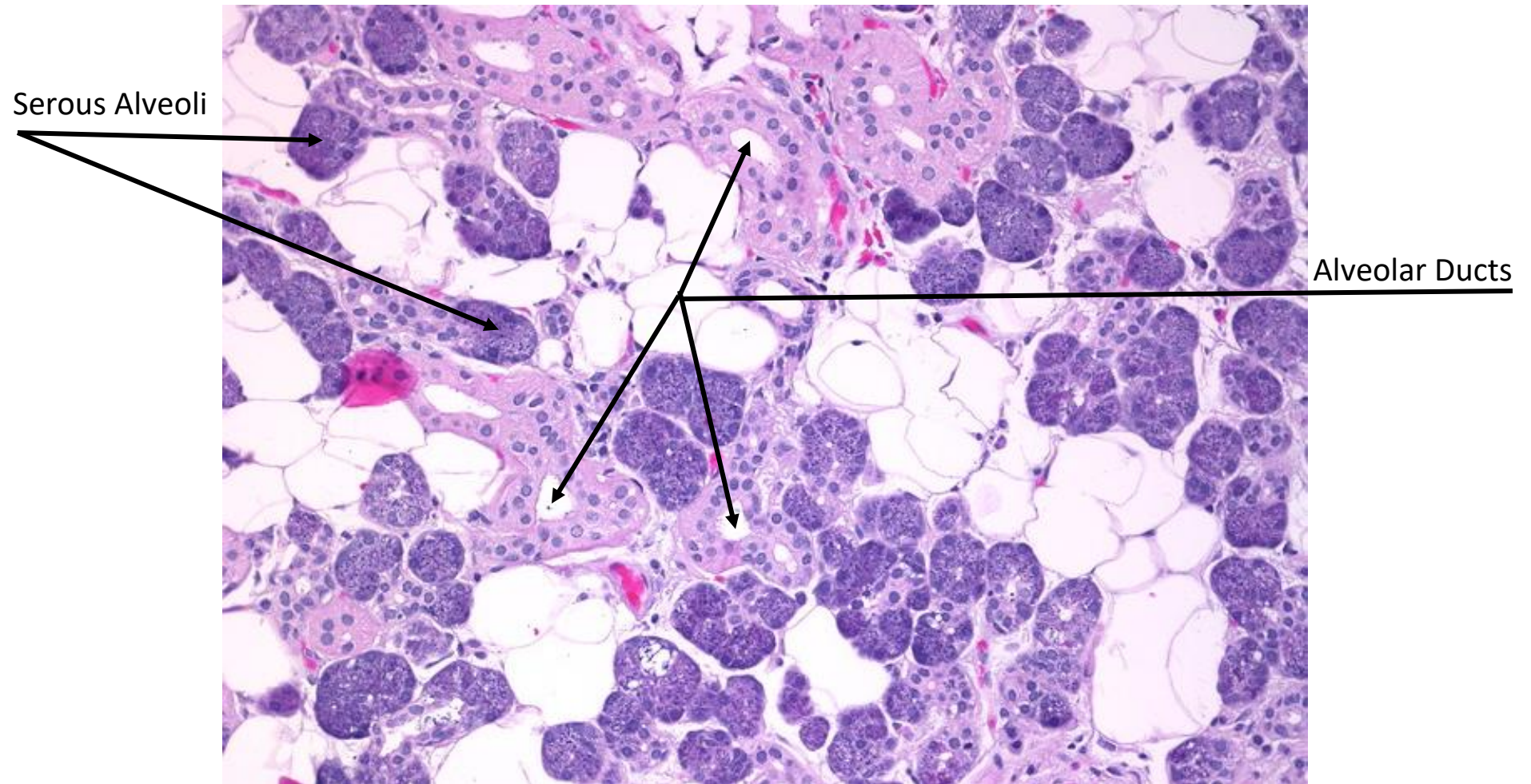




## TONGUE SLIDE

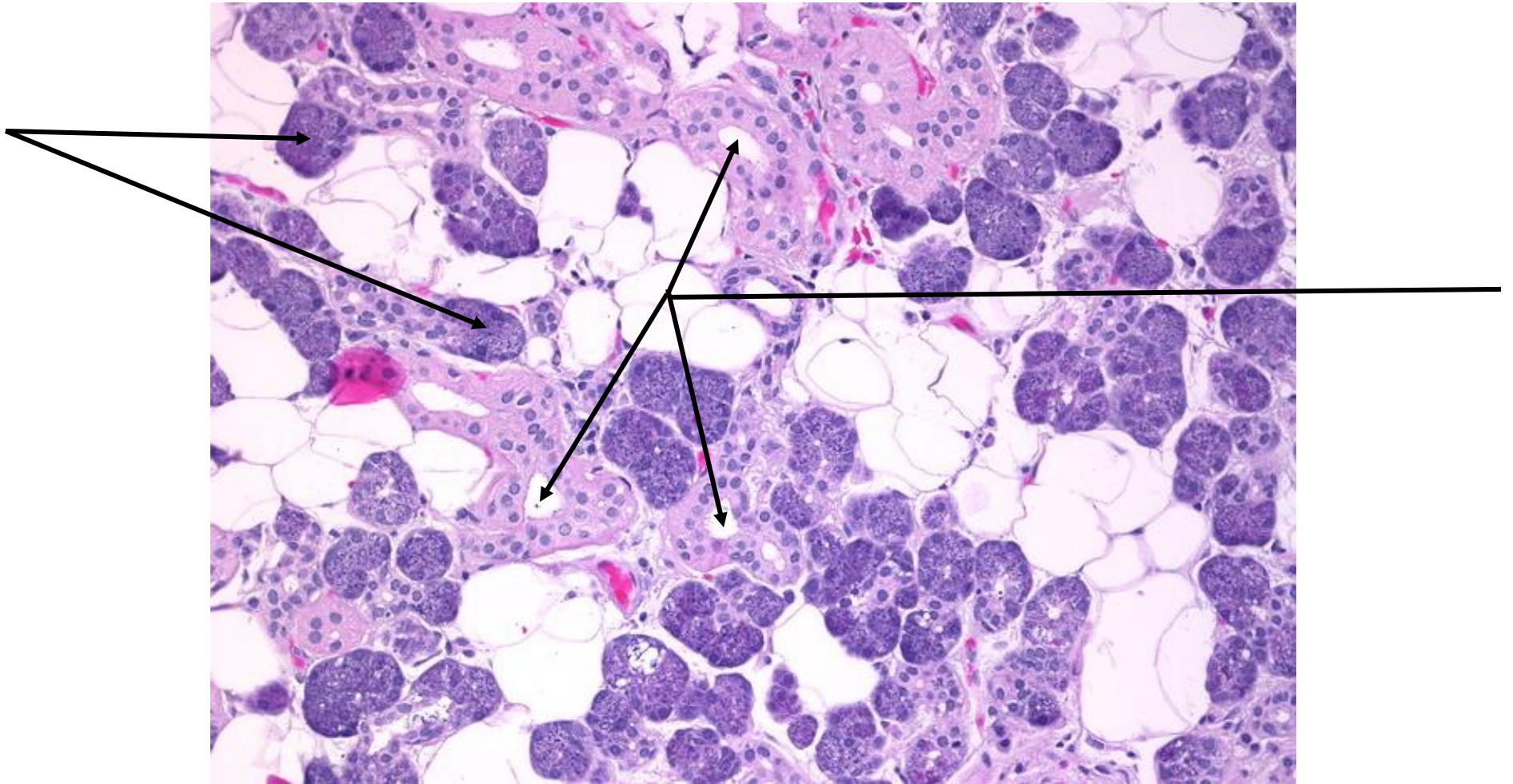


## PAROTID SALIVARY GLAND SLIDE





## PAROTID SALIVARY GLAND SLIDE





# JEJUNUM MODEL

Mucosa Layer

Simple Columnar Epithelium

Villi

Submucosa Layer

Lacteal

Lamina Propria

Intestinal Gland

Muscularis Externa

Muscularis Mucosae

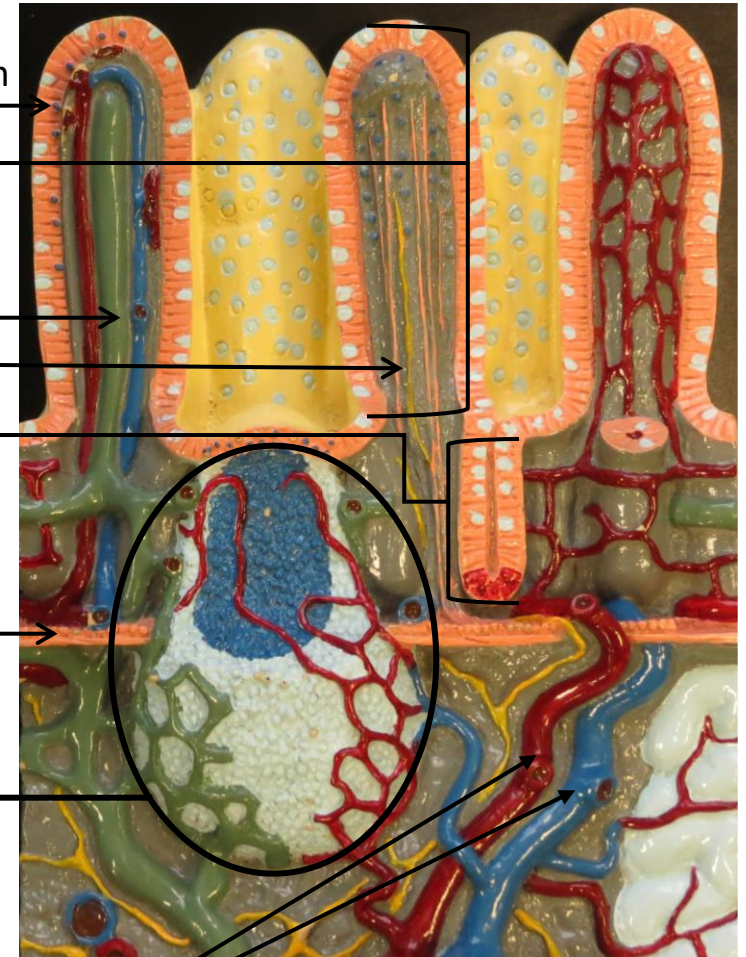
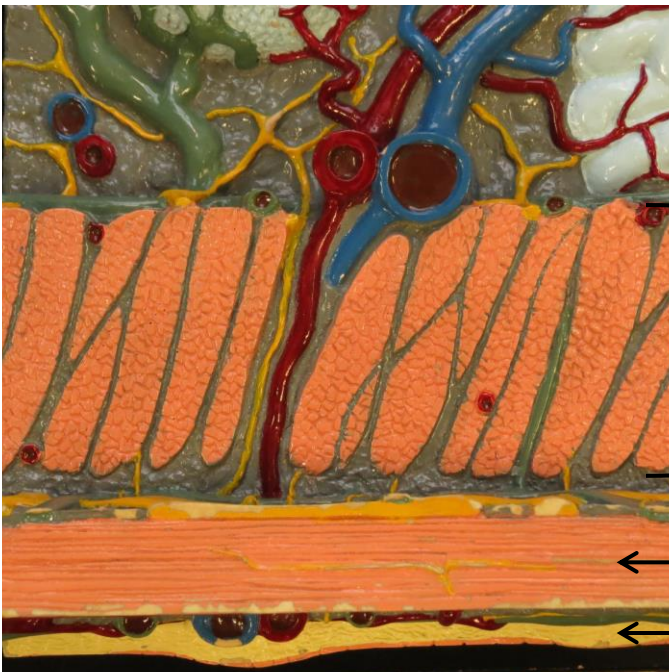
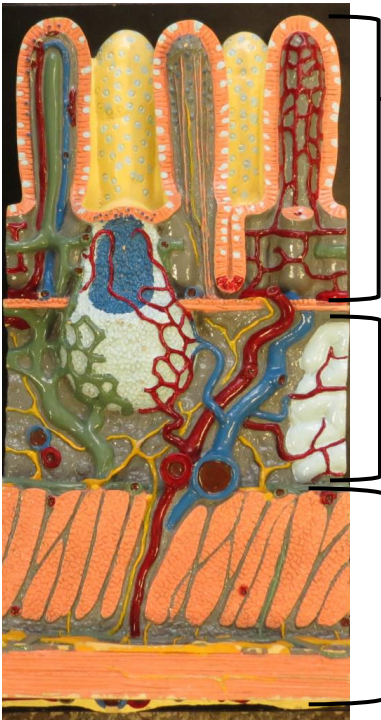
Peyer's Patch

Circular Layer

Blood Vessels

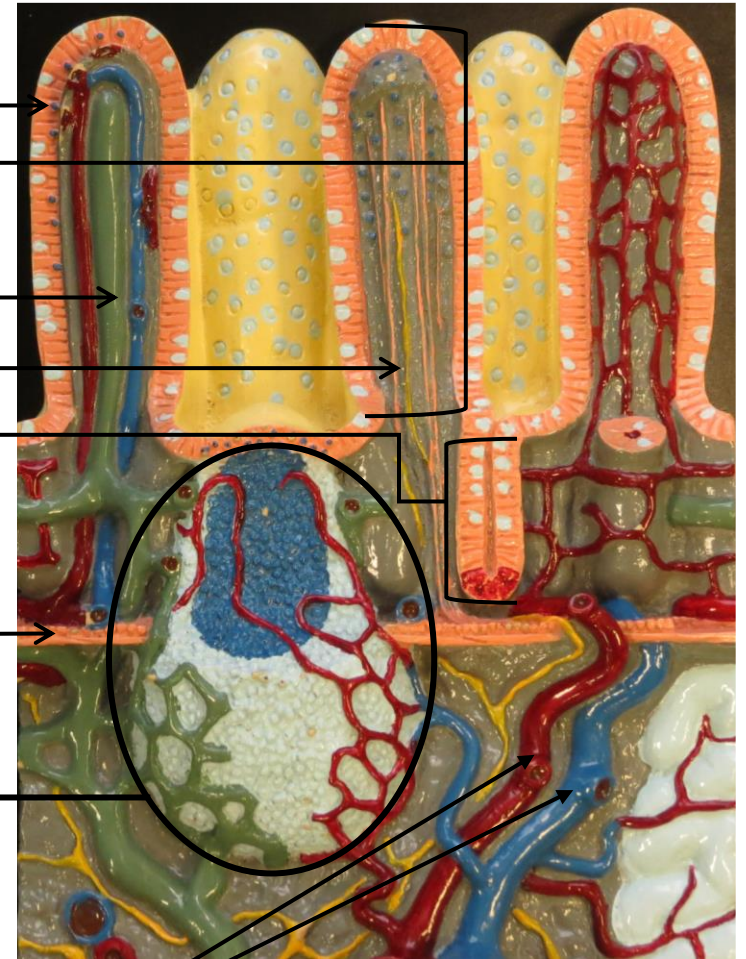
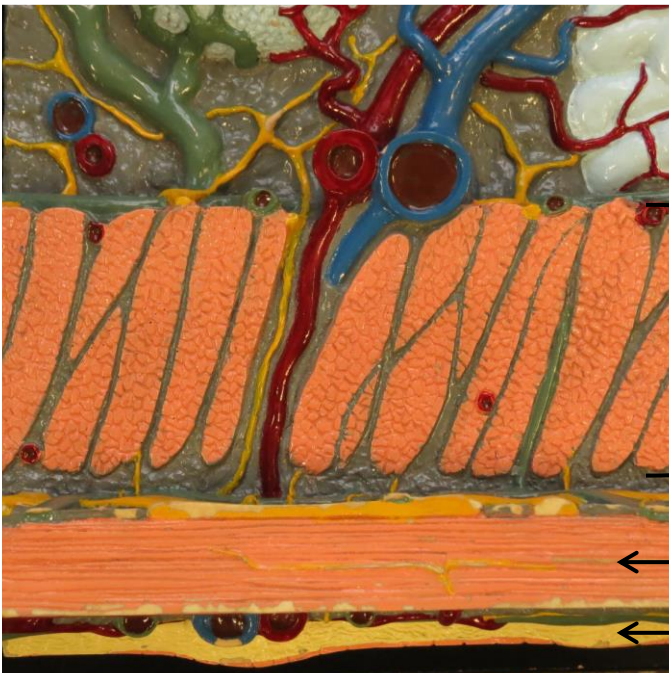Longitudinal Layer

Serosa

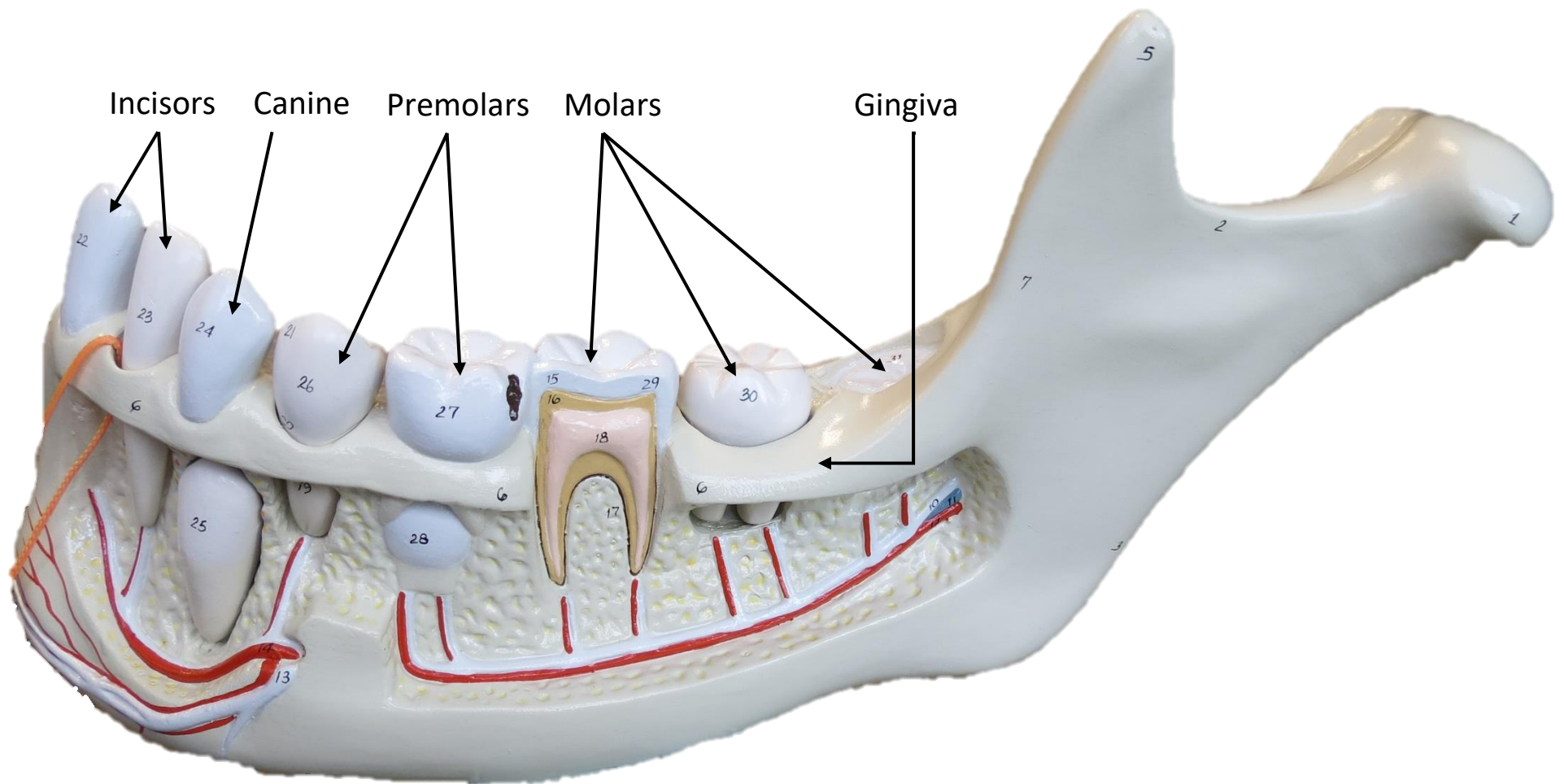




# JEJUNUM MODEL

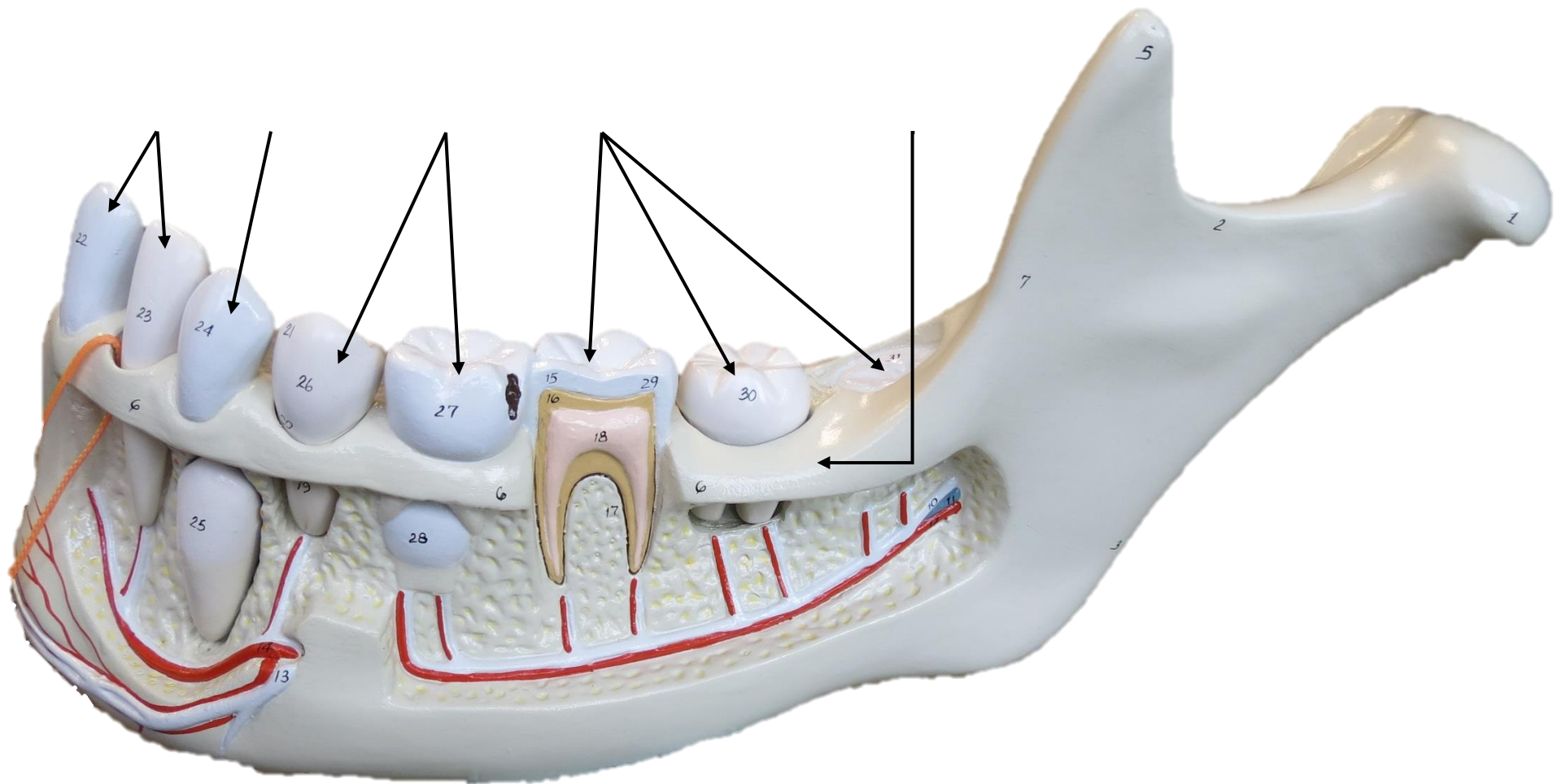


# MANDIBLE MODEL

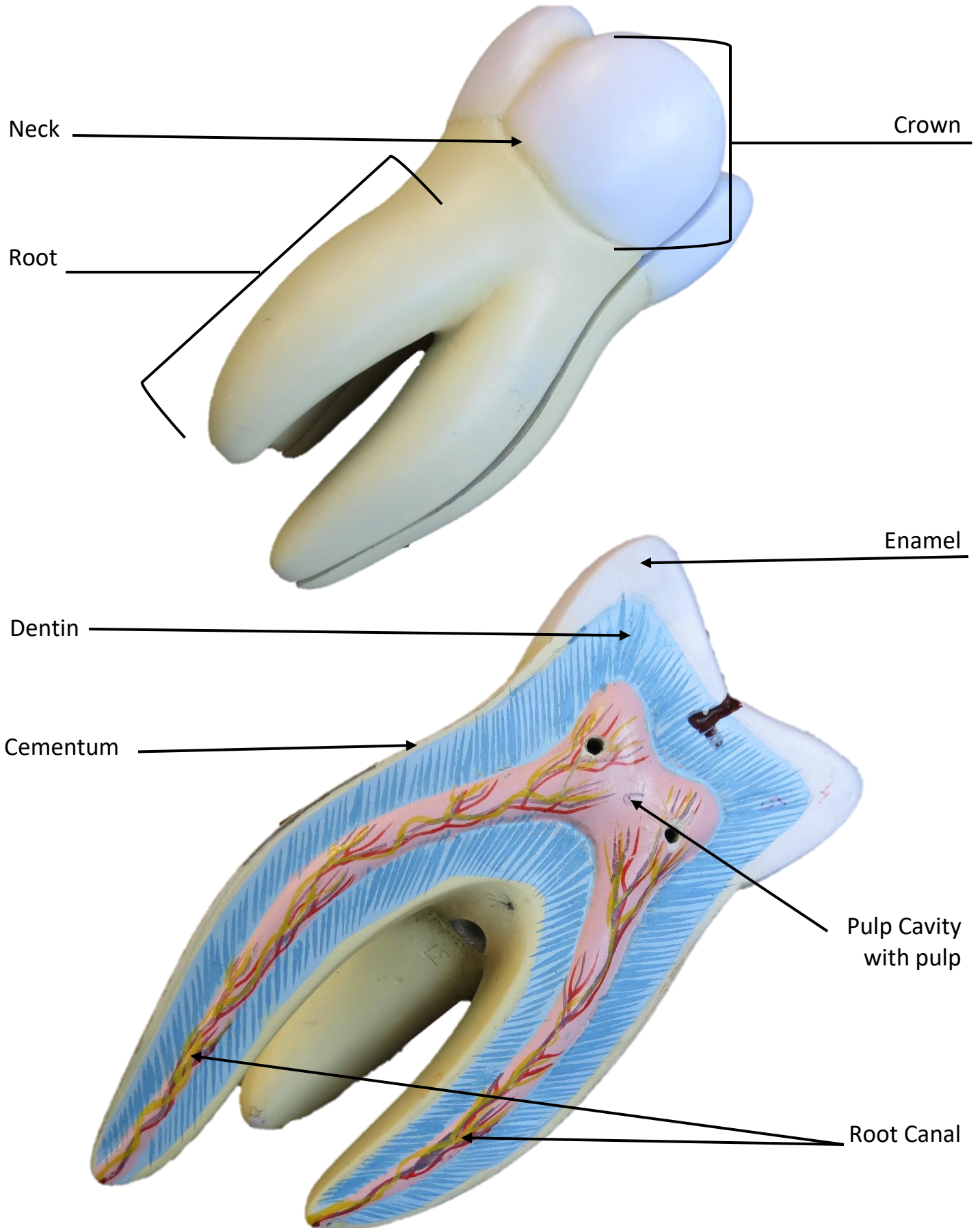




# MANDIBLE MODEL

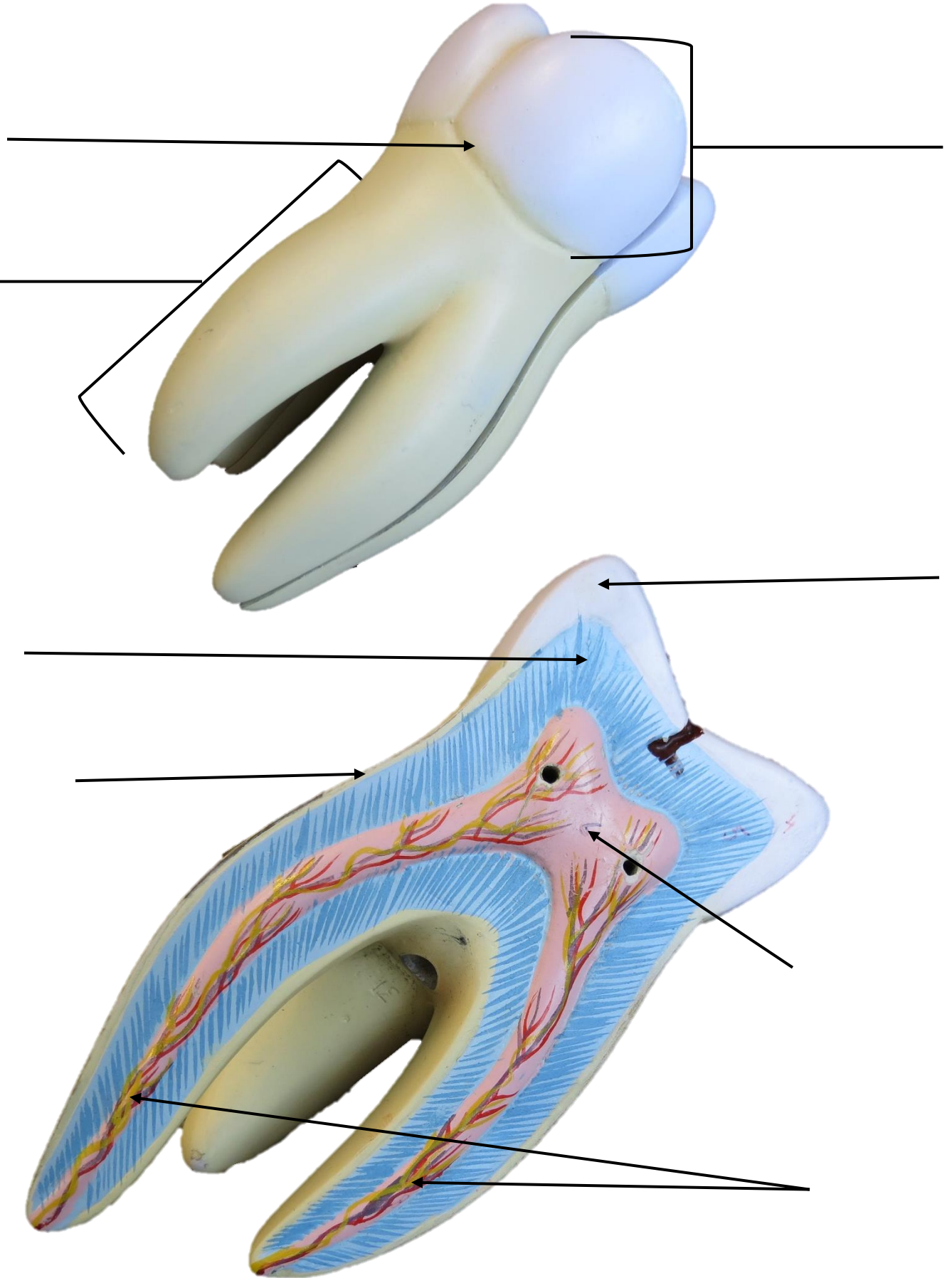


# TOOTH MODEL





## The image displays two anatomical models of a tooth, likely a maxillary premolar, used for educational purposes. The top model shows the external anatomy, with labels pointing to the crown, root, and pulp chamber. The bottom model shows a cross-section of the tooth, revealing the internal pulp space and the surrounding dentin and enamel layers. Labels point to the enamel, dentin, pulp chamber, pulp root, and pulp apex. The models are color-coded: the crown is light blue, the root is light yellow, the pulp chamber is pink, the pulp root is red, and the pulp apex is yellow. The enamel is white, and the dentin is light blue. The pulp space is filled with a pinkish-red material, and the pulp root is filled with a red material. The pulp apex is filled with a yellow material. The models are shown from a lingual perspective, with the root pointing towards the bottom left and the crown towards the top right. The labels are as follows: 1. Crown 2. Root 3. Pulp chamber 4. Enamel 5. Dentin 6. Pulp chamber 7. Pulp root 8. Pulp apex



# JEJUNUM MODEL

Mucosa Layer

Simple Columnar Epithelium

Villi

Submucosa Layer

Lacteal

Lamina Propria

Intestinal Gland

Muscularis Externa

Muscularis Mucosae

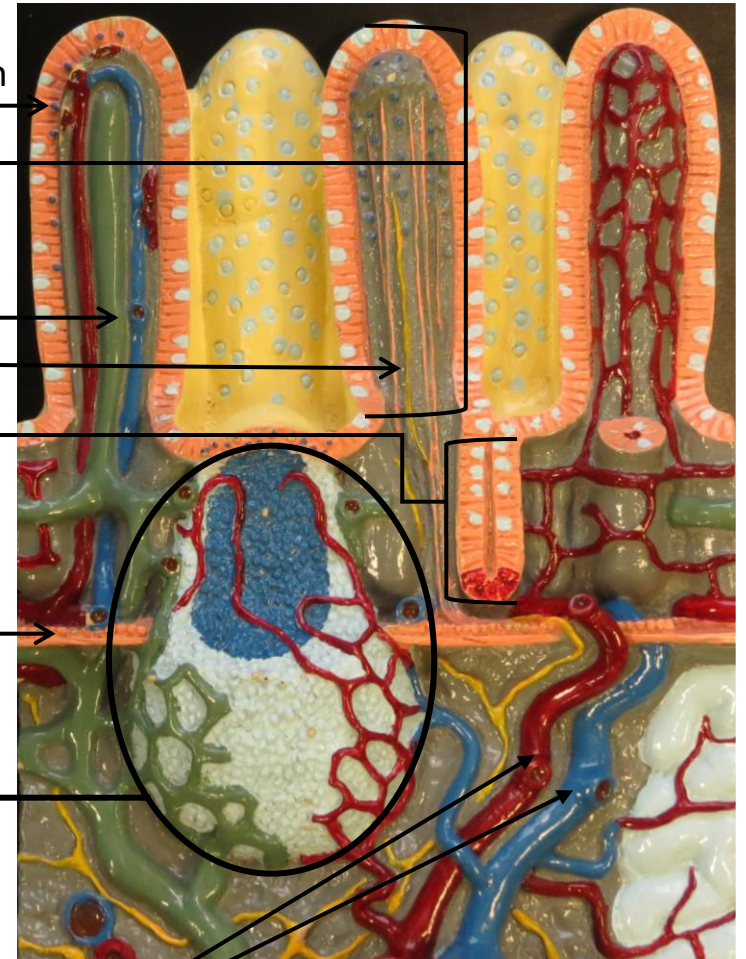
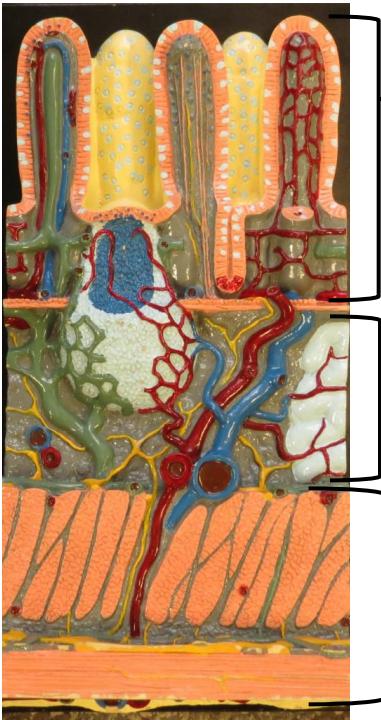
Peyer's Patch

Circular Layer

Blood Vessels

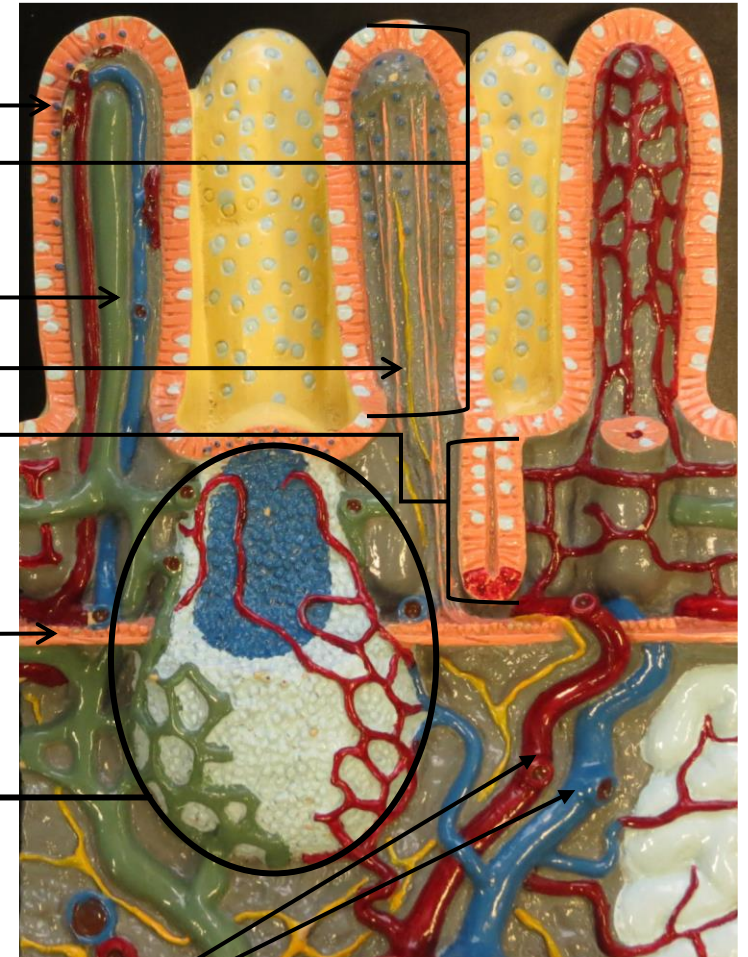
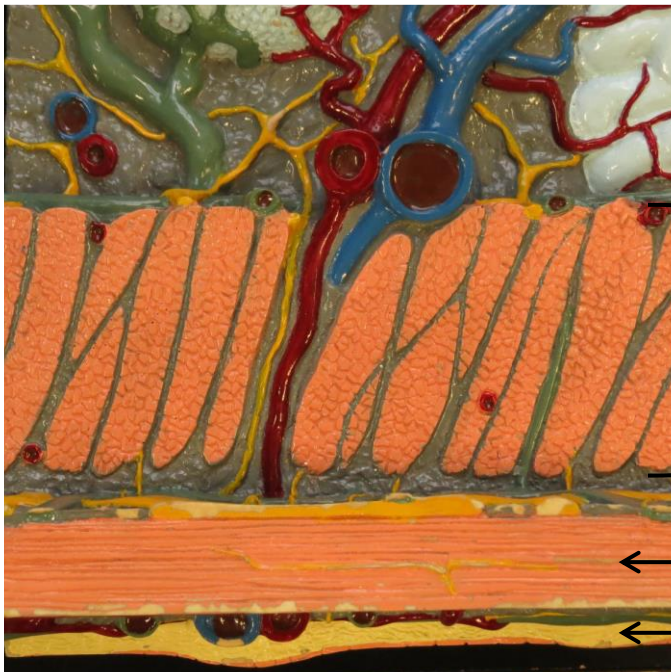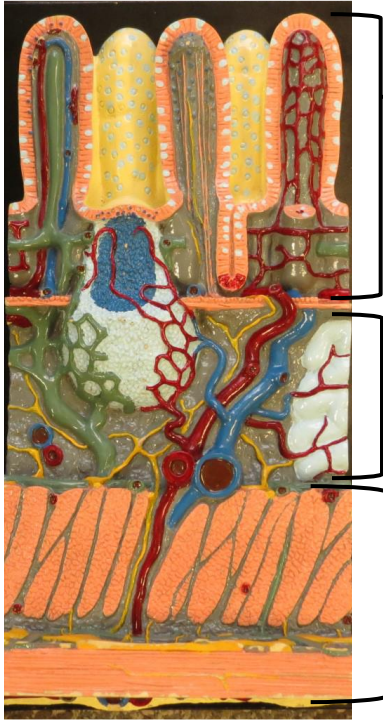
Longitudinal Layer

Serosa

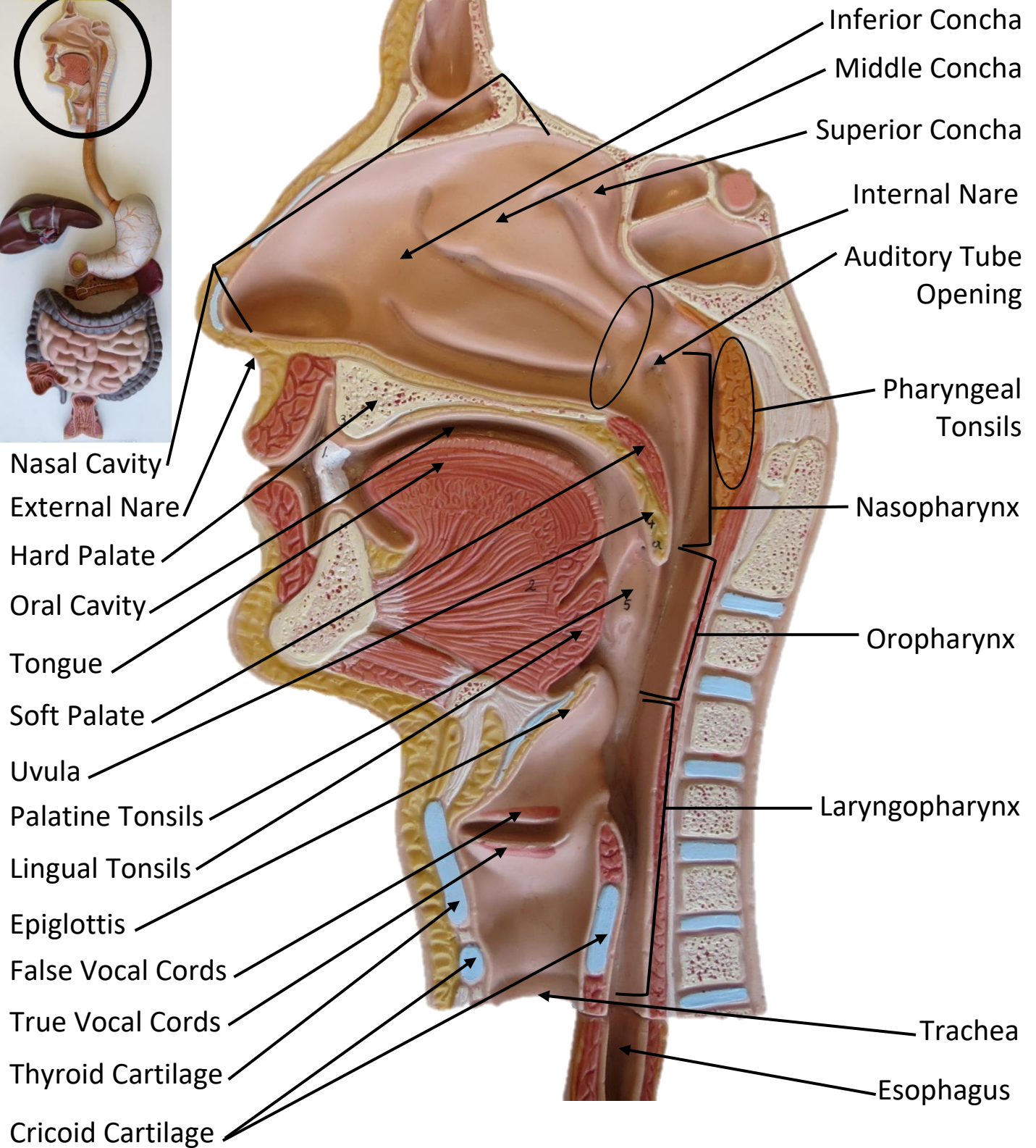
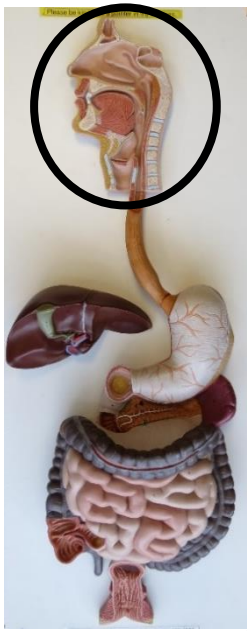



# JEJUNUM MODEL

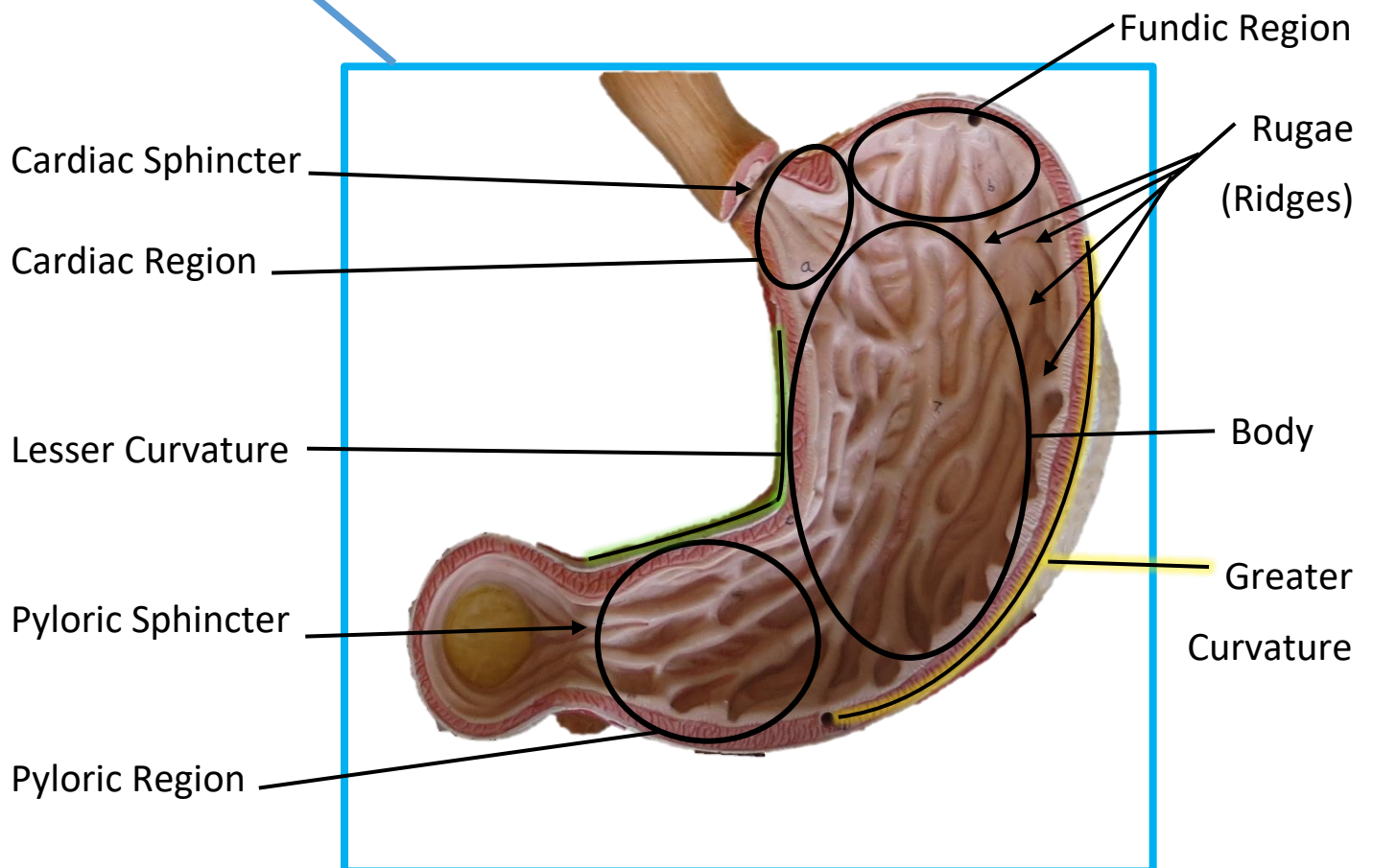
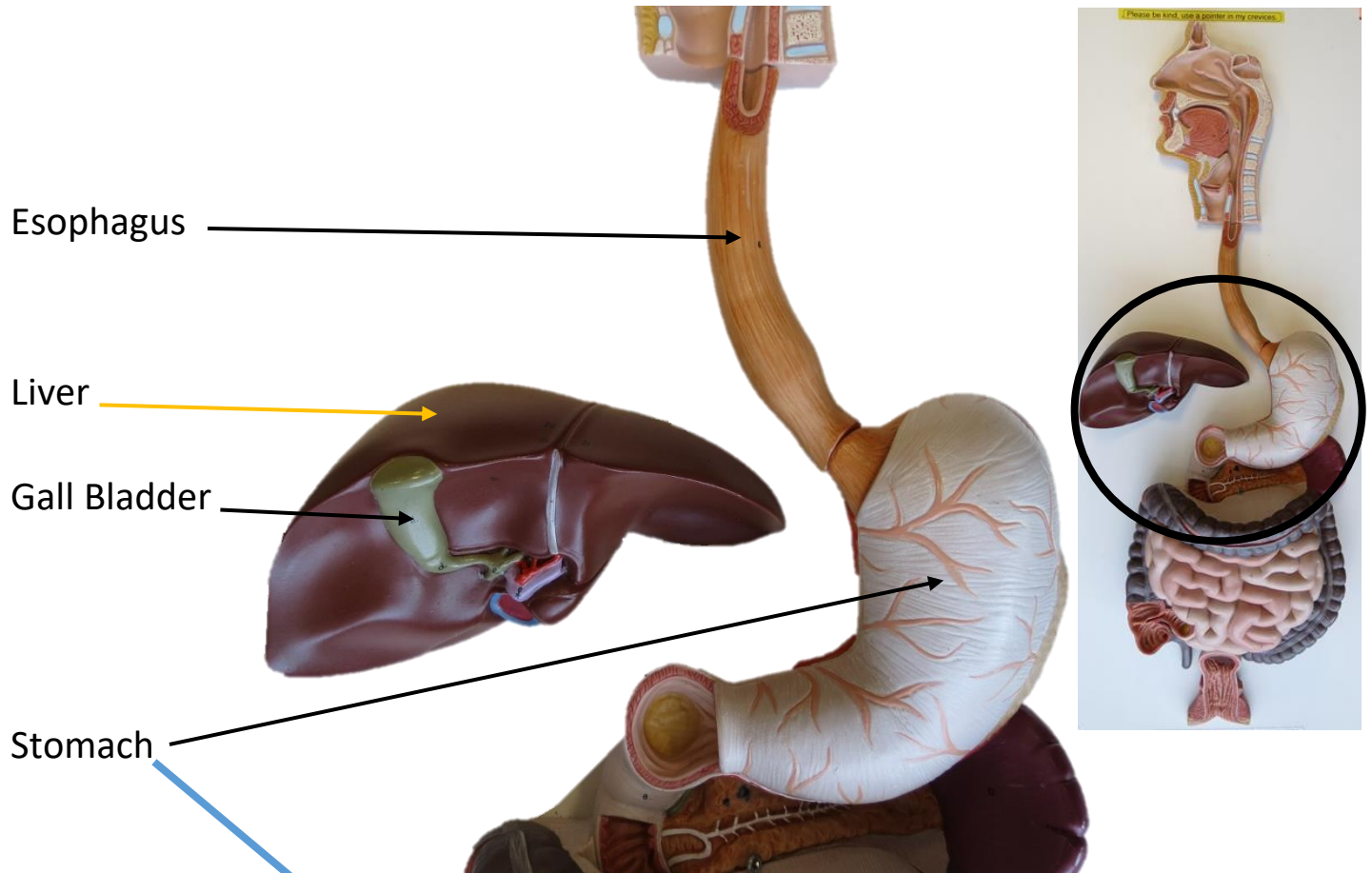


# FLAT DIGESTIVE MODEL

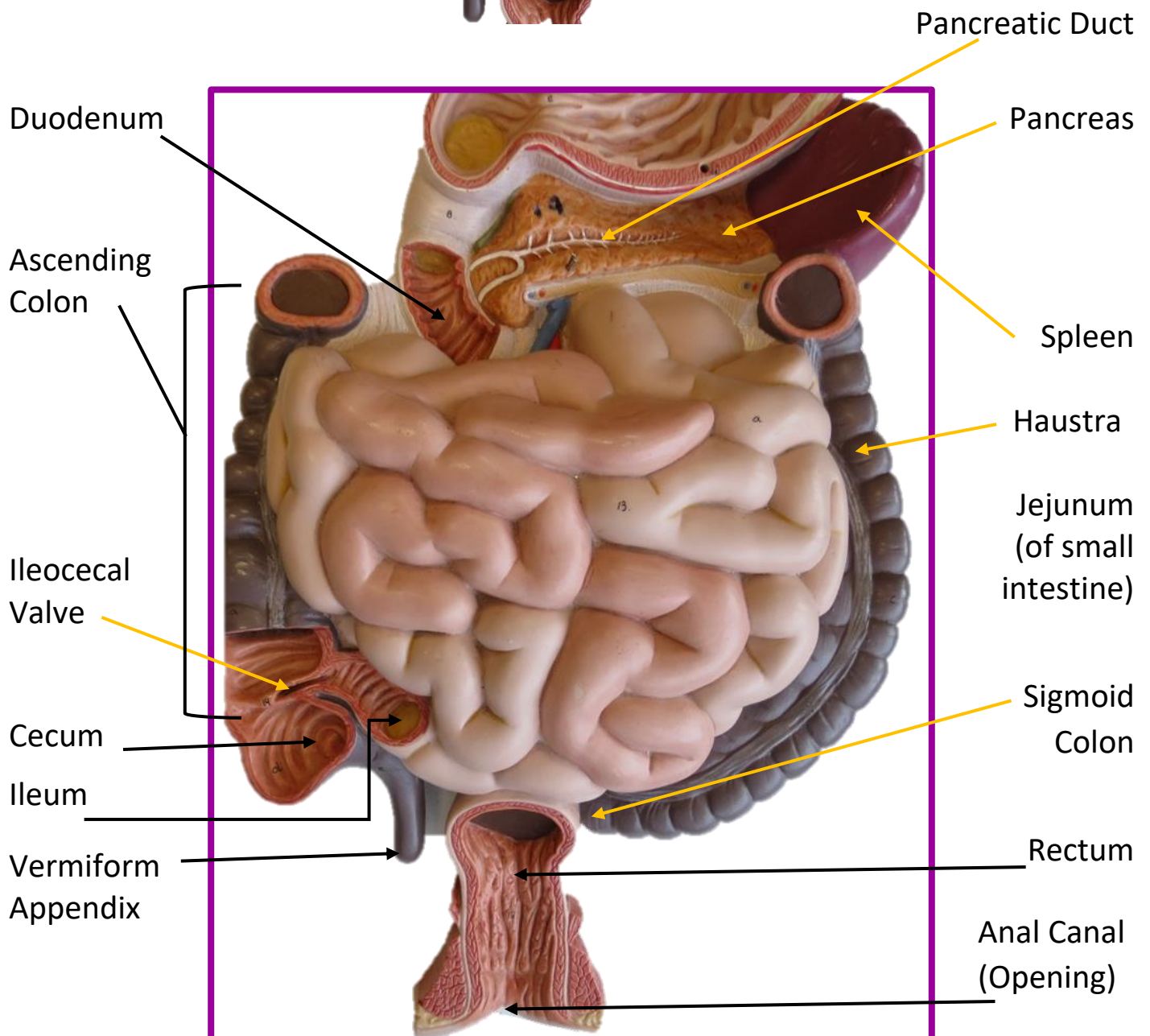
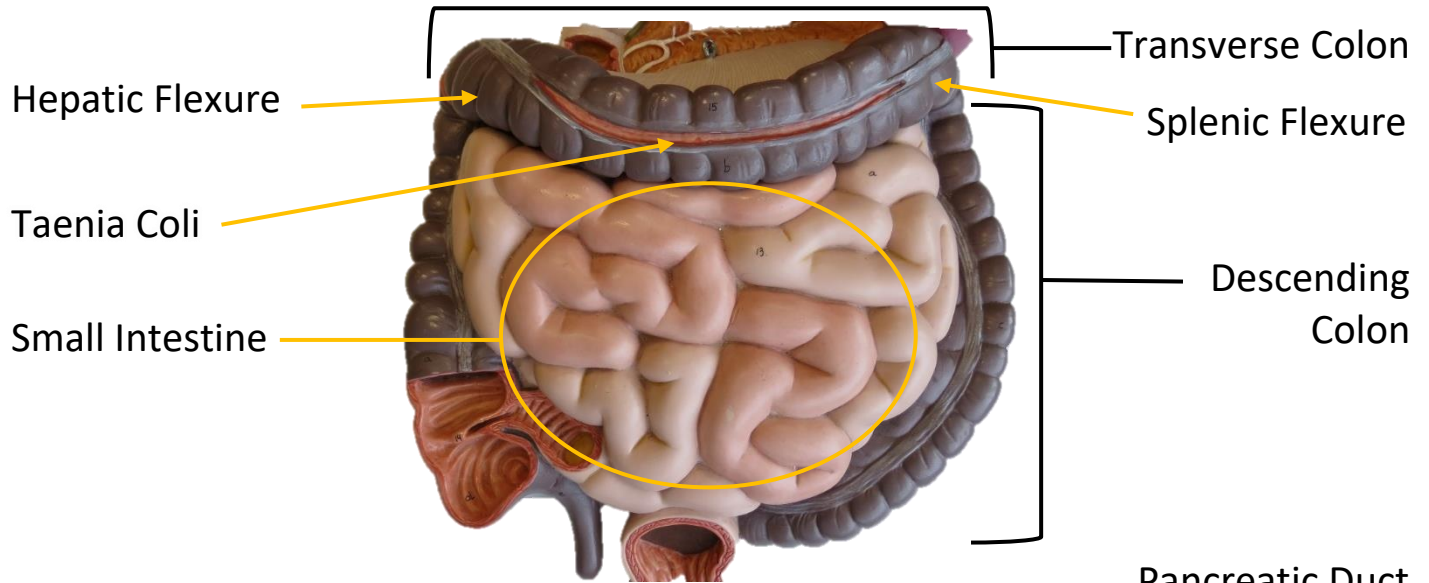




# FLAT DIGESTIVE MODEL

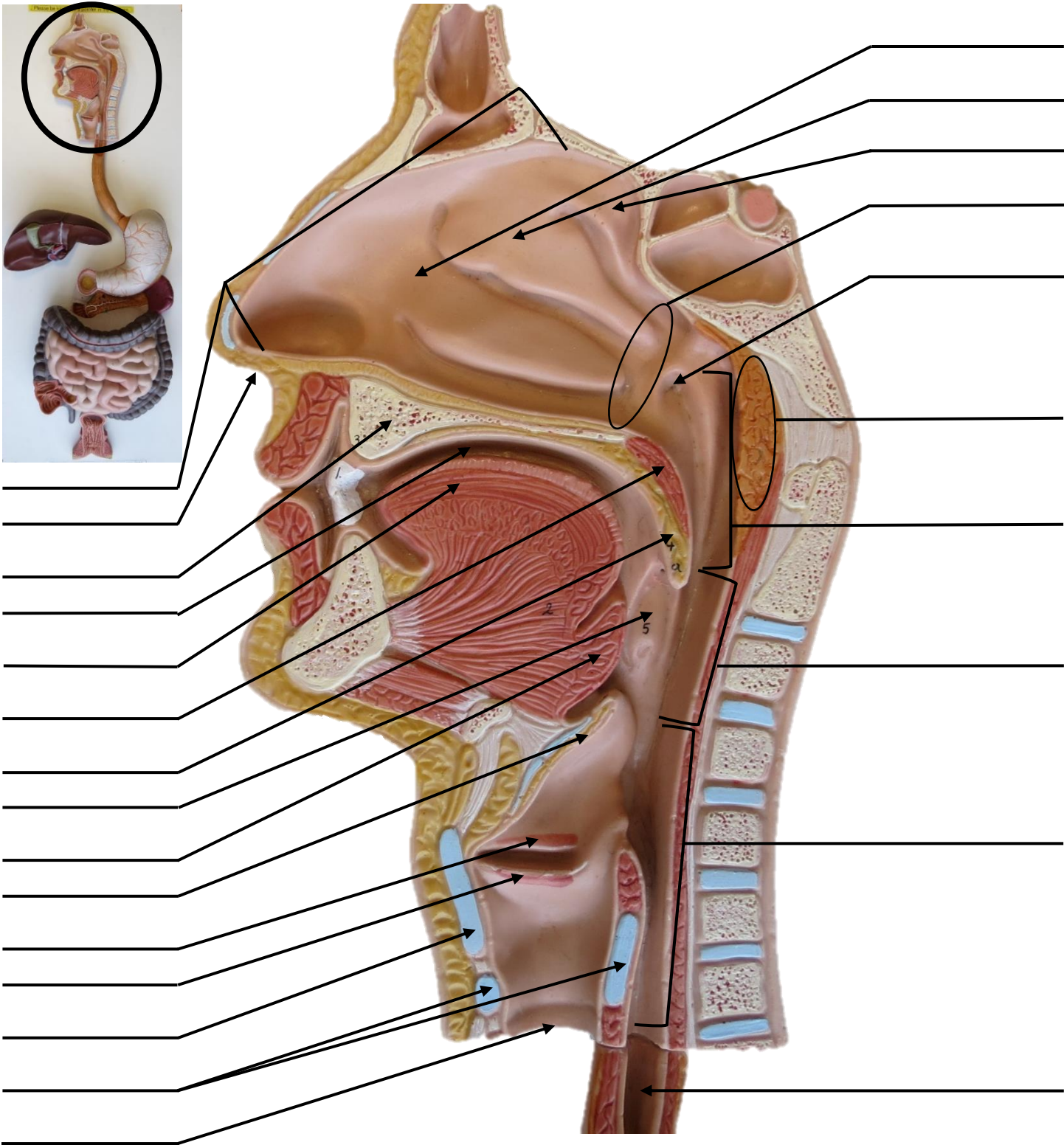
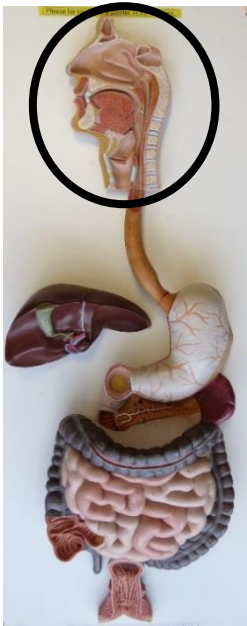

## FLAT DIGESTIVE MODEL

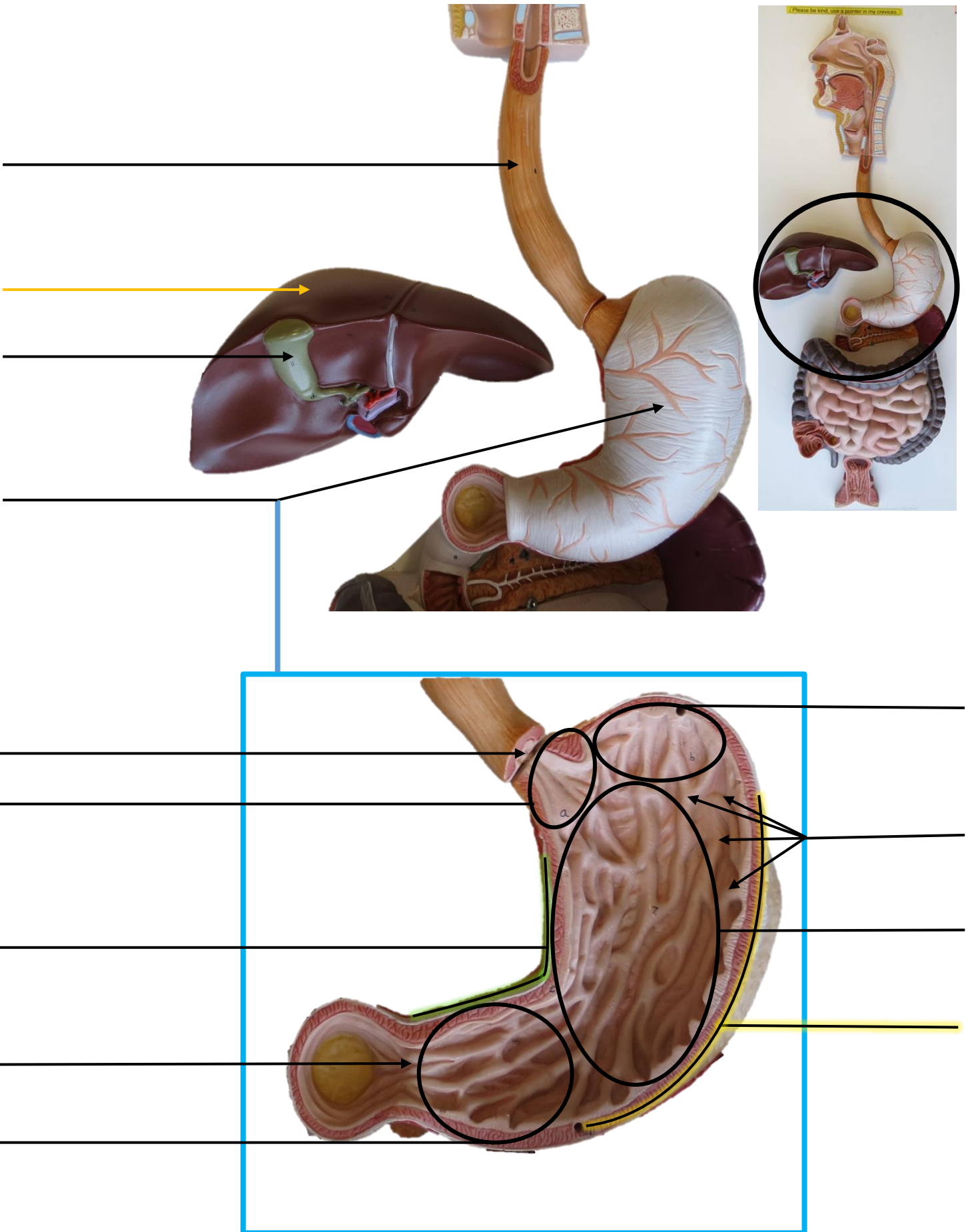




FLAT DIGESTIVE MODEL

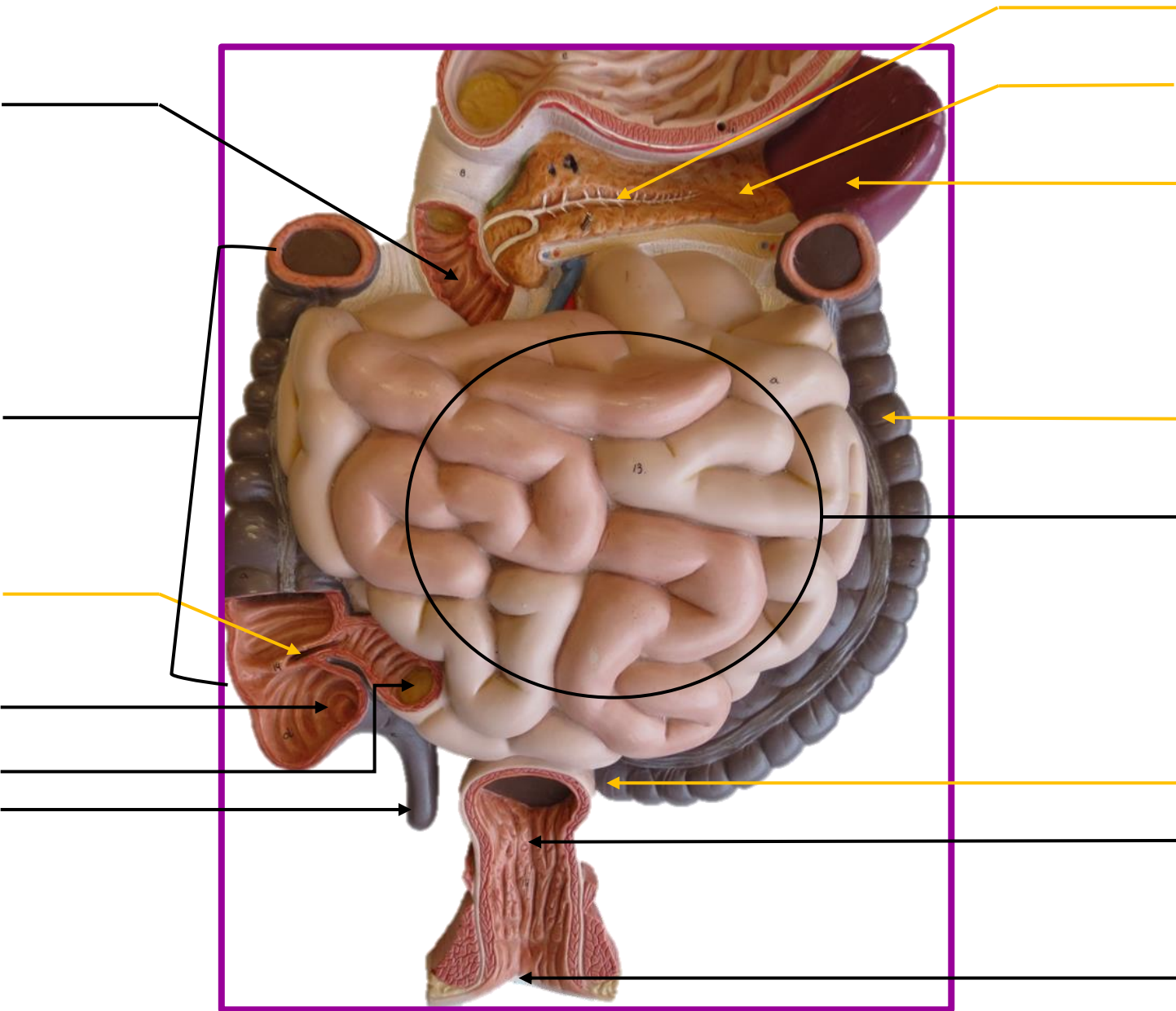
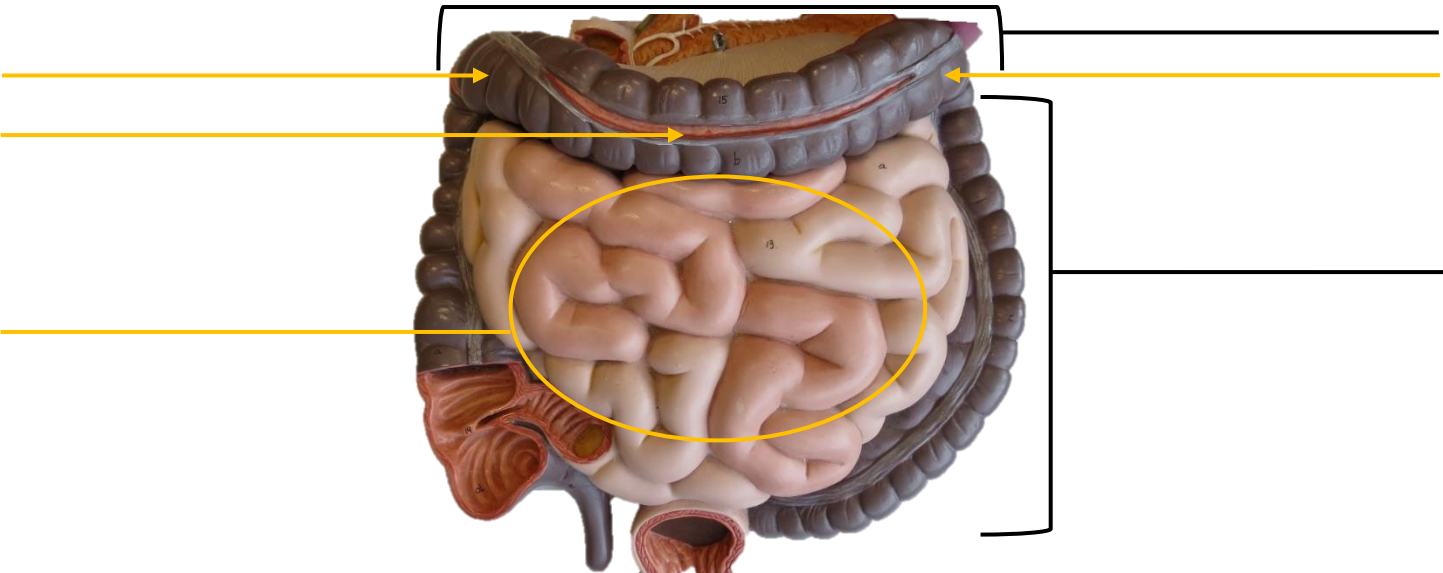


# FLAT DIGESTIVE MODEL

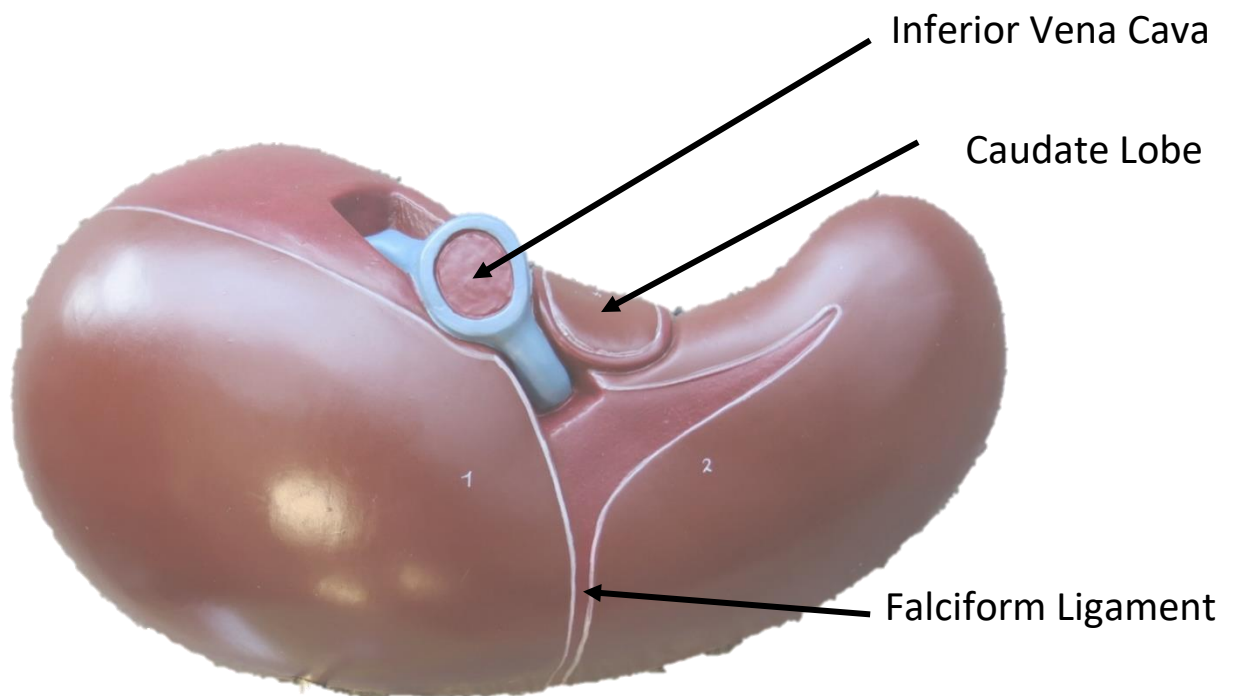
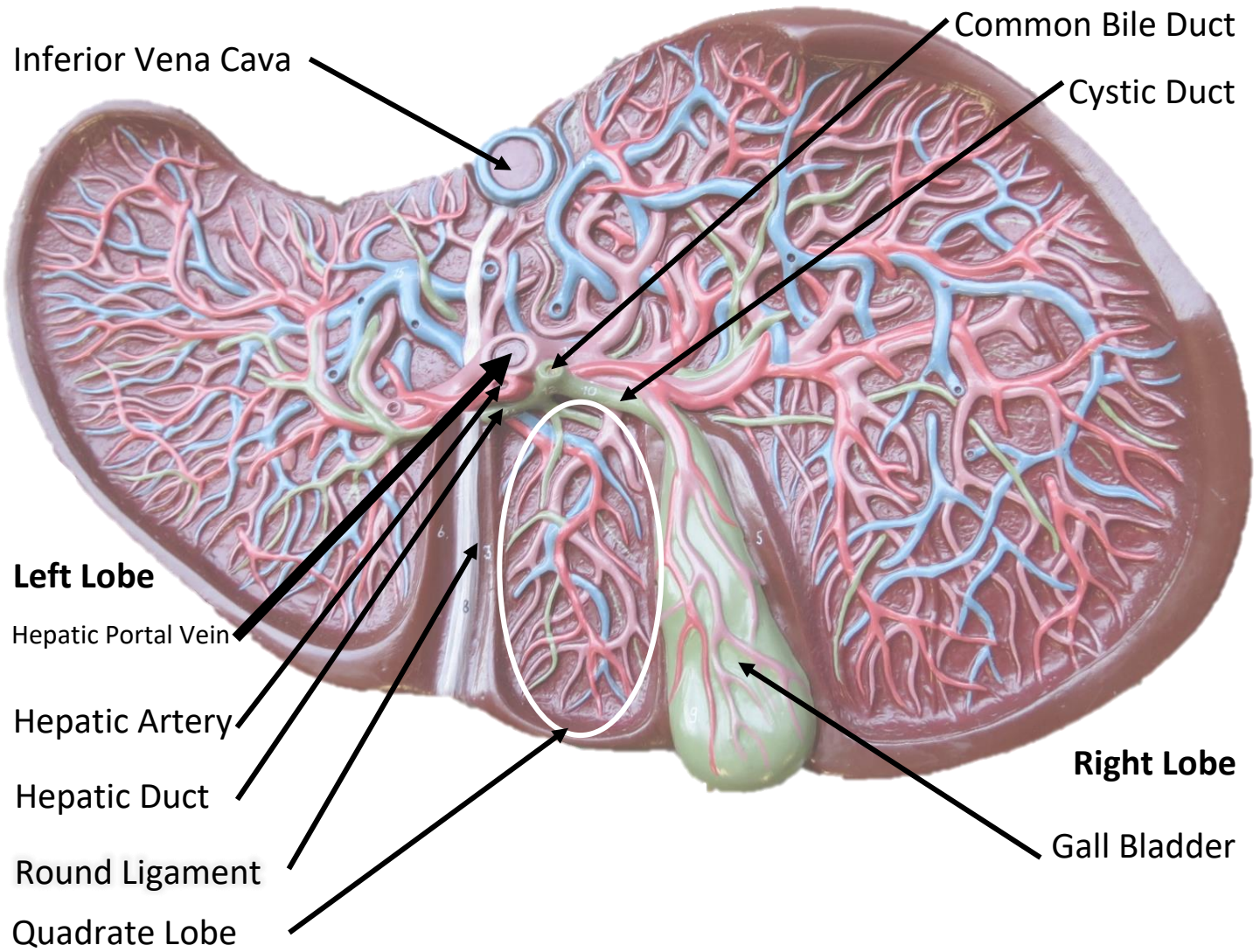




FLAT DIGESTIVE MODEL



# LIVER MODEL





# LIVER MODEL

