

Cell Model

Secretory Vesicle

Smooth Endoplasmic Reticulum

Mitochondria

Fat Vacuole

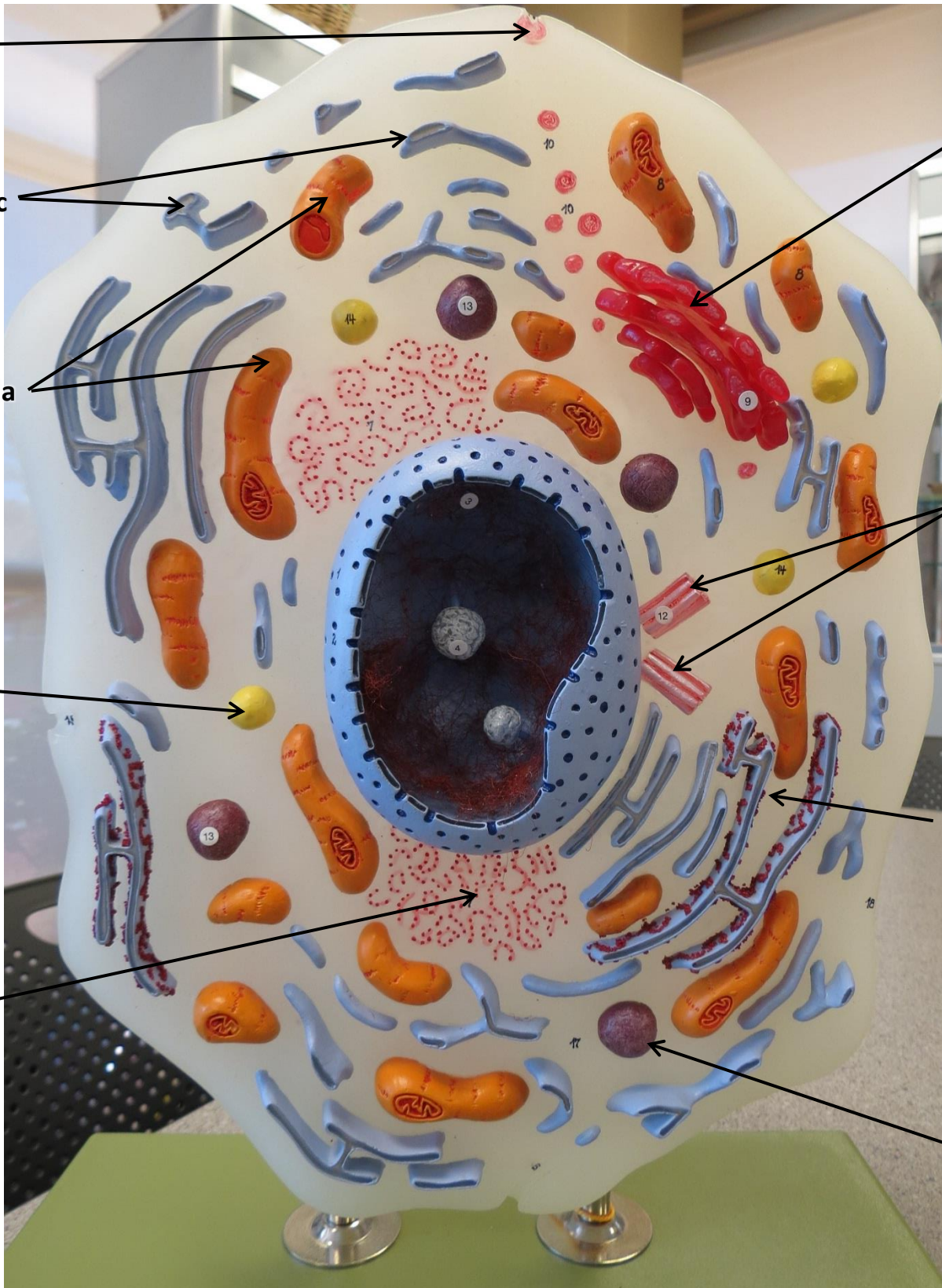
Ribosomes

Golgi Apparatus

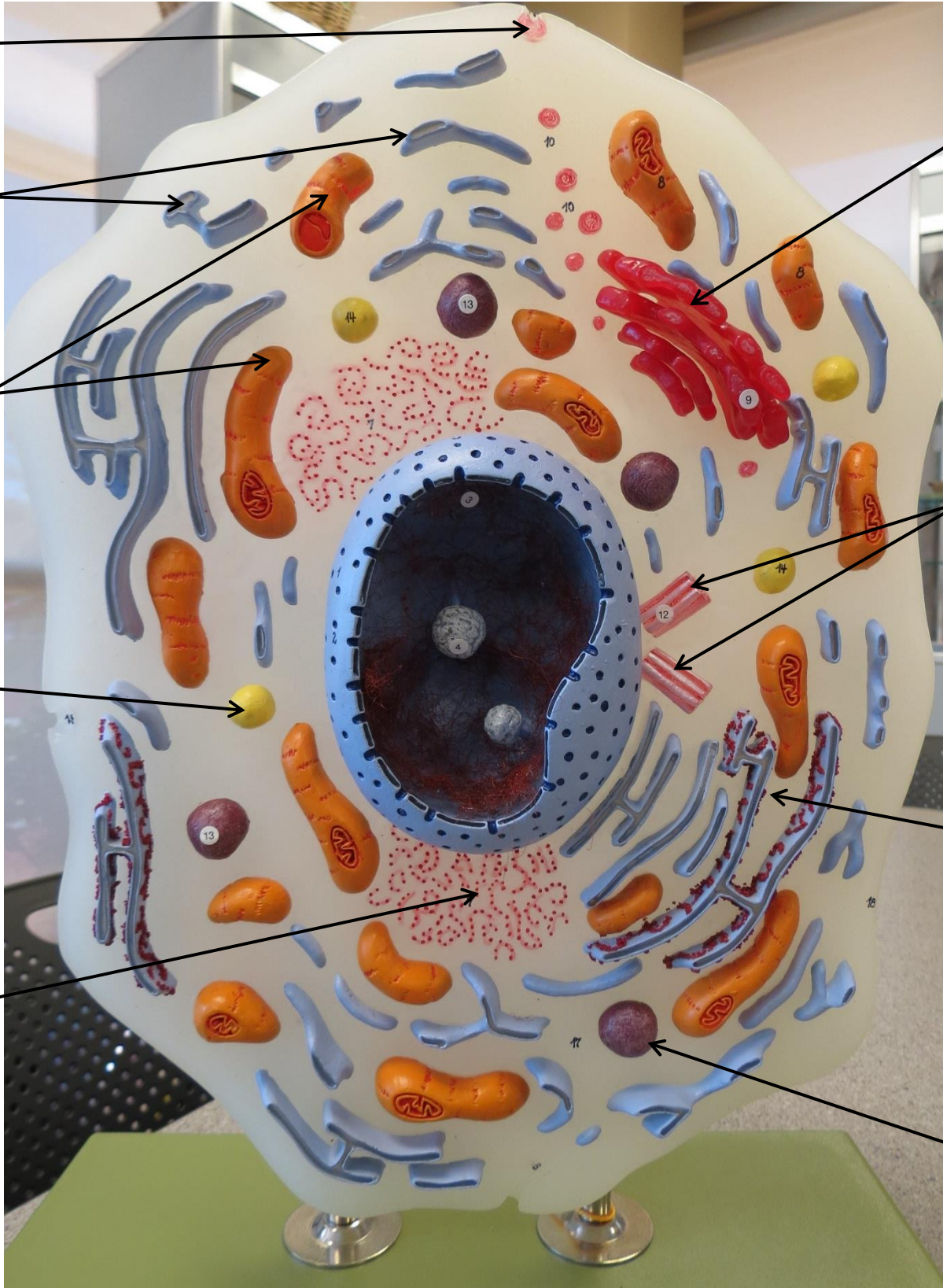
Centrioles

Rough Endoplasmic Reticulum (Note Ribosomes)

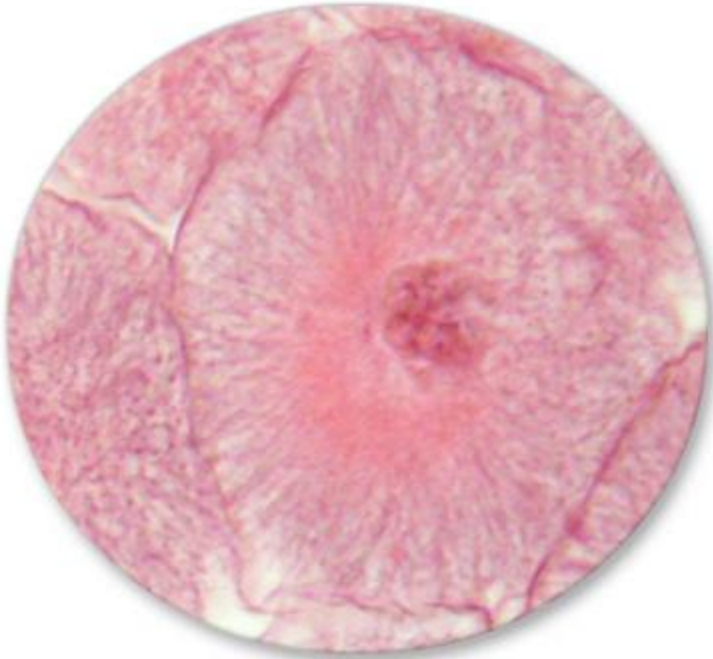Lysosome



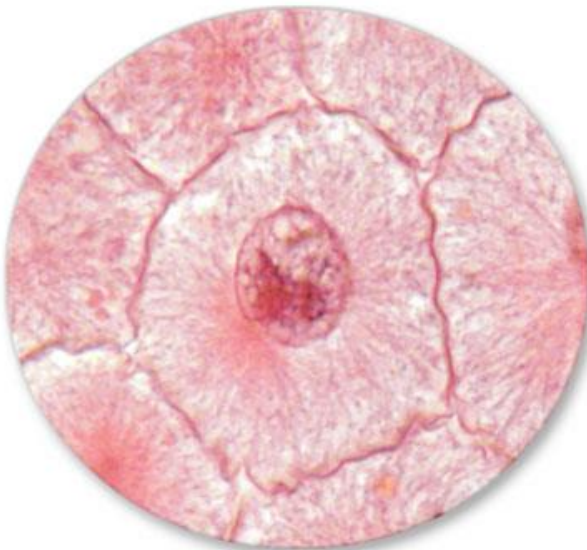Cell Model



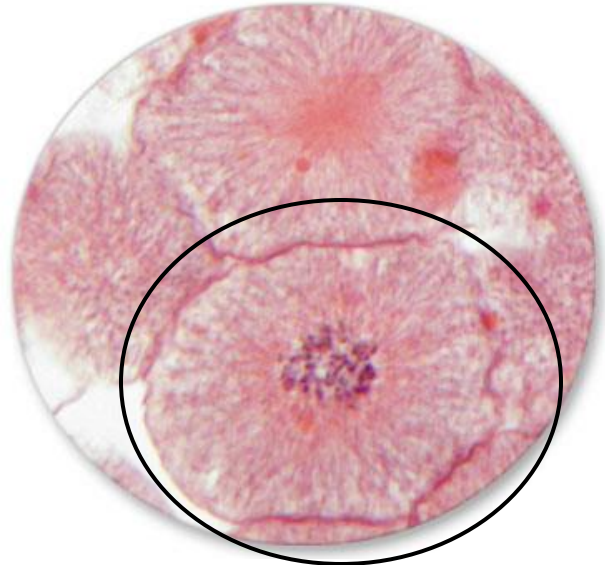MITOSIS SLIDES



INTERPHASE

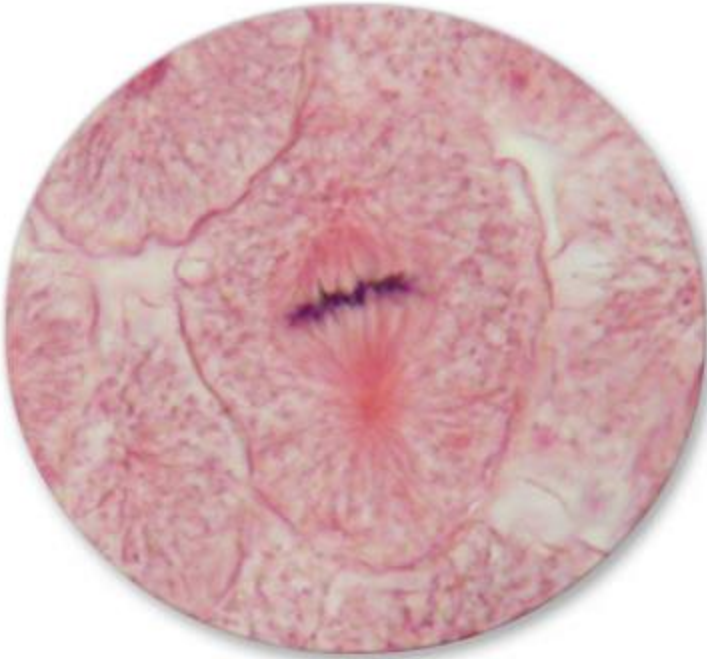

**EARLY
PROPHASE**

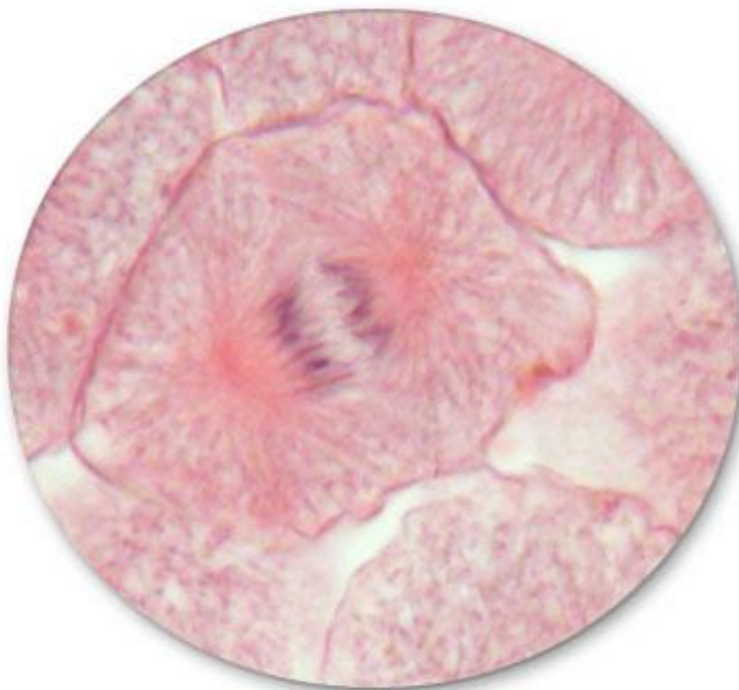

**LATE
PROPHASE**

MITOSIS SLIDES

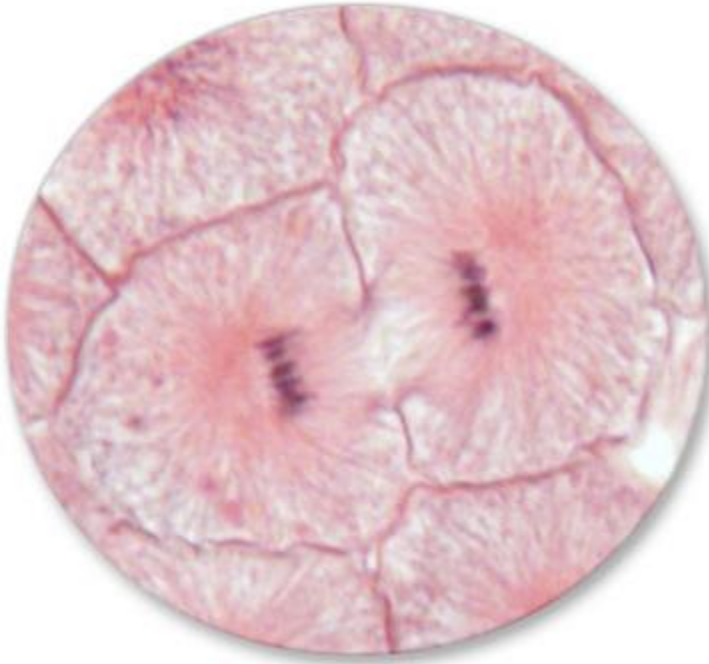

METAPHASE



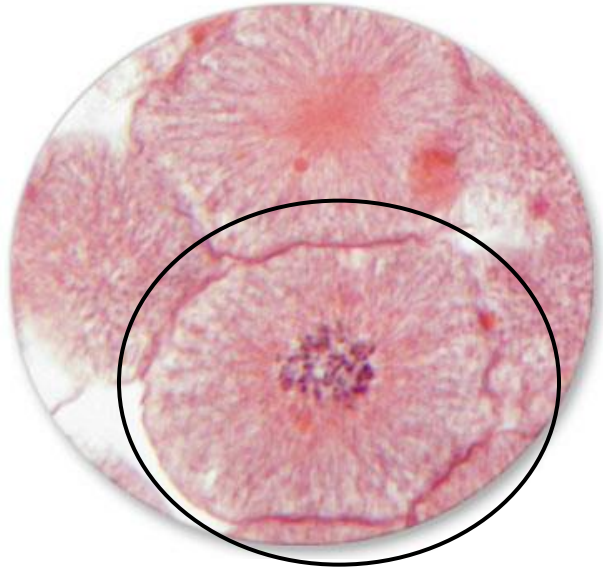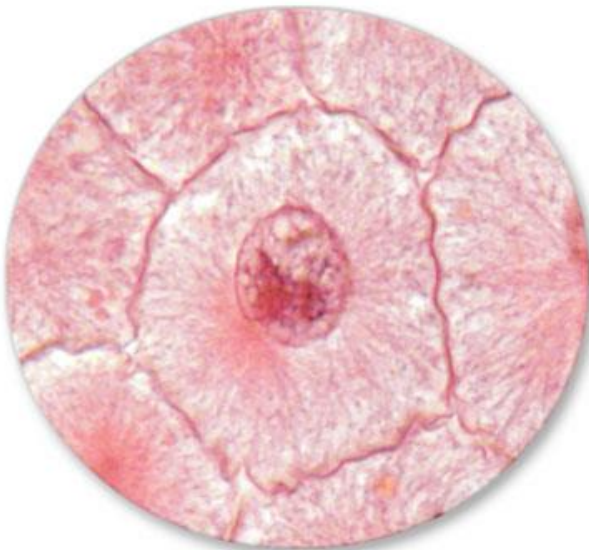ANAPHASE

MITOSIS SLIDES



TELOPHASE

MITOSIS SLIDES



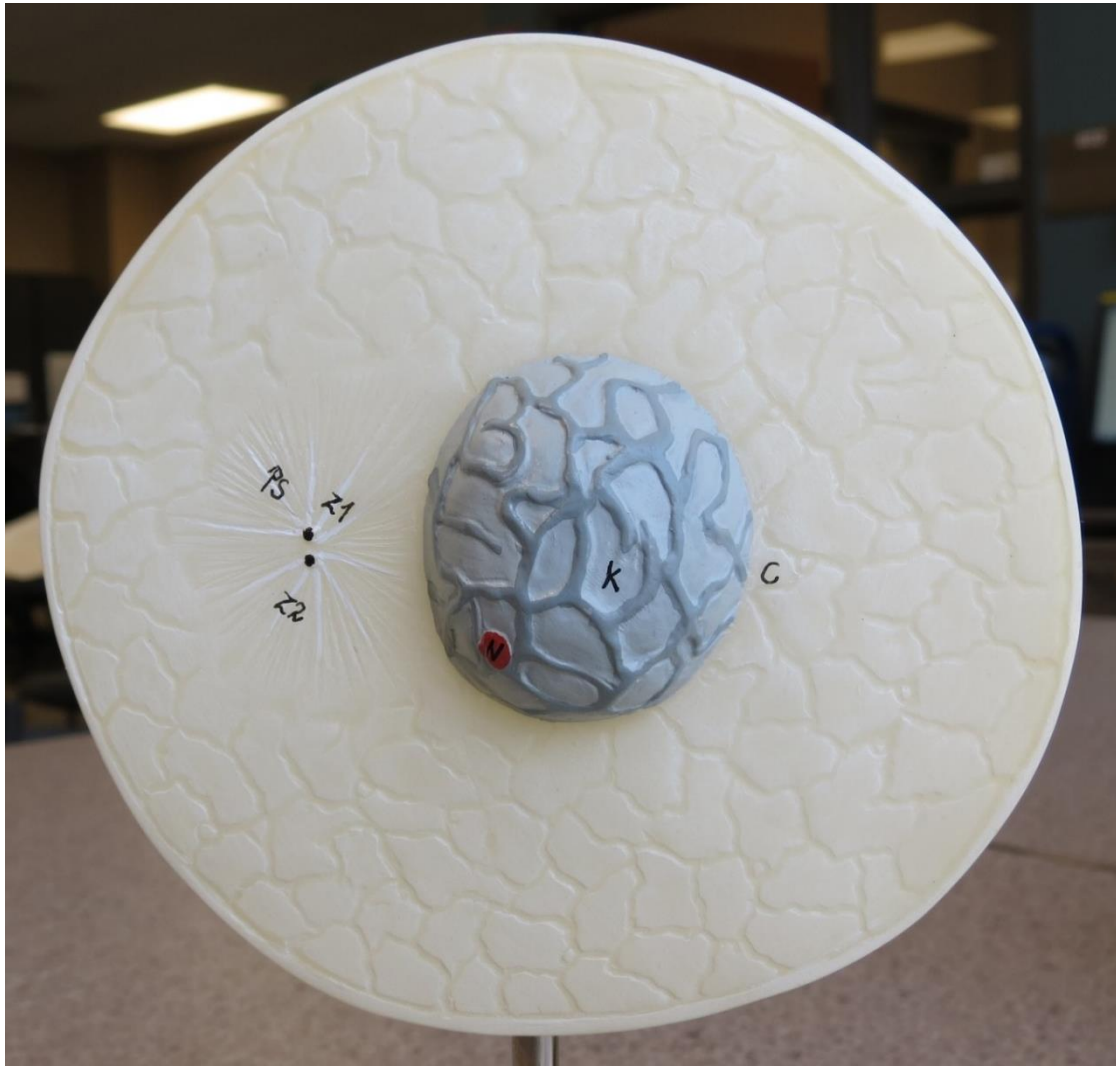
MITOSIS SLIDES



MITOSIS SLIDES



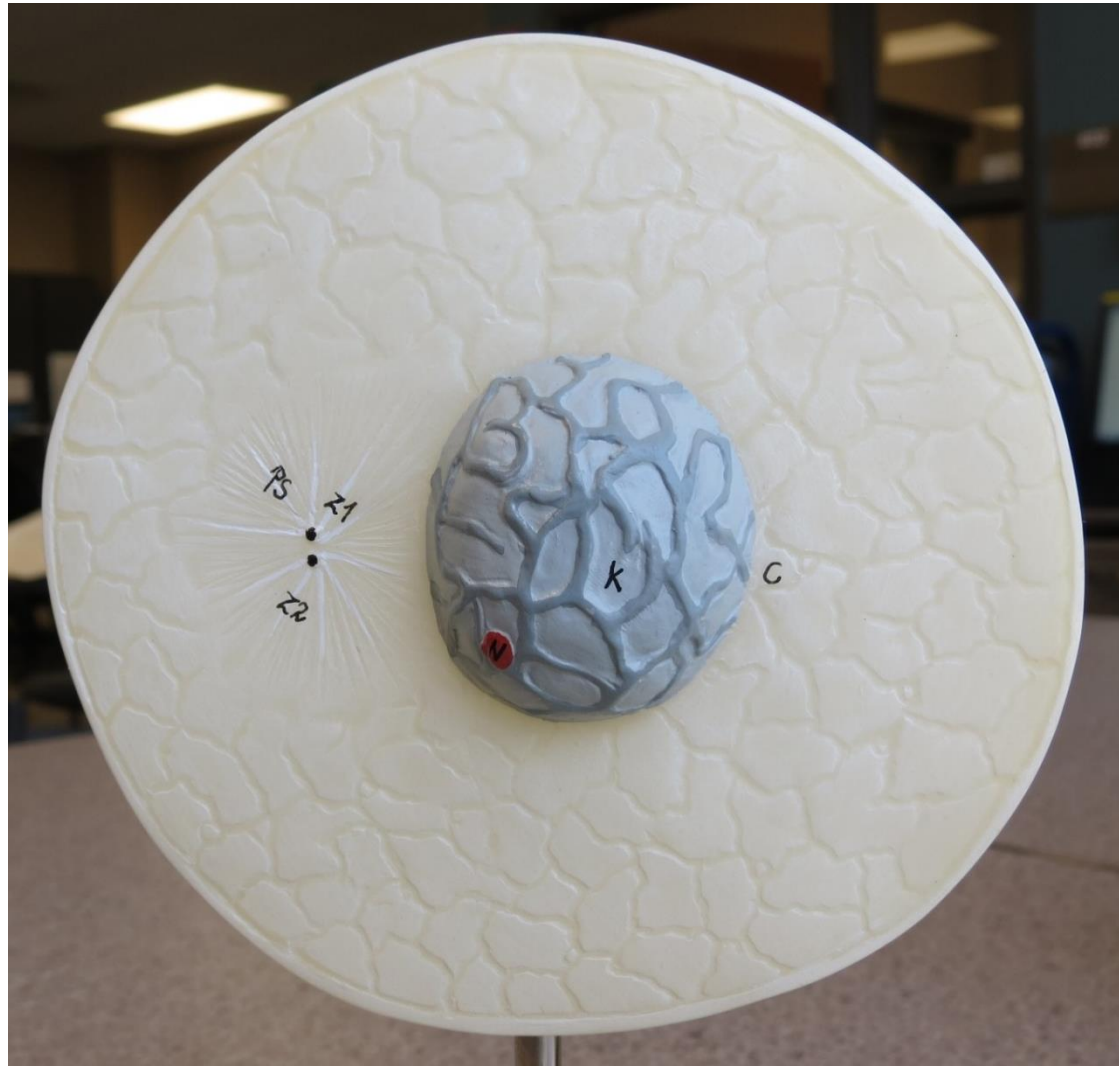
MITOSIS MODEL



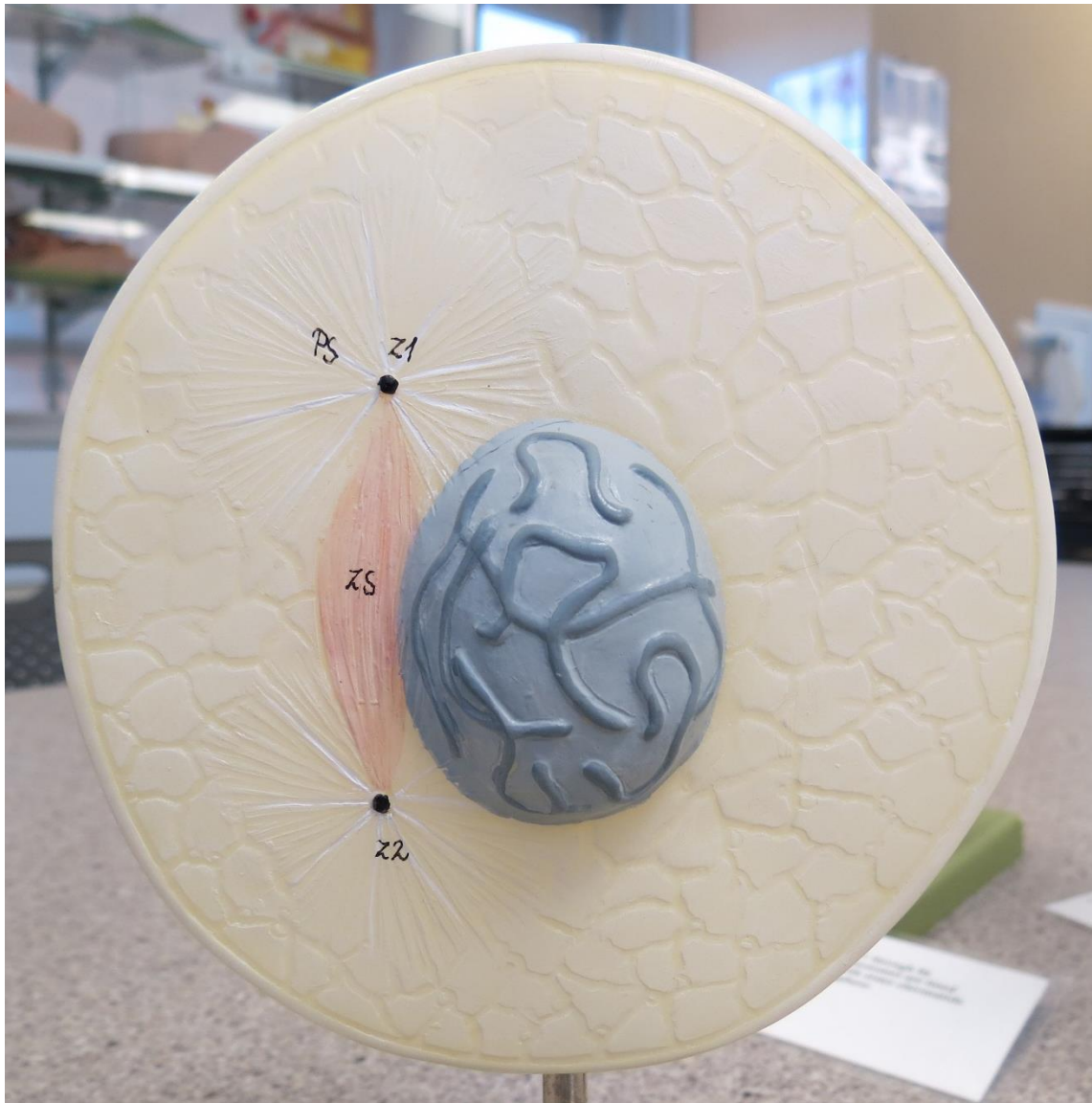
**Nucleus is intact.
Centrioles are close
together**

Interphase

MITOSIS MODEL



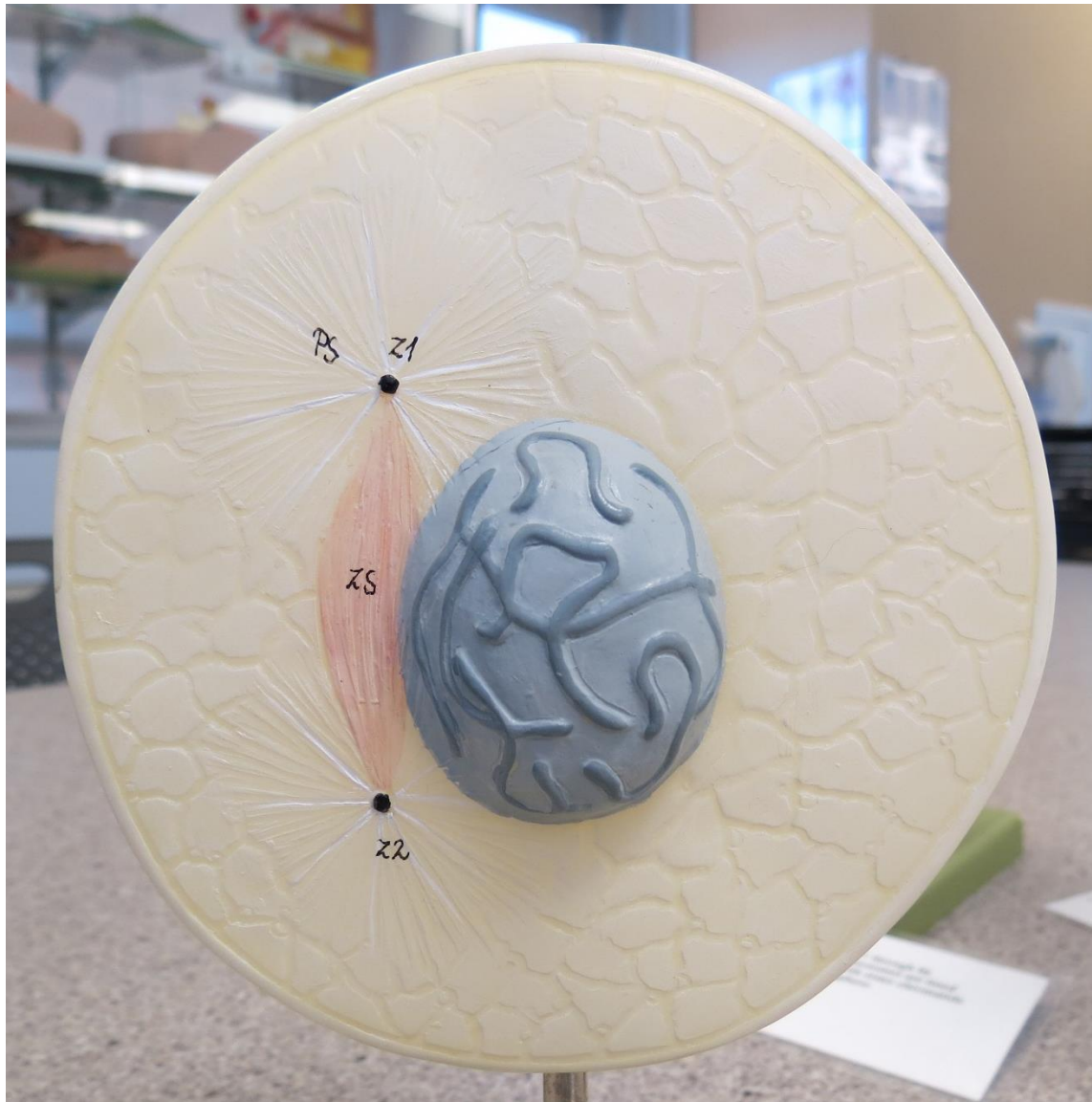
MITOSIS MODEL




**Centrioles are
moving apart.
Nucleus (with chromatin)
is still intact.**

Early Prophase

MITOSIS MODEL




MITOSIS MODEL




Centrioles are at opposite ends. Nucleus breaks apart, forming chromosomes.

Late Prophase

MITOSIS MODEL



MITOSIS MODEL




Spindle Fiber

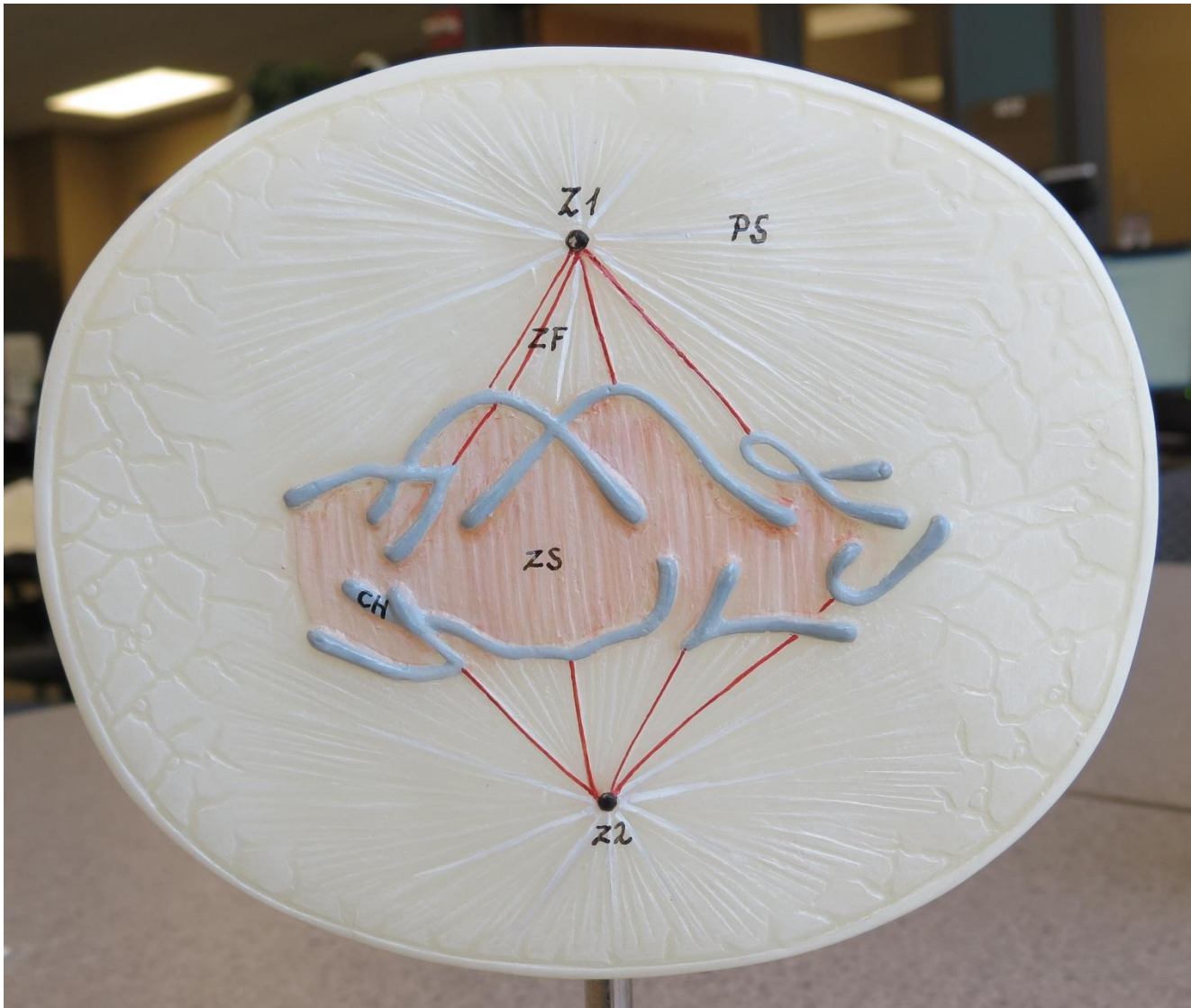
Chromosomes
are aligned in the
middle of the cell
forming sister
chromatids.

Metaphase

MITOSIS MODEL



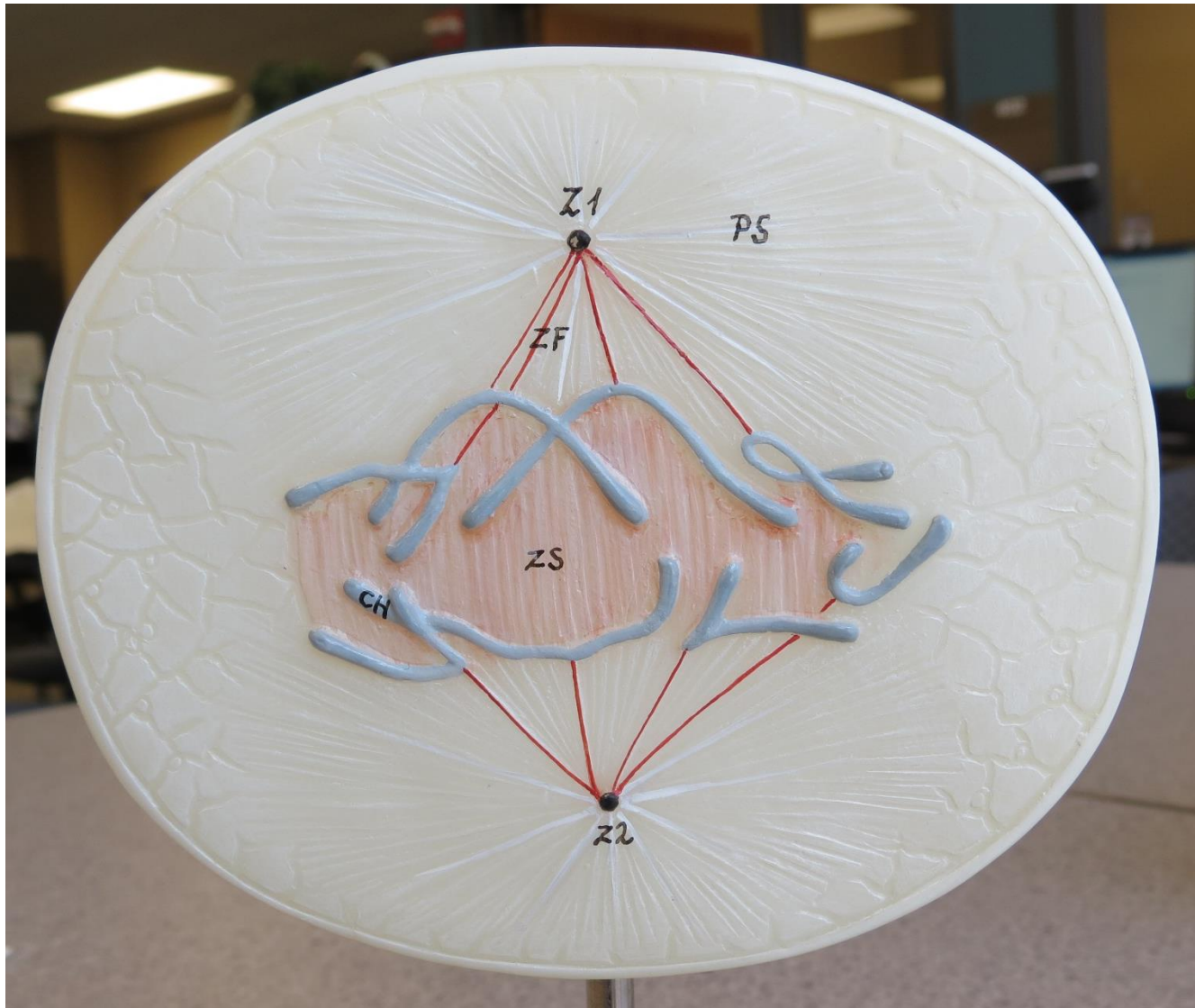
MITOSIS MODEL



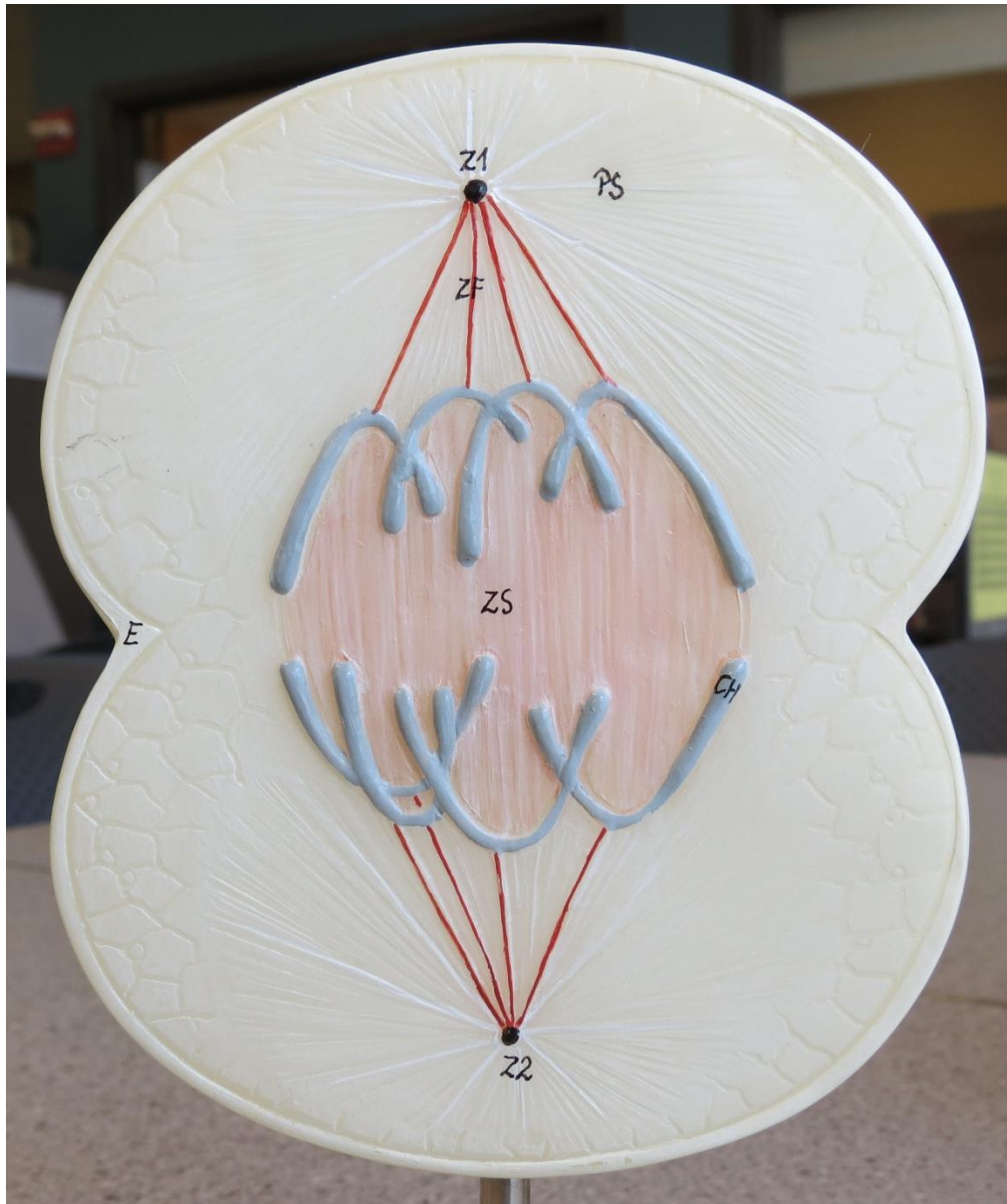
**Sister chromatids
separate forming
daughter
chromosomes.**

Anaphase

MITOSIS MODEL




MITOSIS MODEL




**Daughter
chromosomes become
further separated.**

Late Anaphase

MITOSIS MODEL



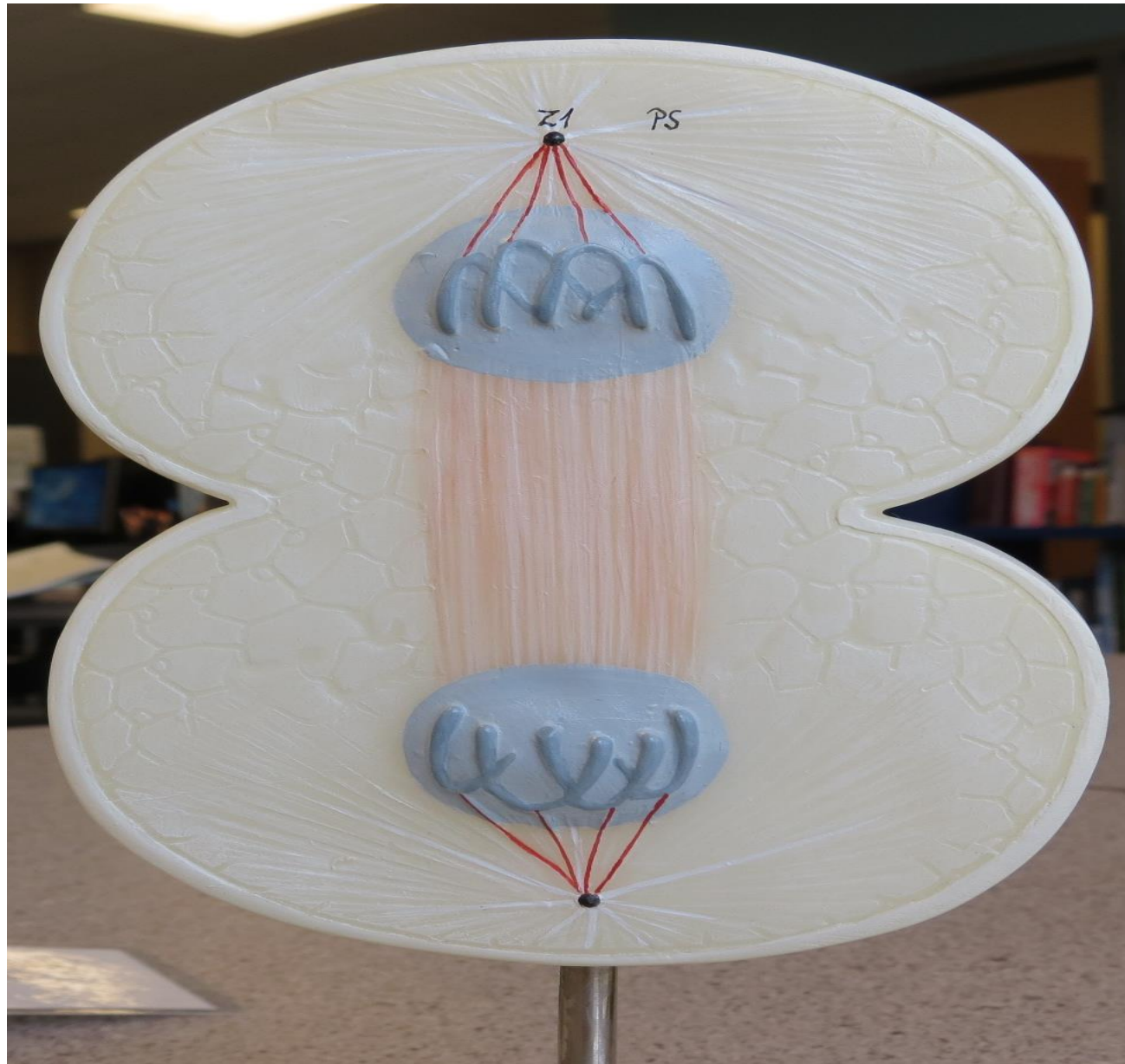
MITOSIS MODEL



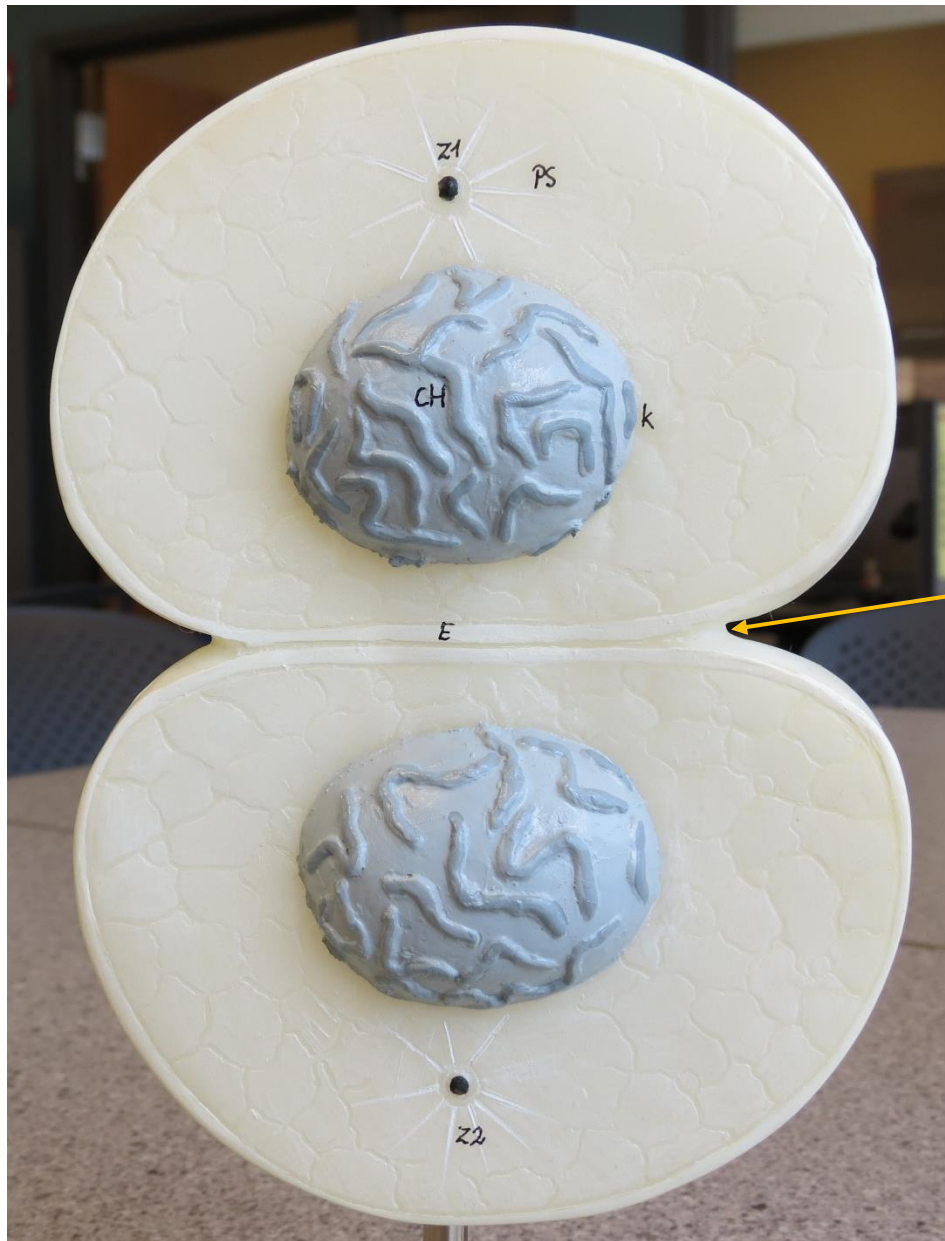
Chromosomes have completed their separation forming new nuclei. Cytokinesis causes cleavage furrow.

Telophase

MITOSIS MODEL



MITOSIS MODEL

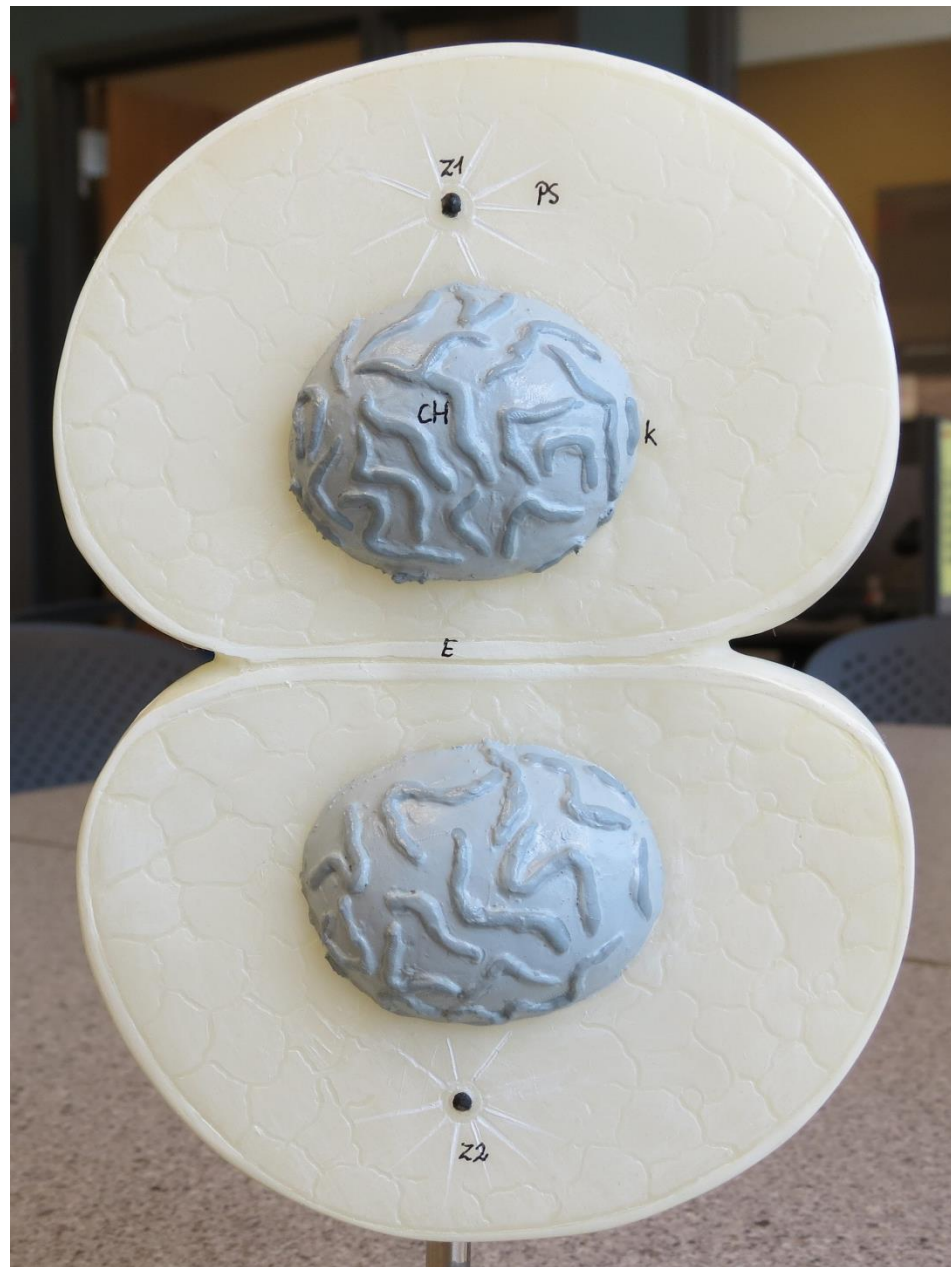

(Note cell boundary
between cells.)

**Cytokinesis has been
completed. We now have 2
individual cells.**

Daughter Cells/ Interphase

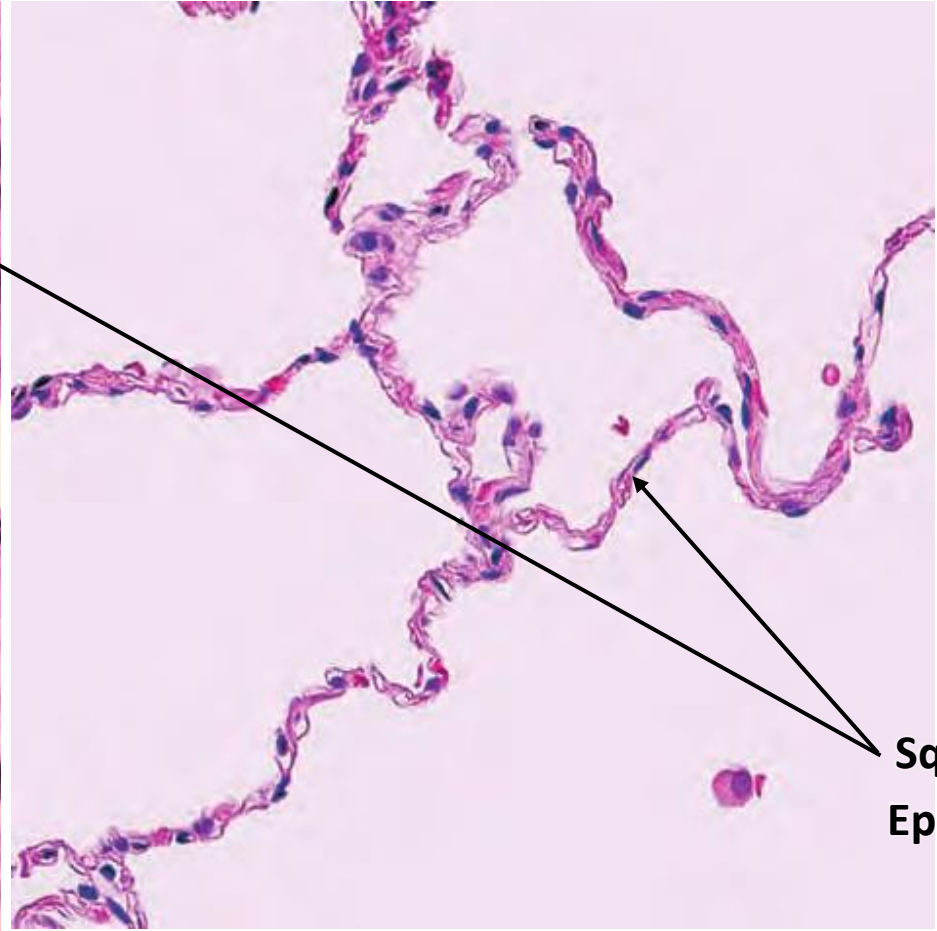
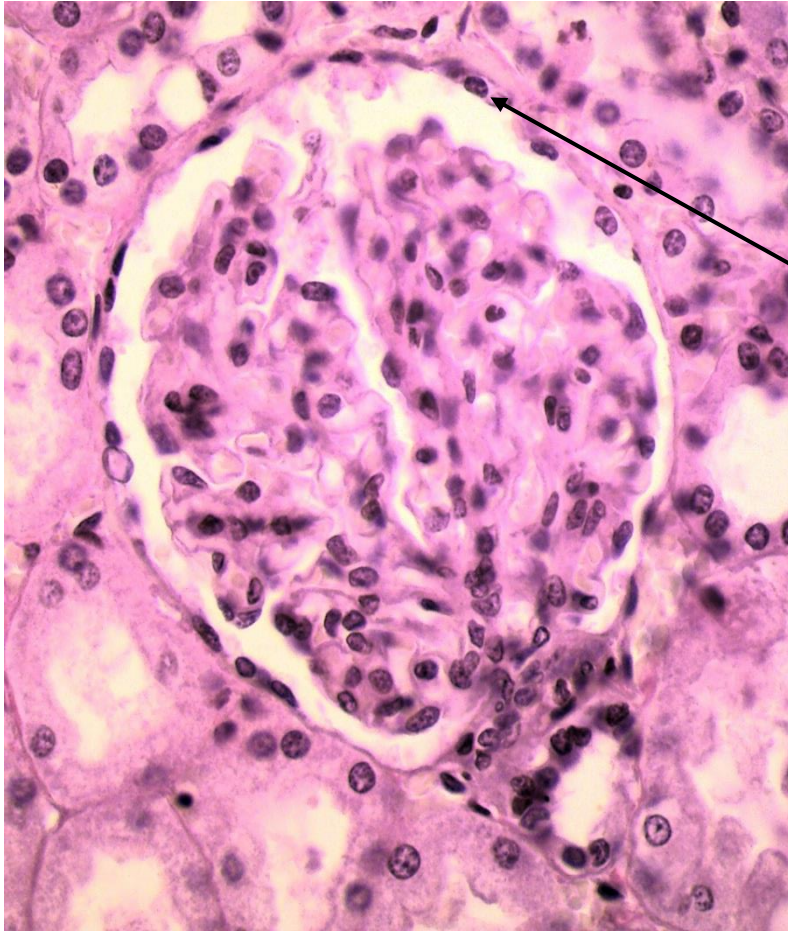
MITOSIS MODEL



SIMPLE SQUAMOUS EPITHELIUM

Function: Diffusion and filtration

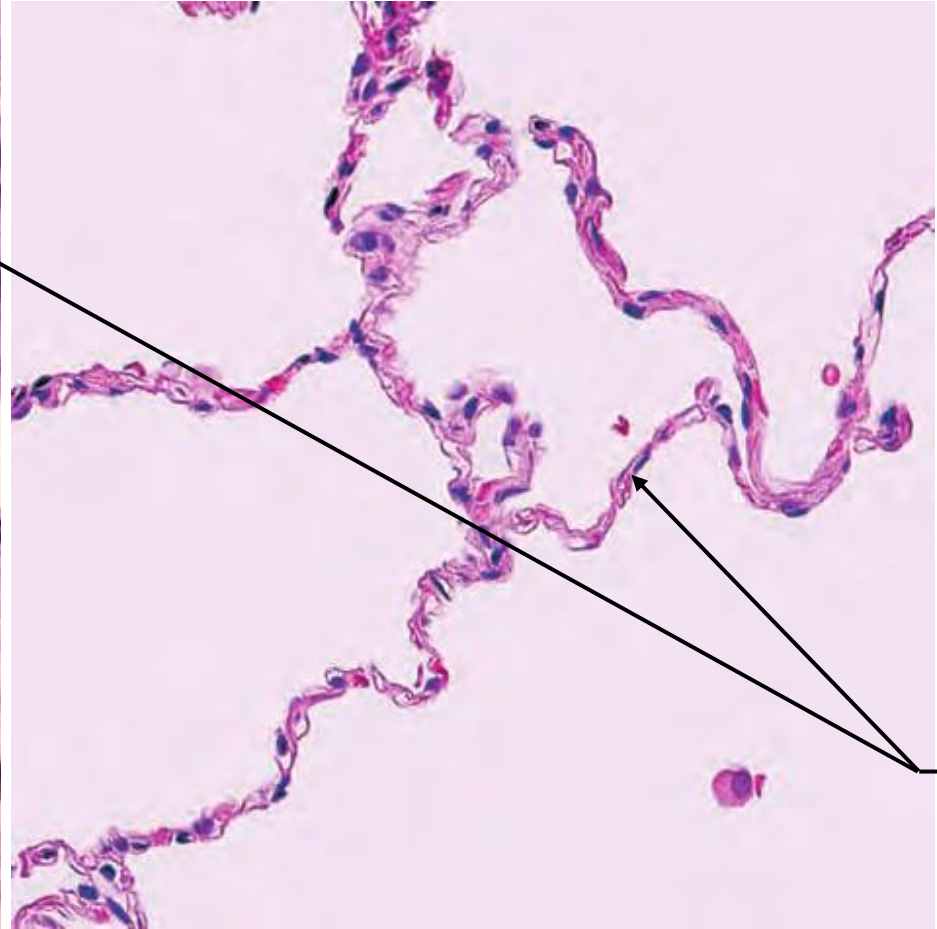
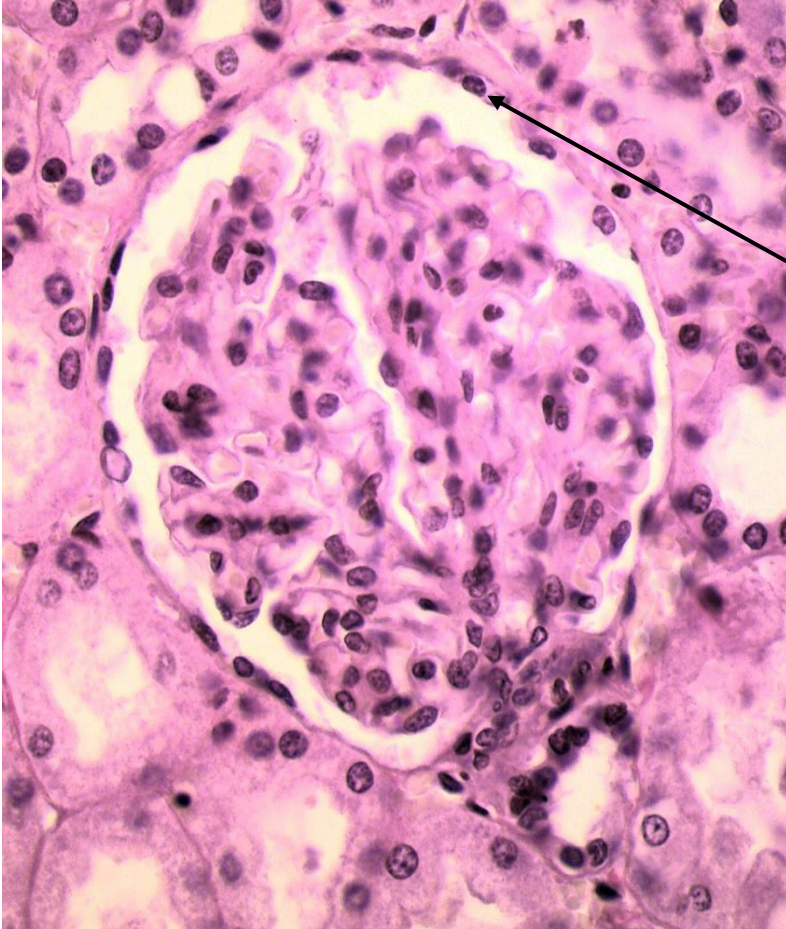
Location: Lung alveoli, kidney glomerulus, capillary walls



Simple
Squamous
Epithelium

Function: _____

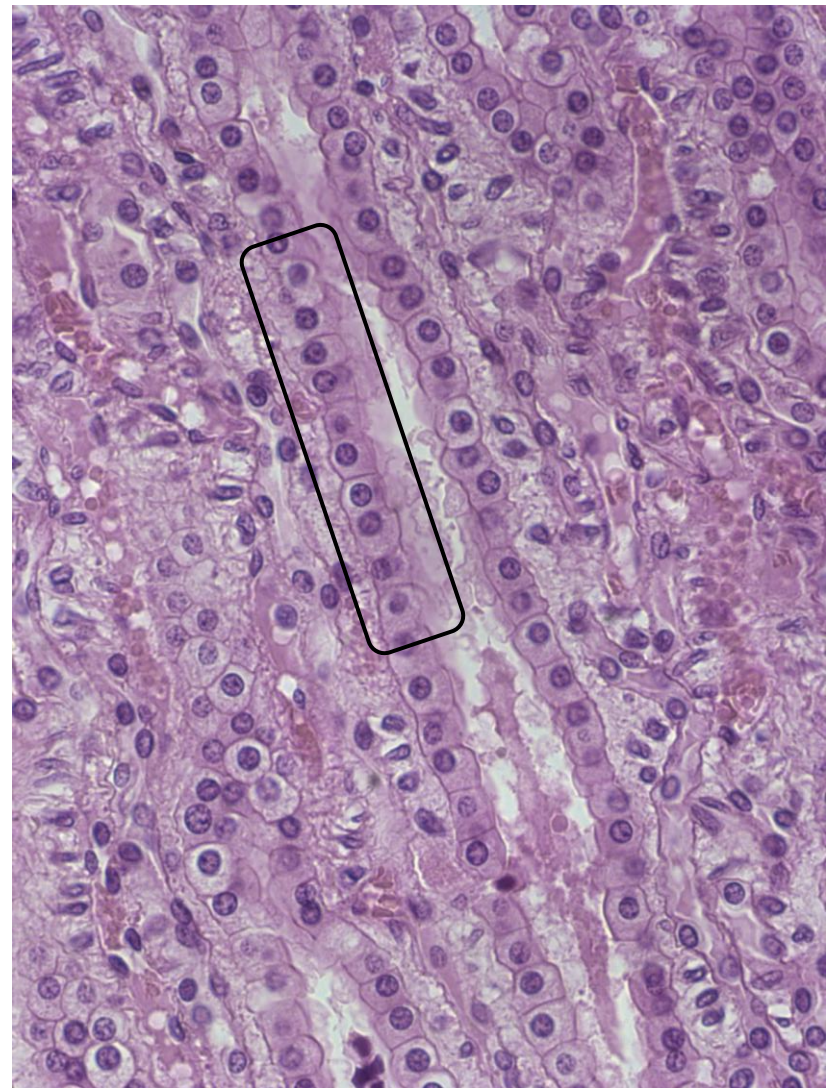
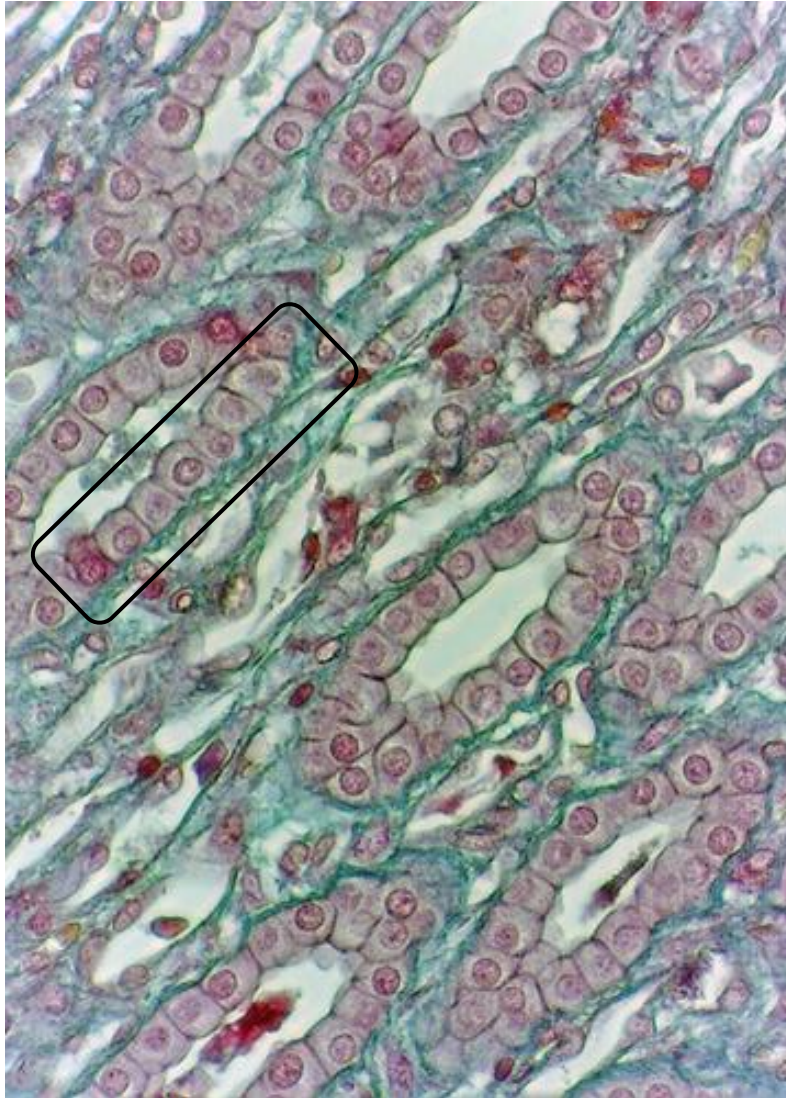
Location: _____



SIMPLE CUBOIDAL EPITHELIUM

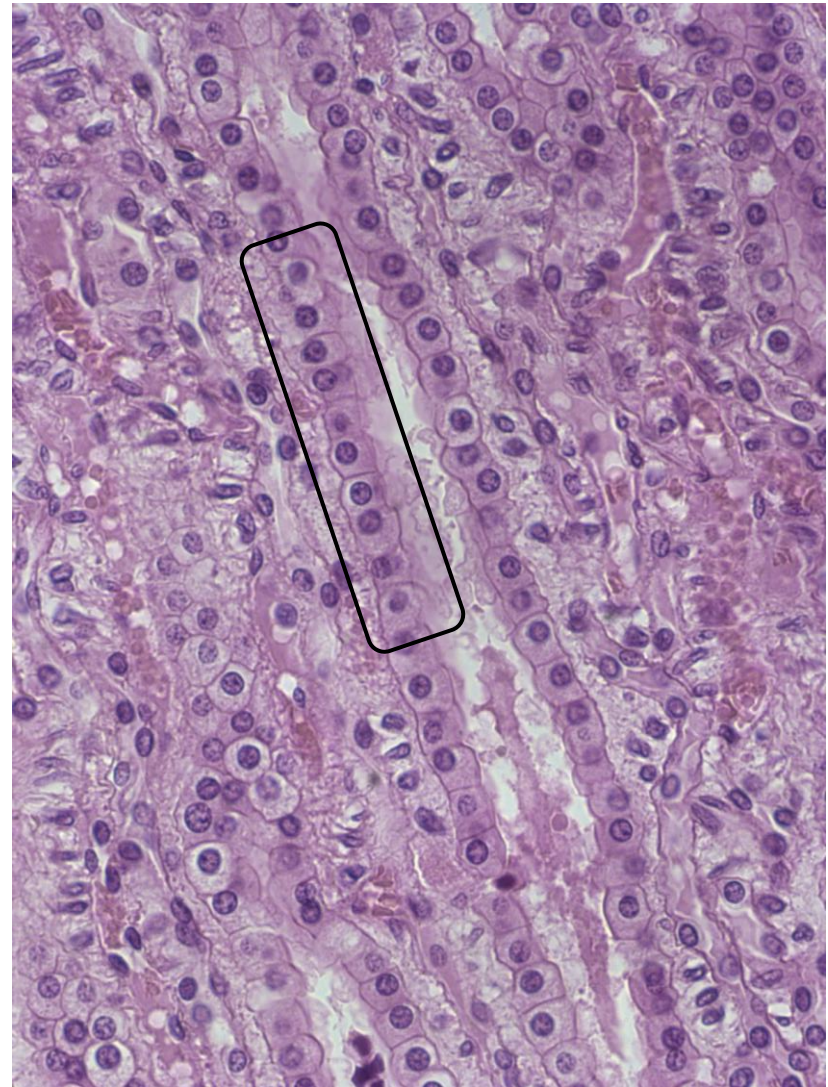
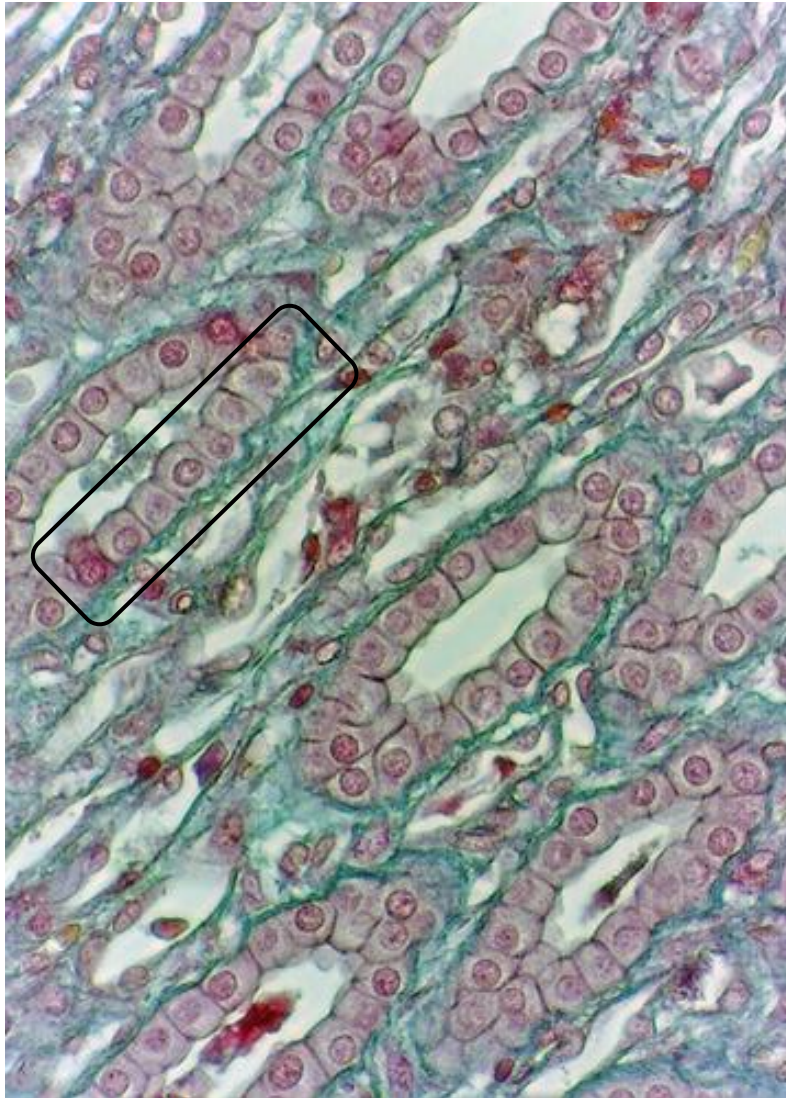
Function: Secretion and some absorption

Location: Any secretory gland, kidney tubules and other ducts



Function: _____

Location: _____



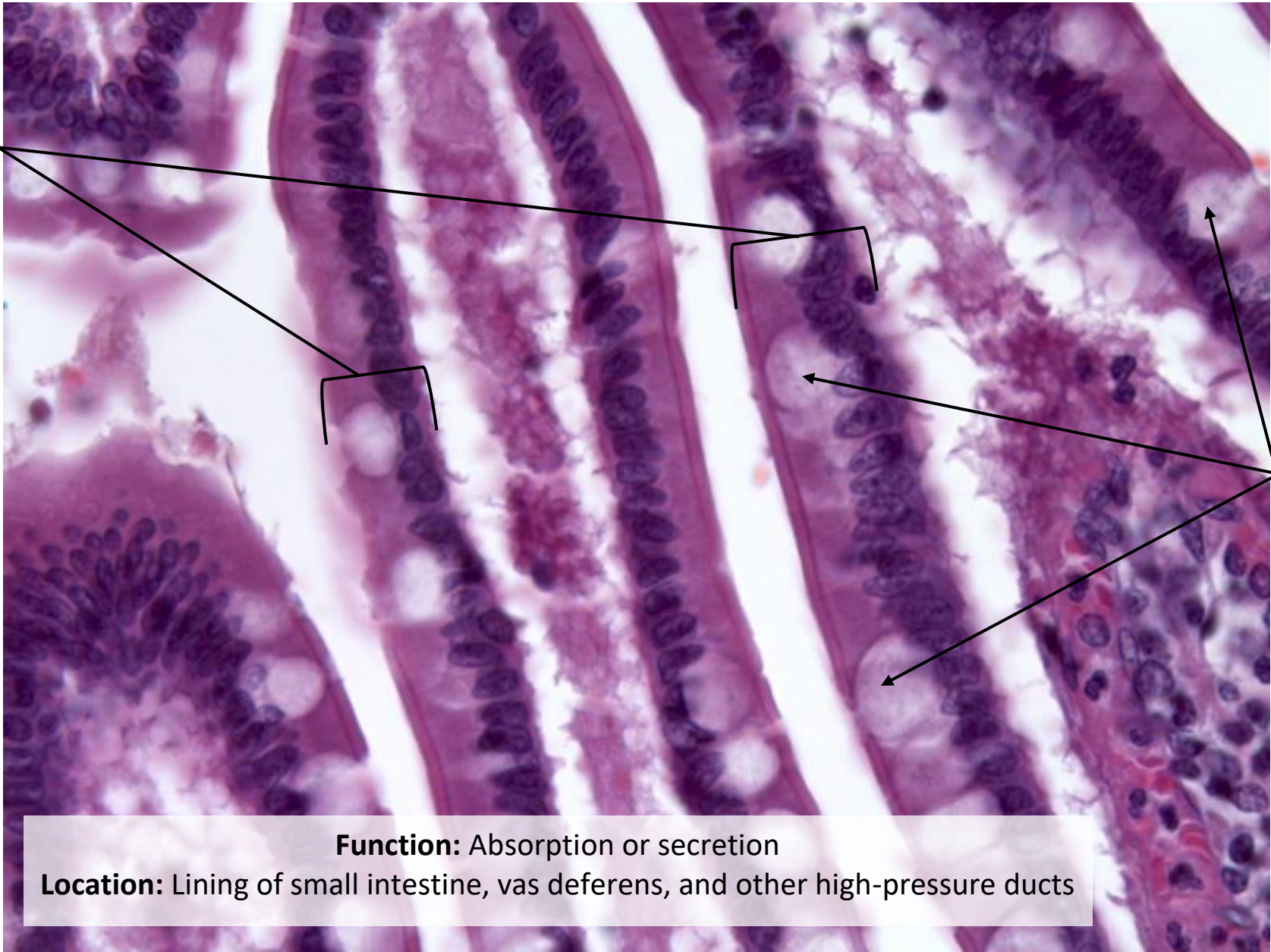
SIMPLE COLUMNAR EPITHELIUM

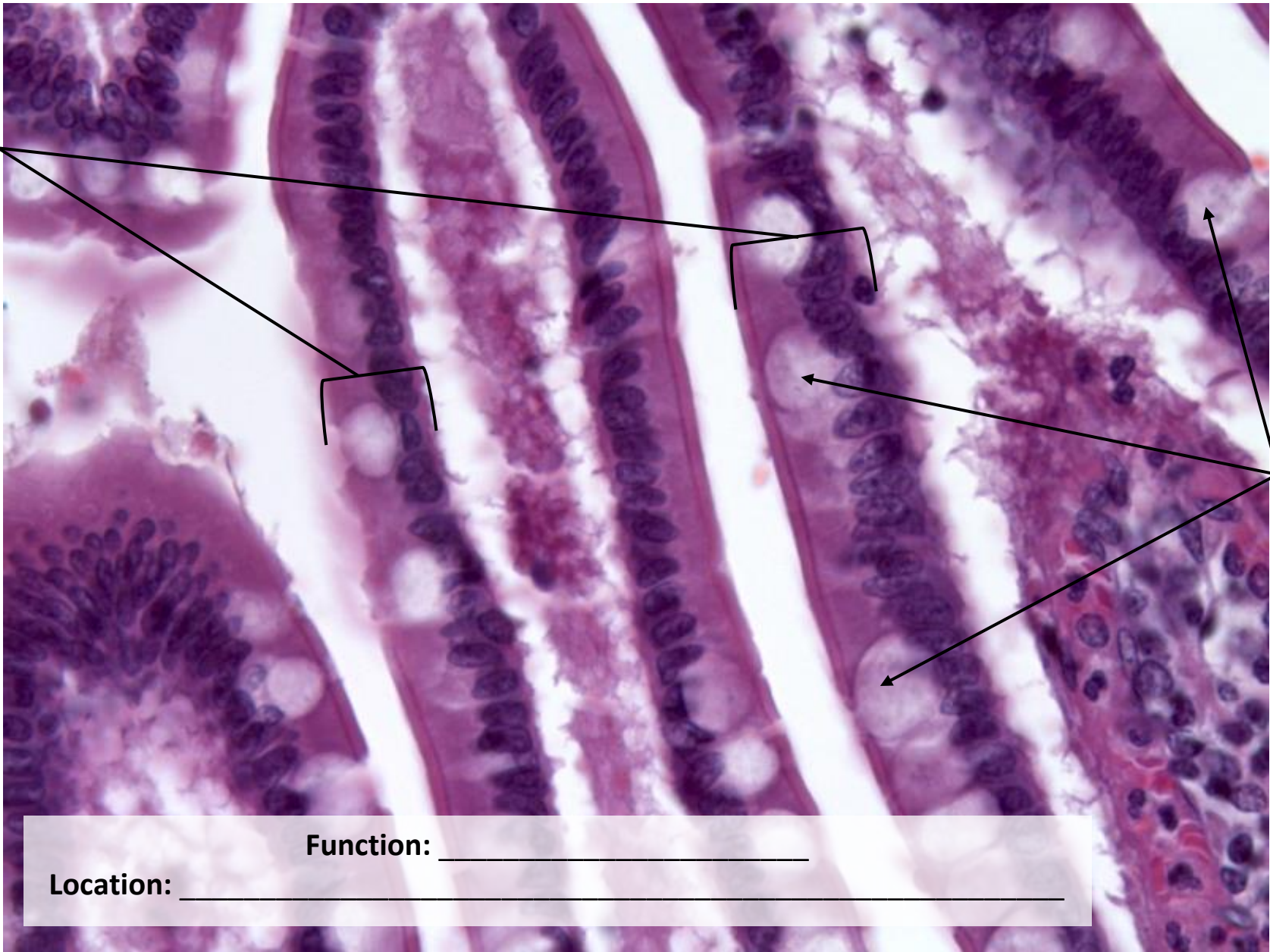Simple
Columnar
Epithelium

Goblet
Cells

Function: Absorption or secretion

Location: Lining of small intestine, vas deferens, and other high-pressure ducts





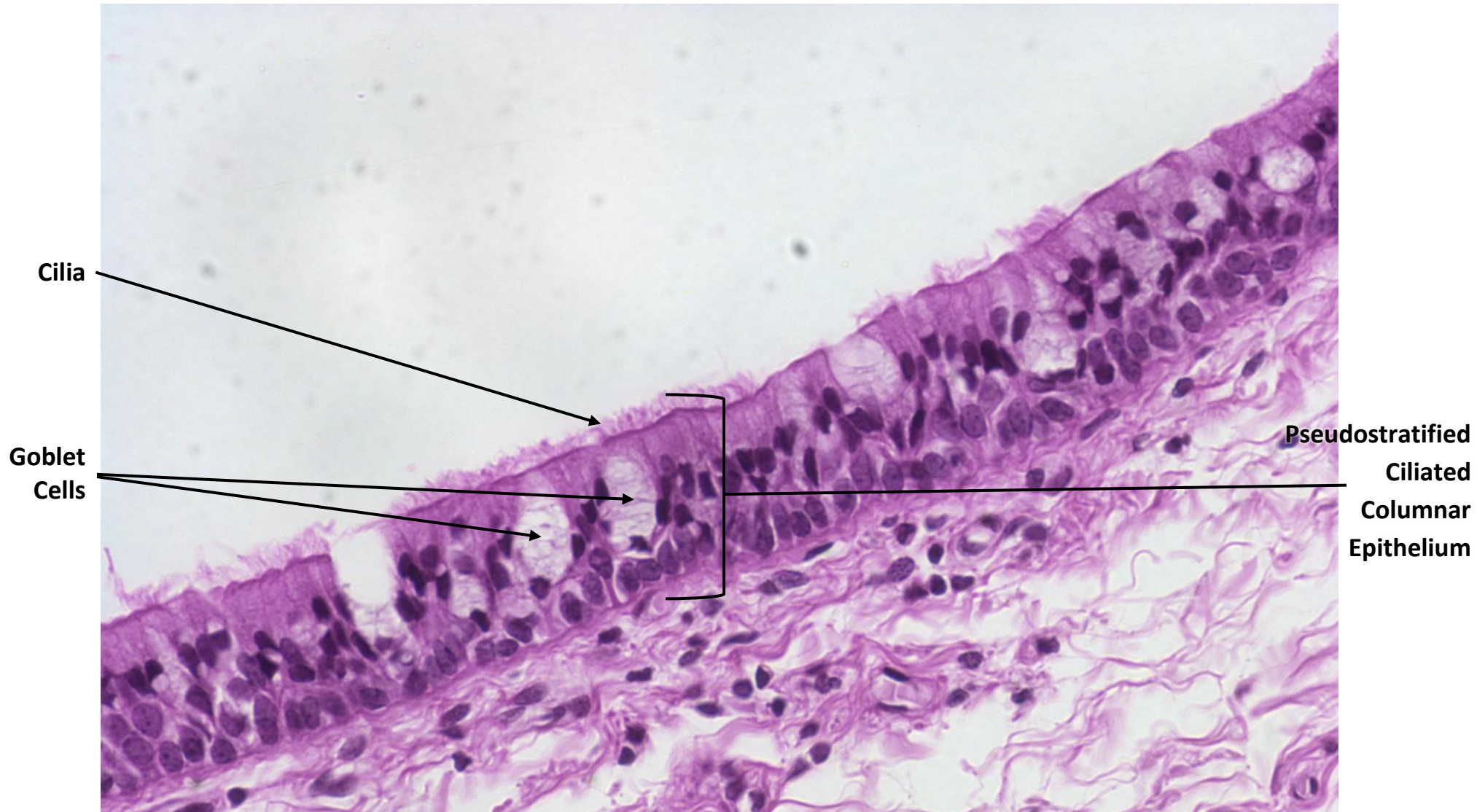
Function: _____

Location: _____

PSEUDOSTRATIFIED CILIATED COLUMNAR EPITHELIUM

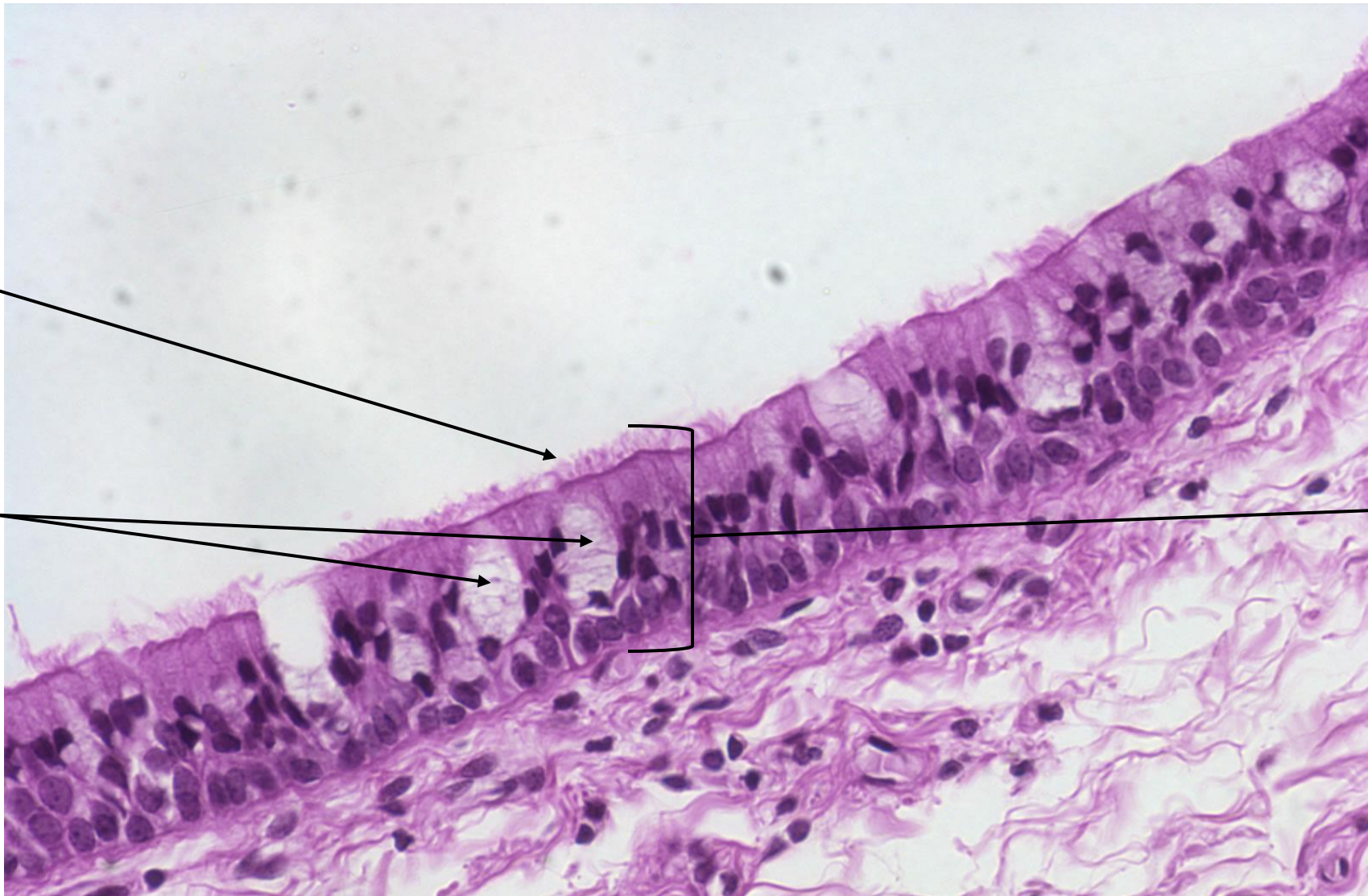
Function: Protection, removal of foreign material

Location: Nasal cavities, sinuses, pharynx, trachea, and bronchi of lungs



Function: _____

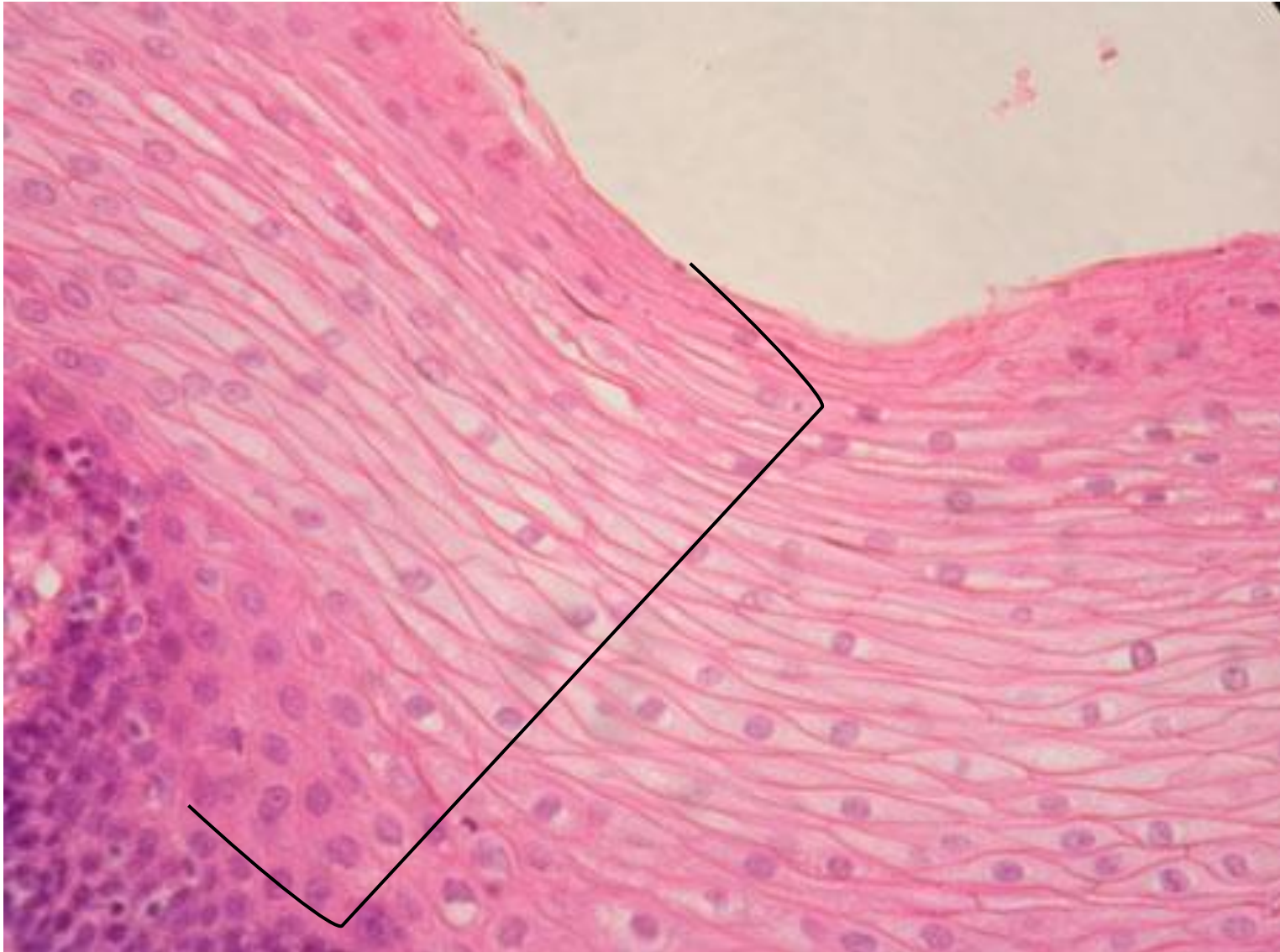
Location: _____



STRATIFIED SQUAMOUS EPITHELIUM

Function: Protection against abrasion

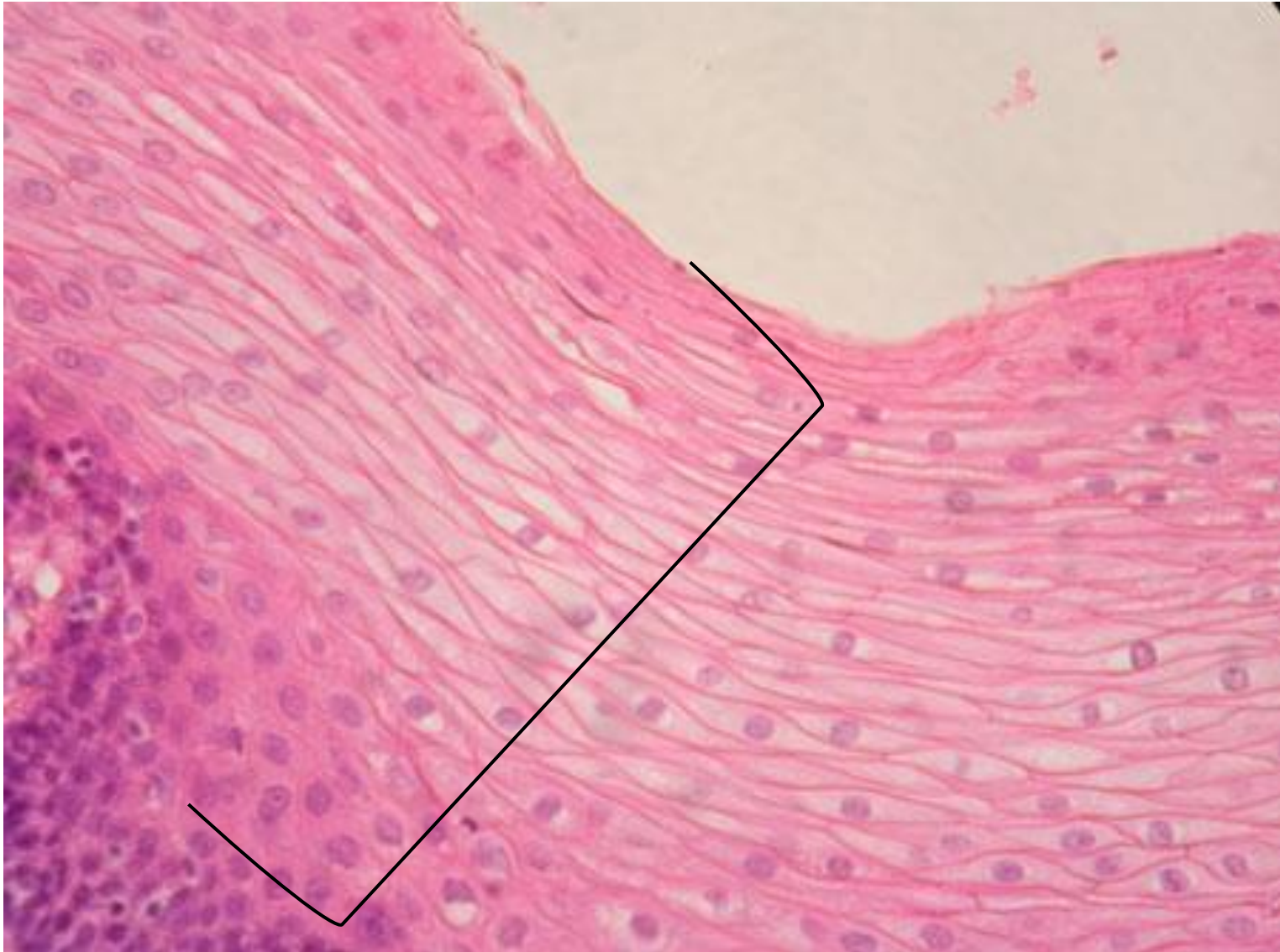
Location: Epidermis, oropharynx, anal canal



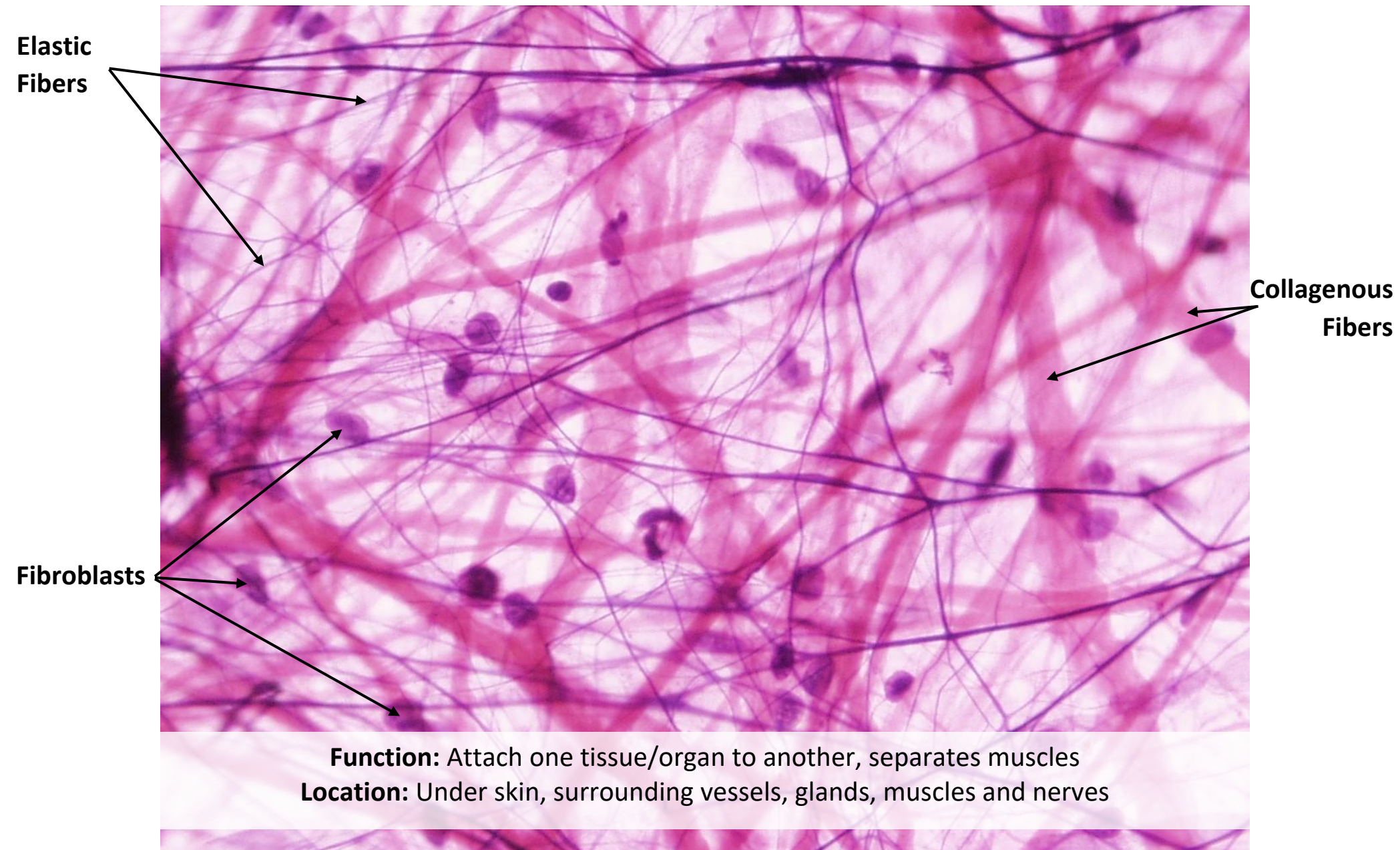
STRATIFIED SQUAMOUS EPITHELIUM

Function: _____

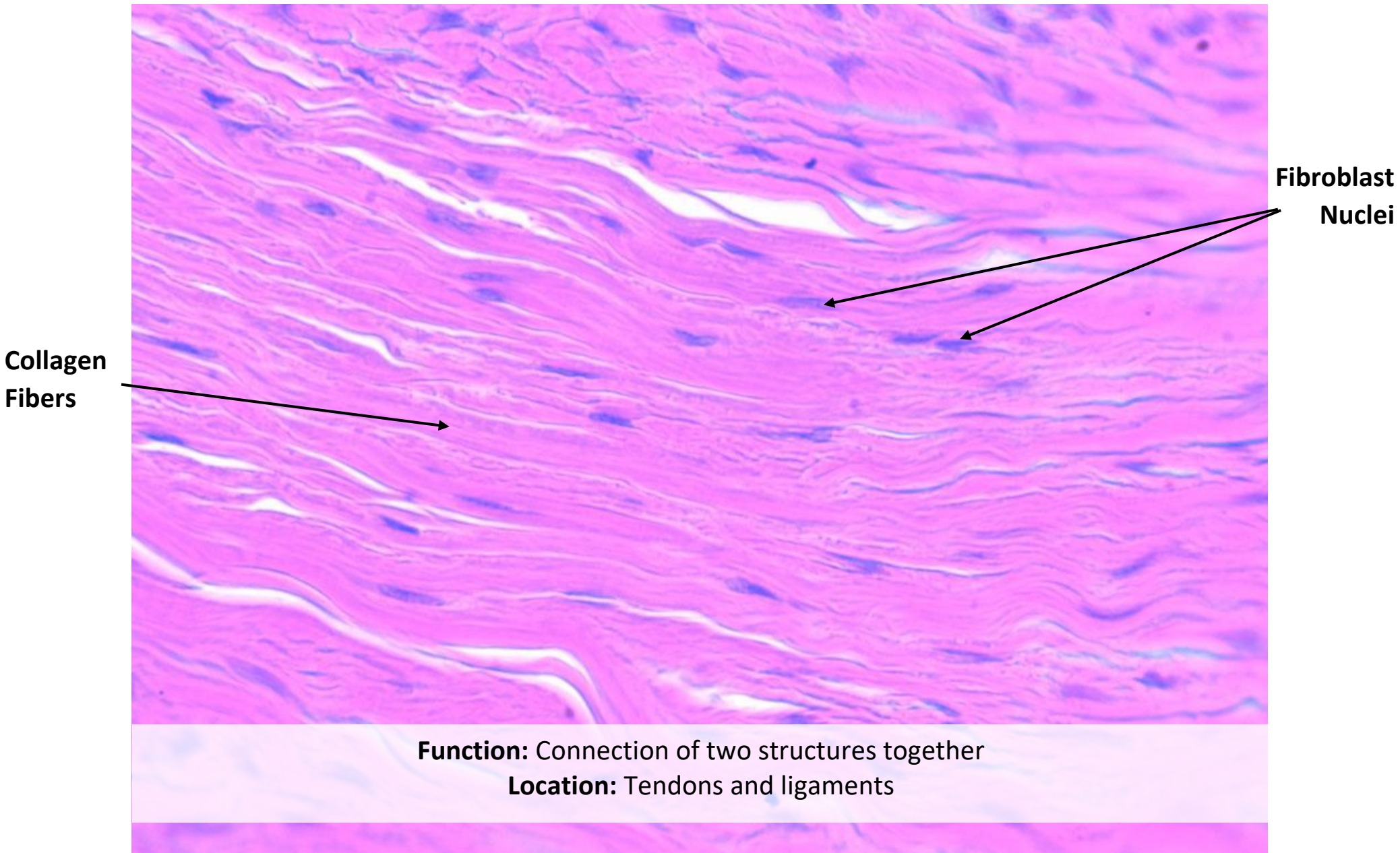
Location: _____



AREOLAR CONNECTIVE TISSUE



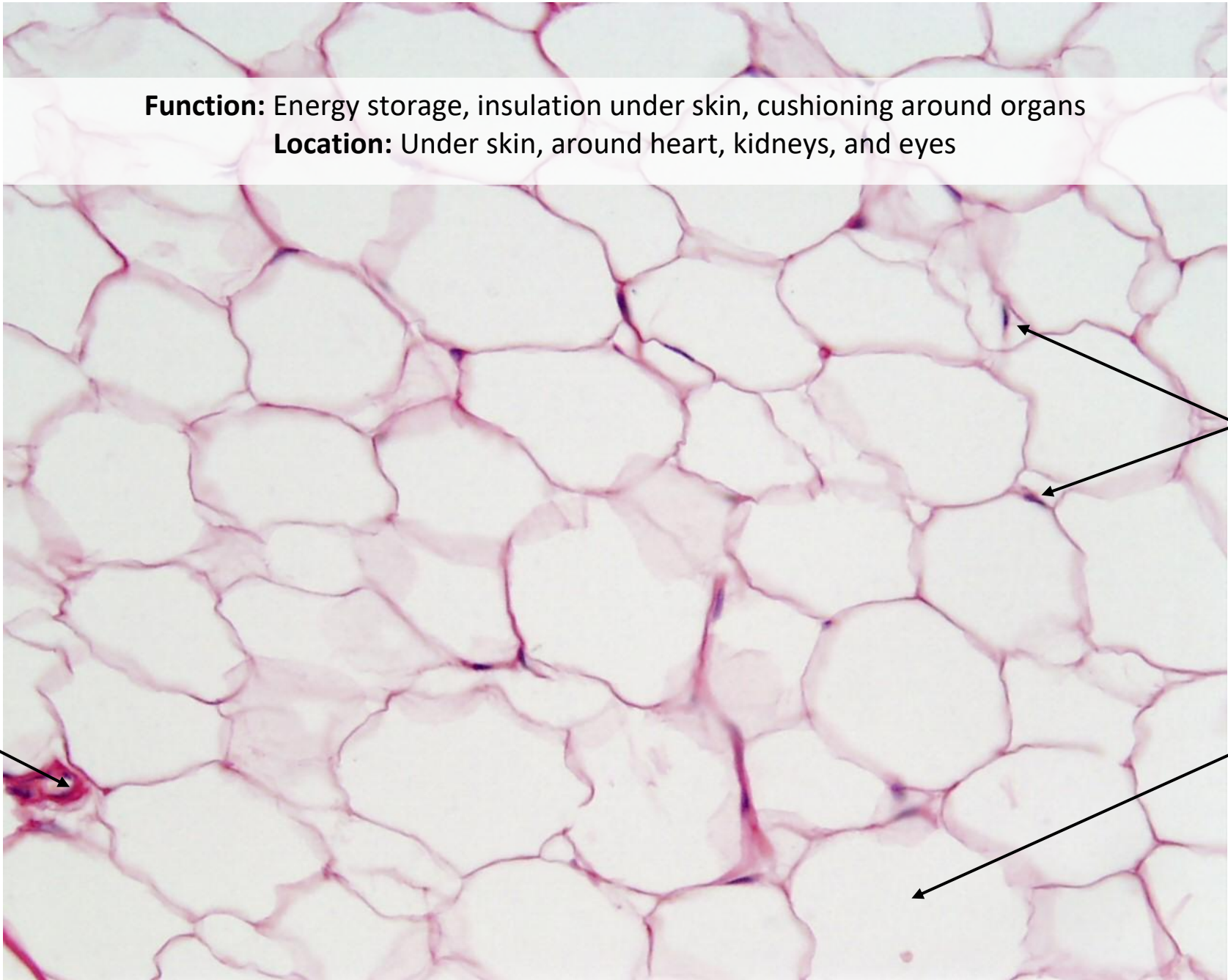
DENSE REGULAR CONNECTIVE TISSUE



ADIPOSE TISSUE

Function: Energy storage, insulation under skin, cushioning around organs

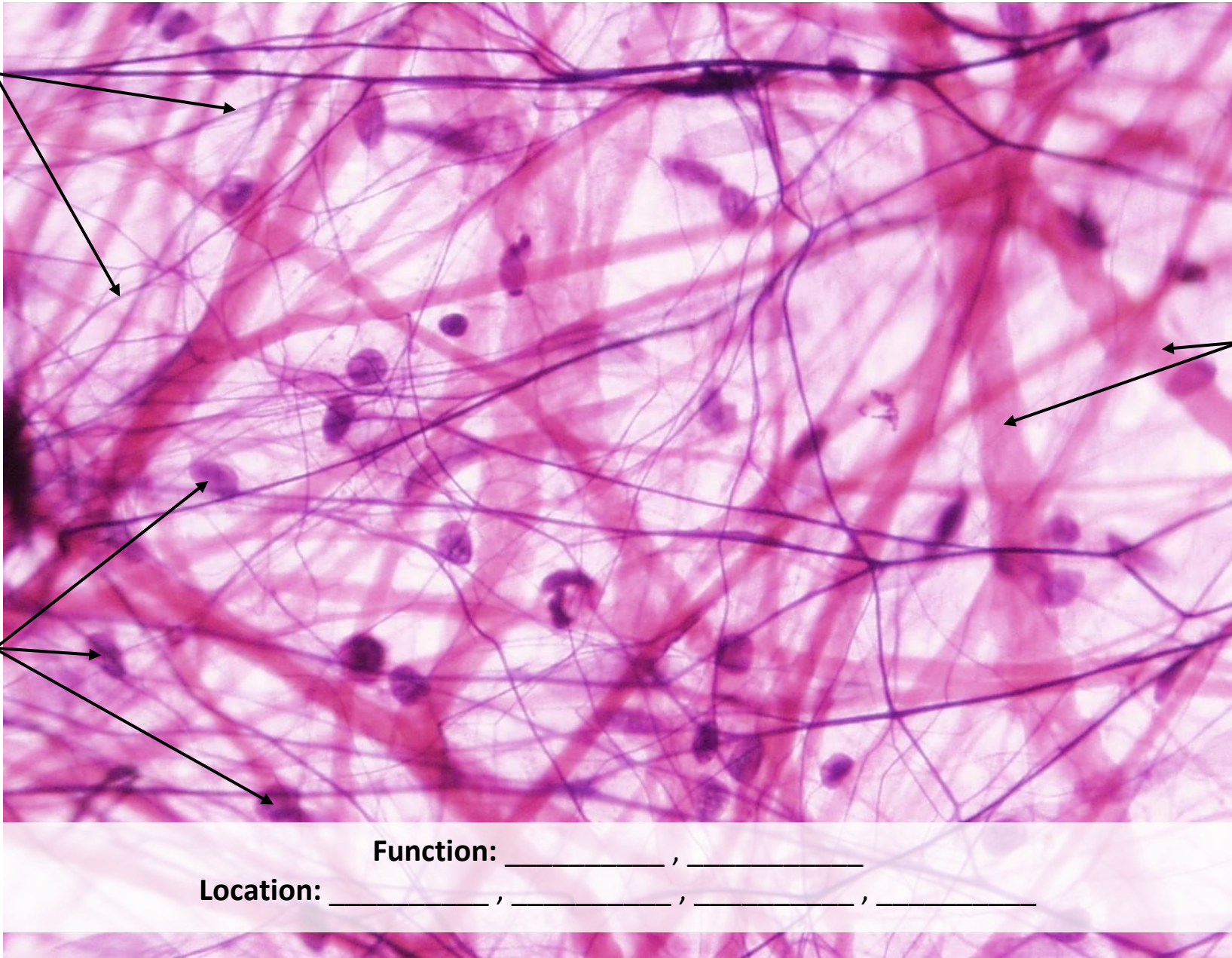Location: Under skin, around heart, kidneys, and eyes



Adipocyte
Nucleus

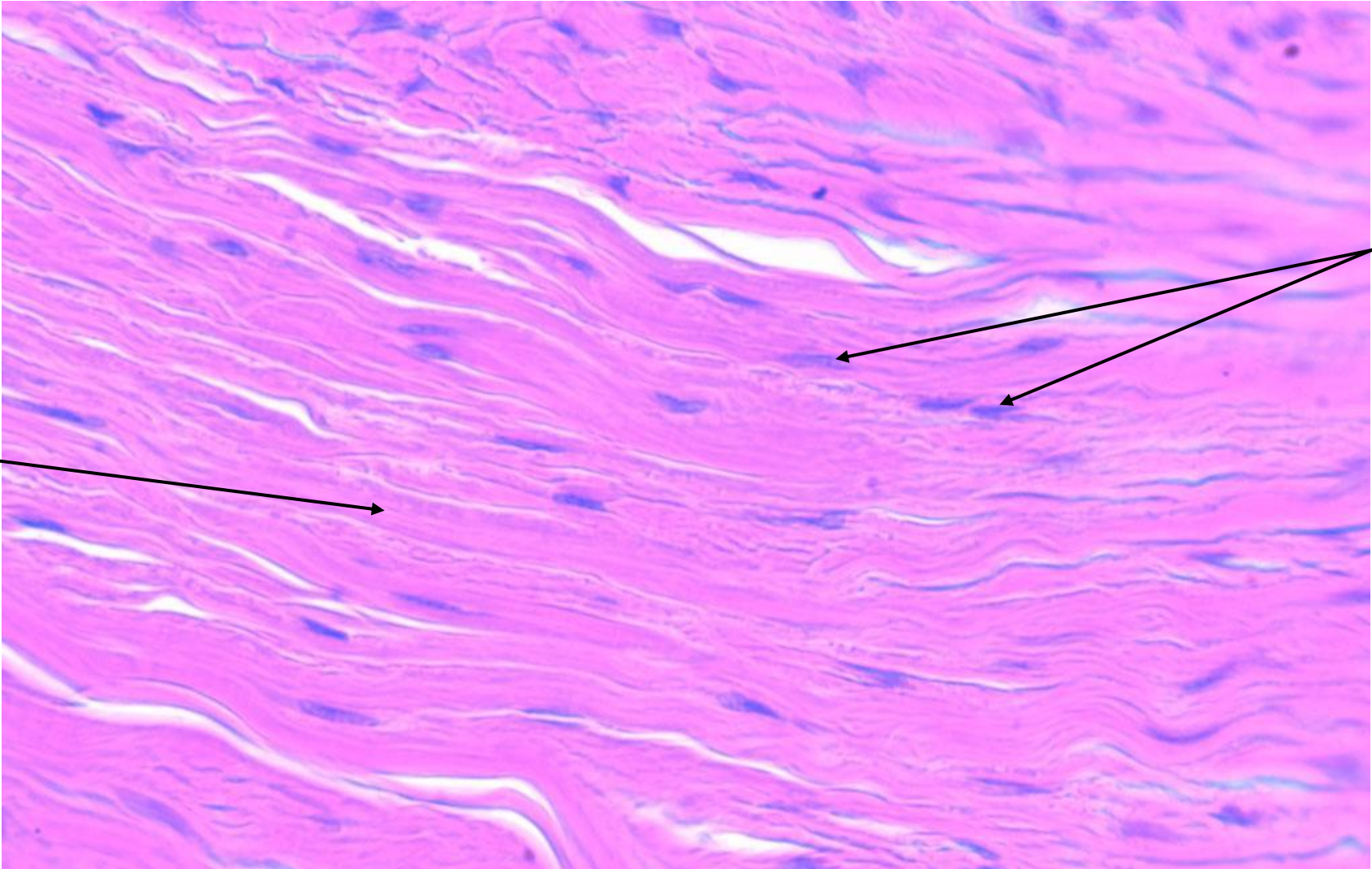
Lipid
within
Adipocyte

Blood
Vessel



Function: _____ , _____

Location: _____ , _____ , _____ , _____



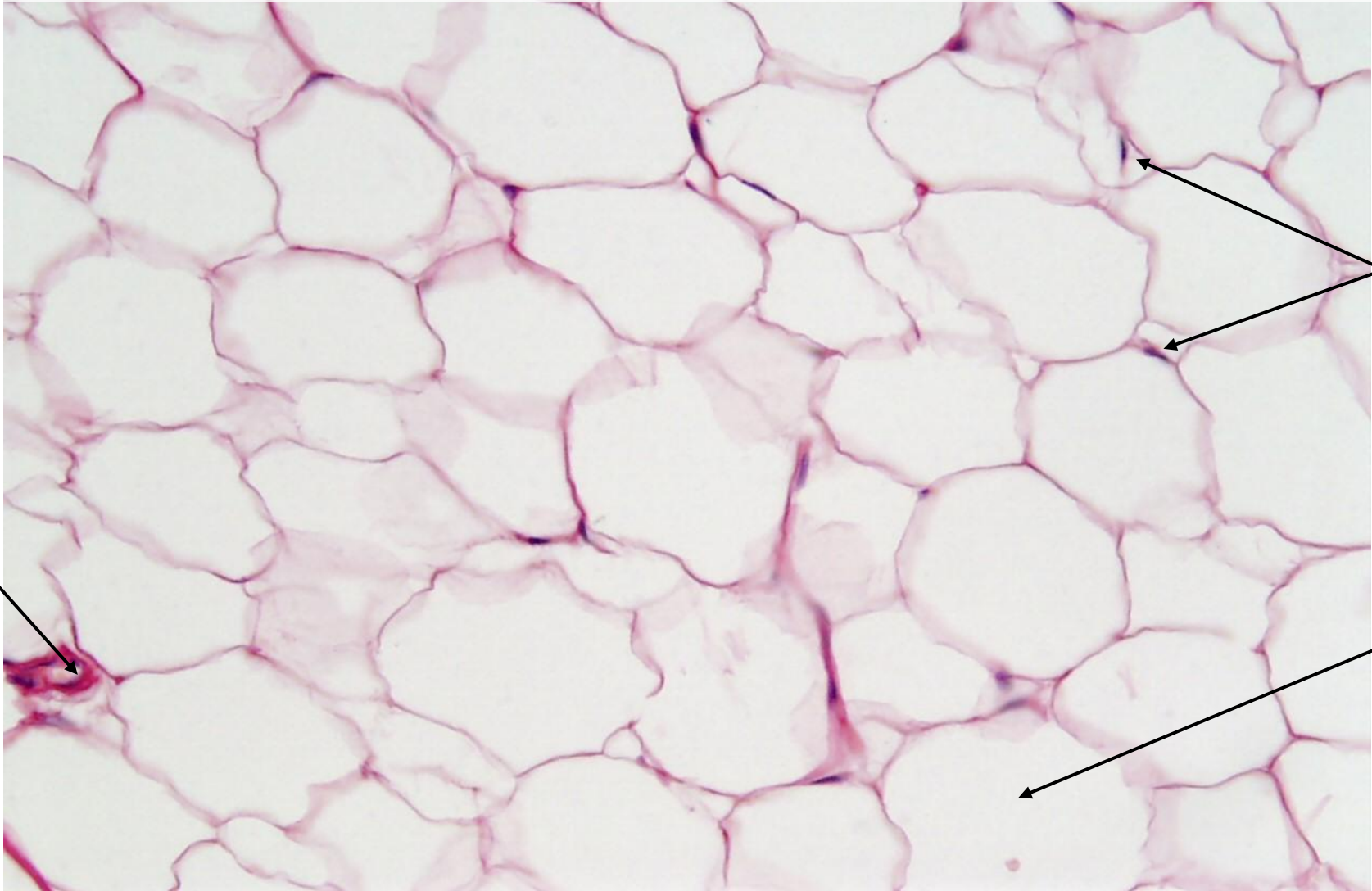
Function: _____

Location: _____ , _____

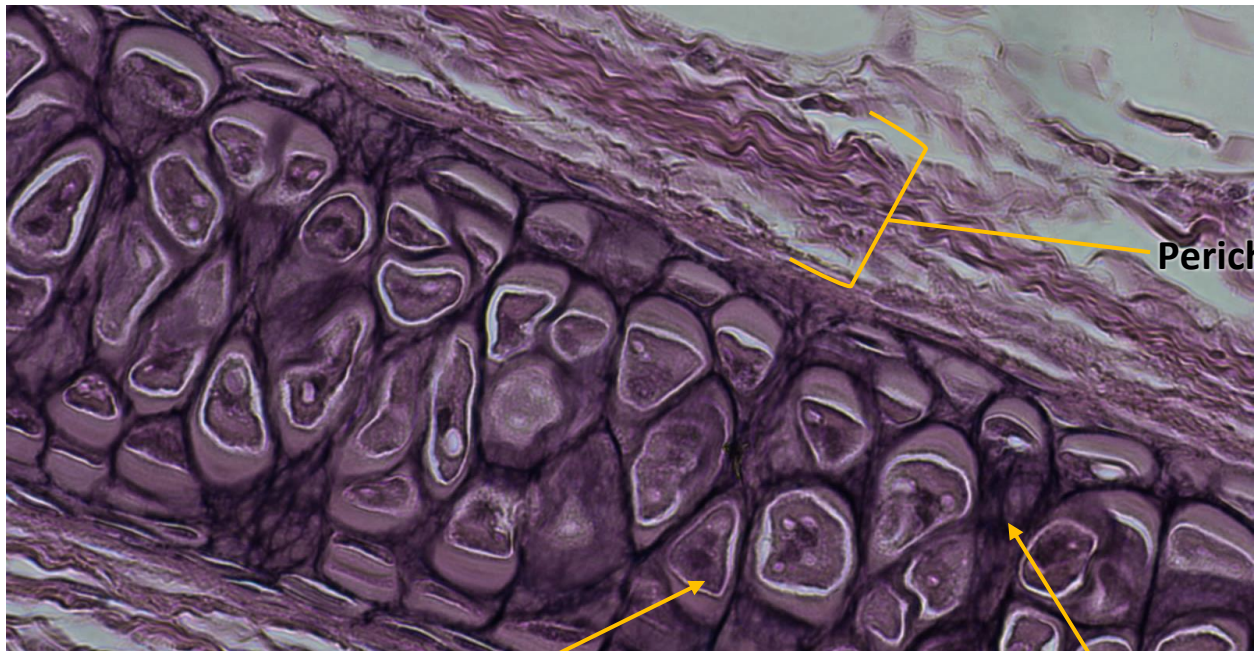

Function: _____ , _____ , _____

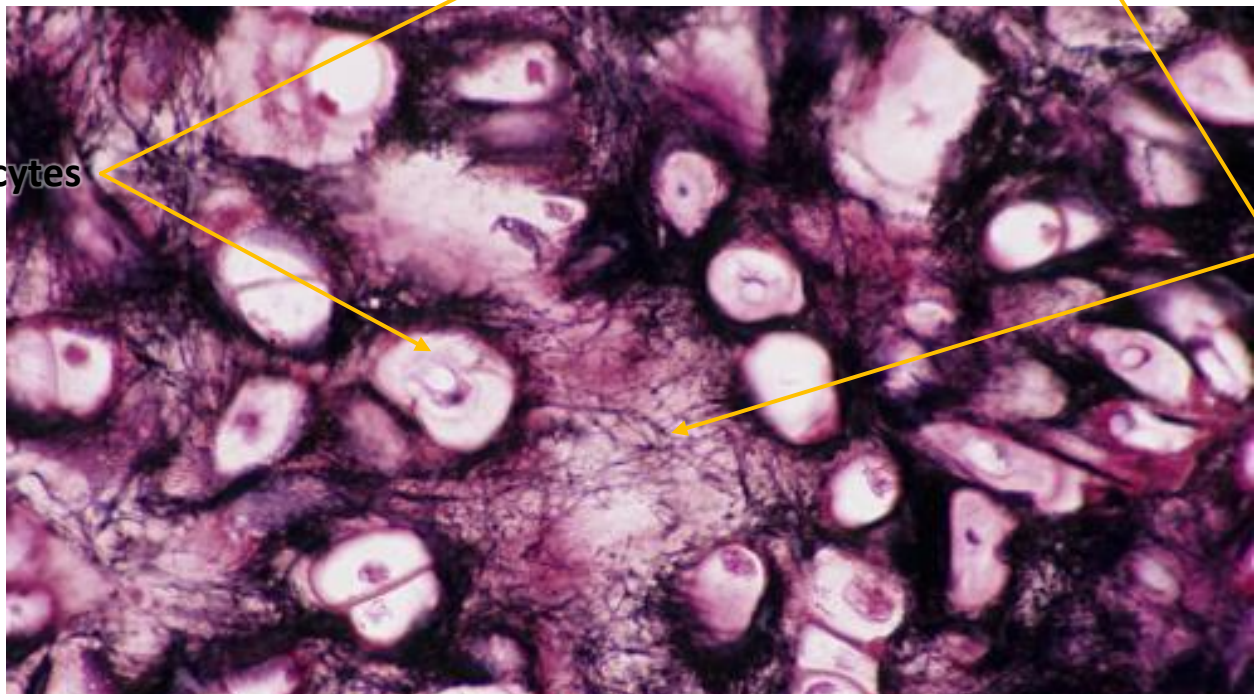
Location: _____ , _____ , _____ , _____



ELASTIC CARTILAGE



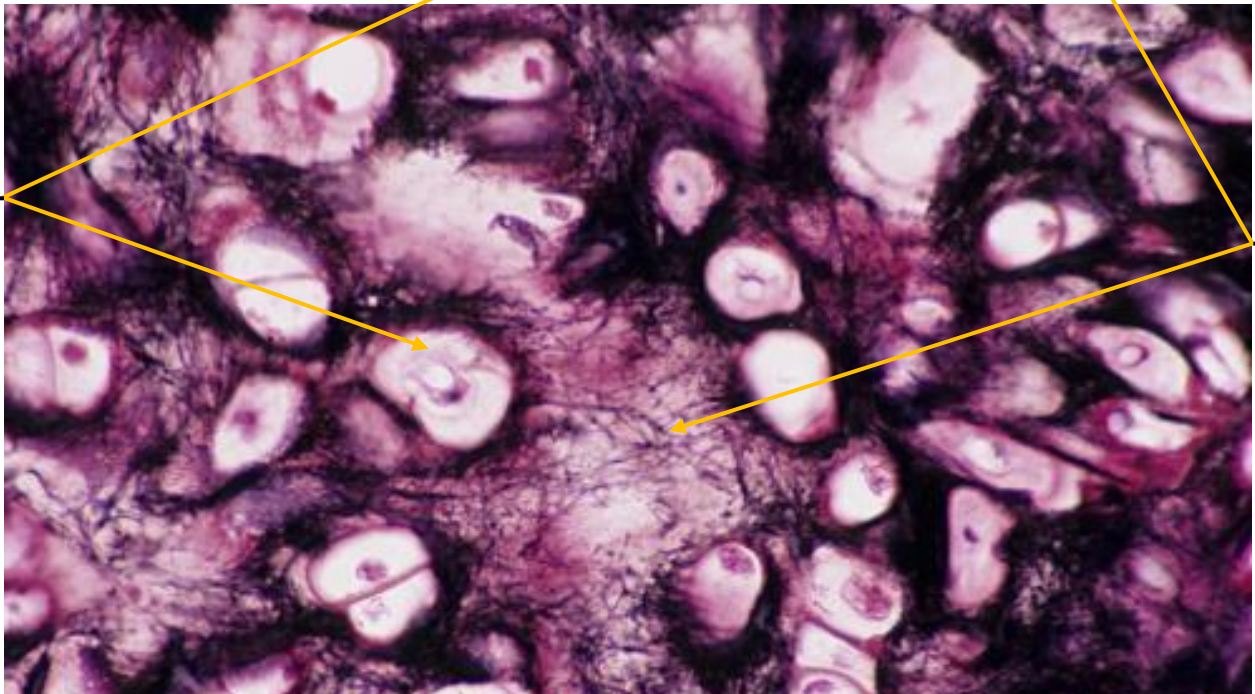
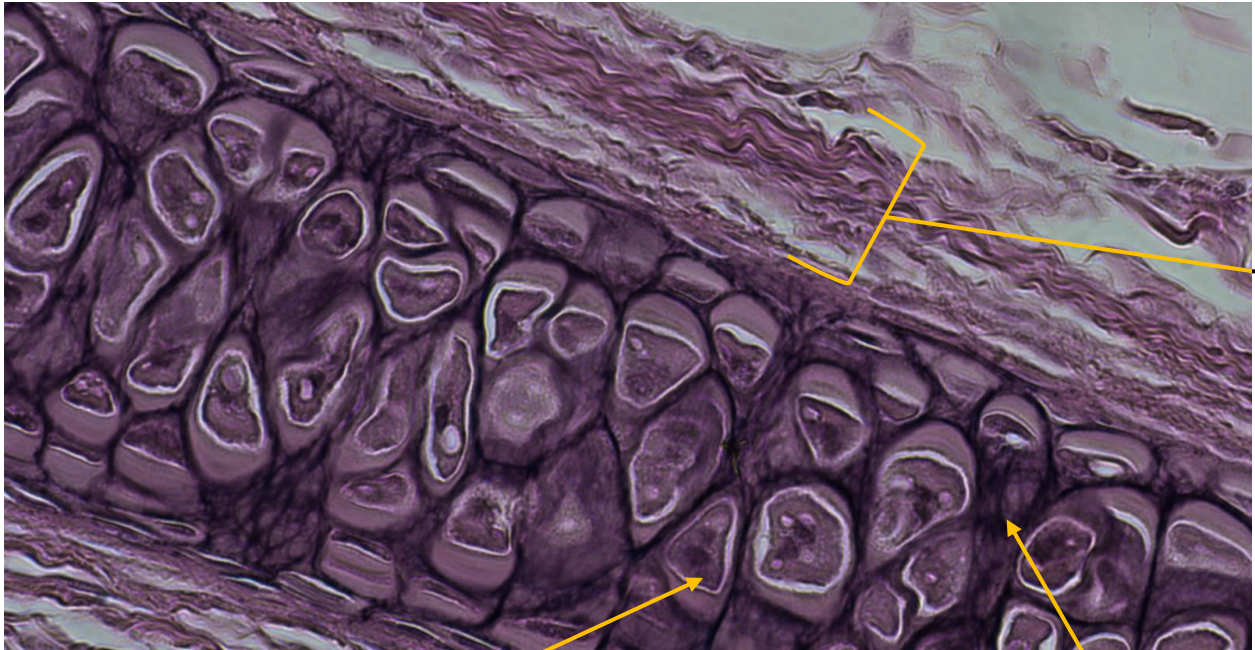Perichondrium



Elastic
Fibers

Lacunae
With
Chondrocytes

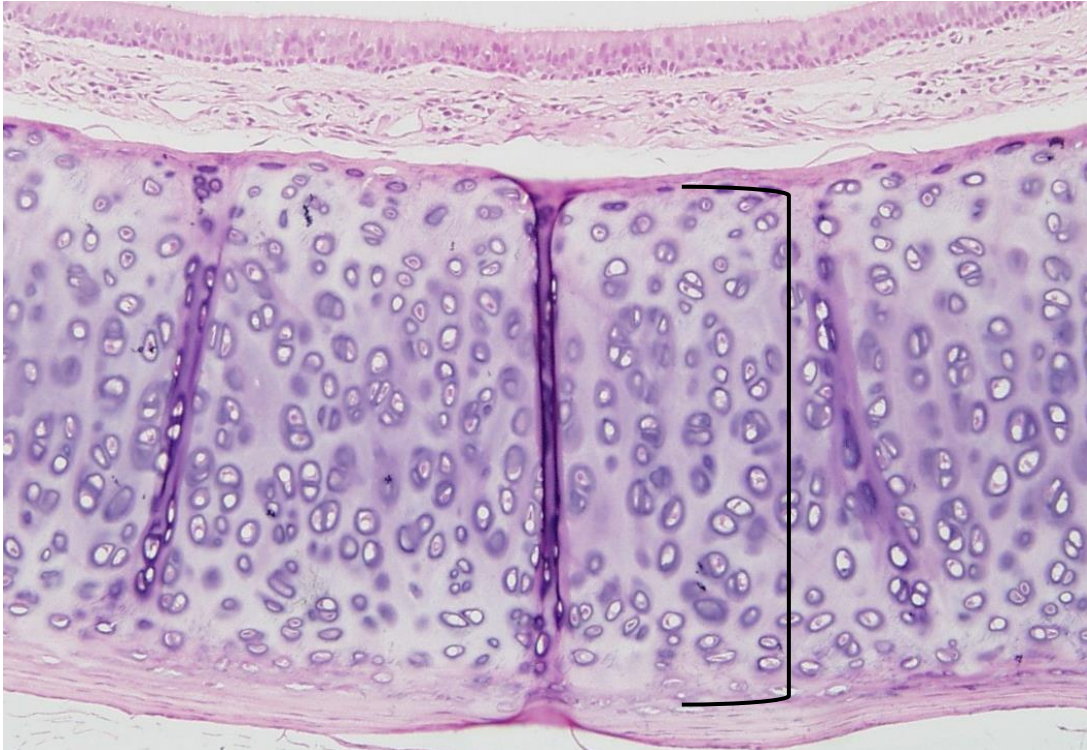
Function: Provide flexible support
Location: Outer ear, epiglottis, larynx



Function: _____

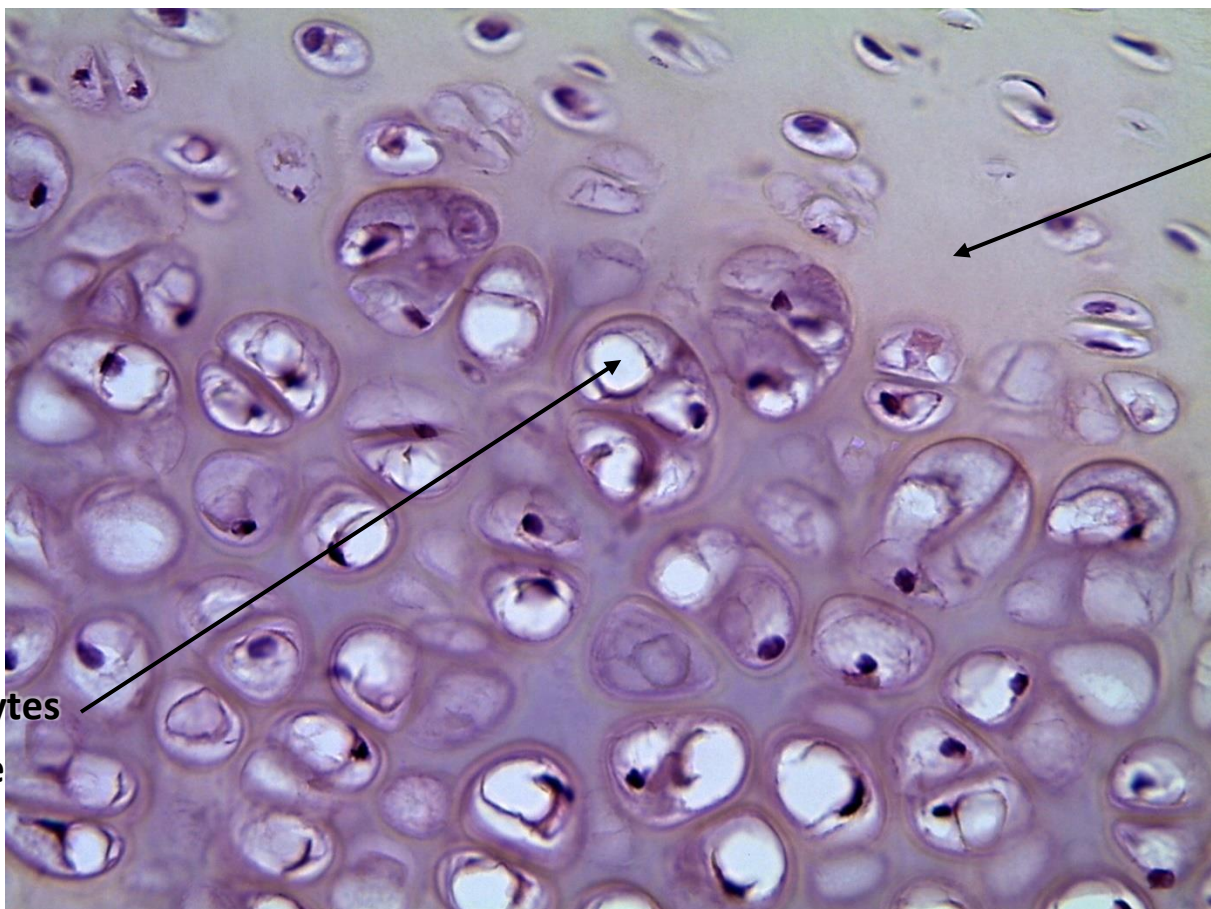
Location: _____ , _____ , _____

HYALINE CARTILAGE



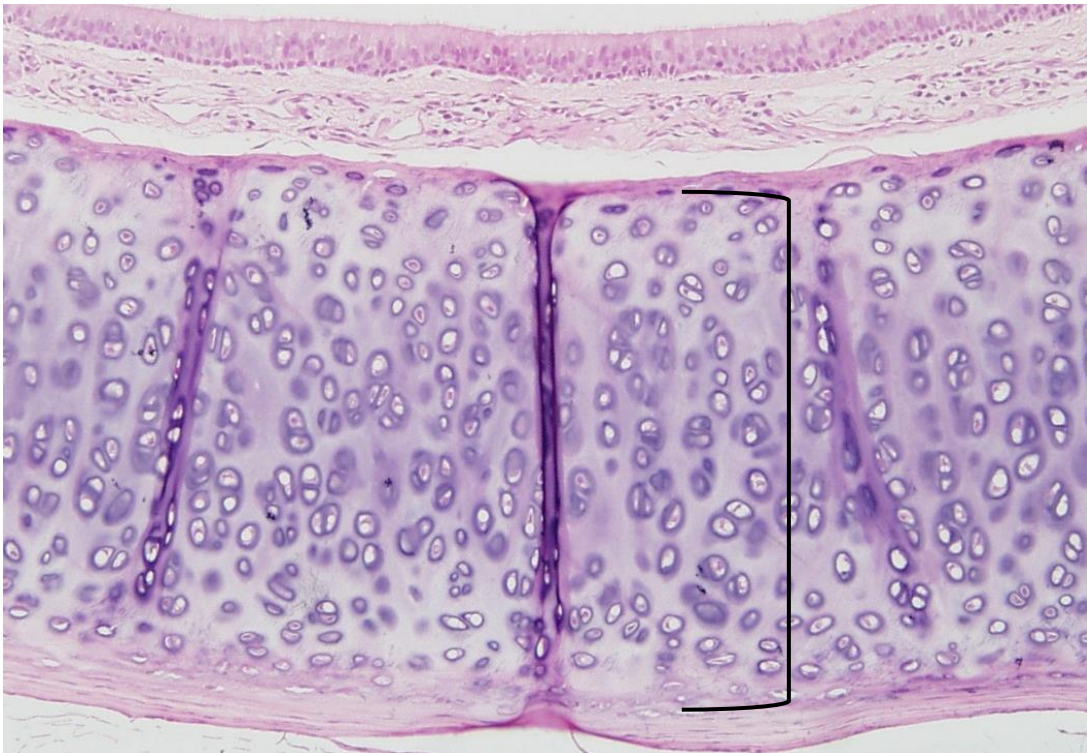
Function: Support

Location: Costal cartilage, end of nose



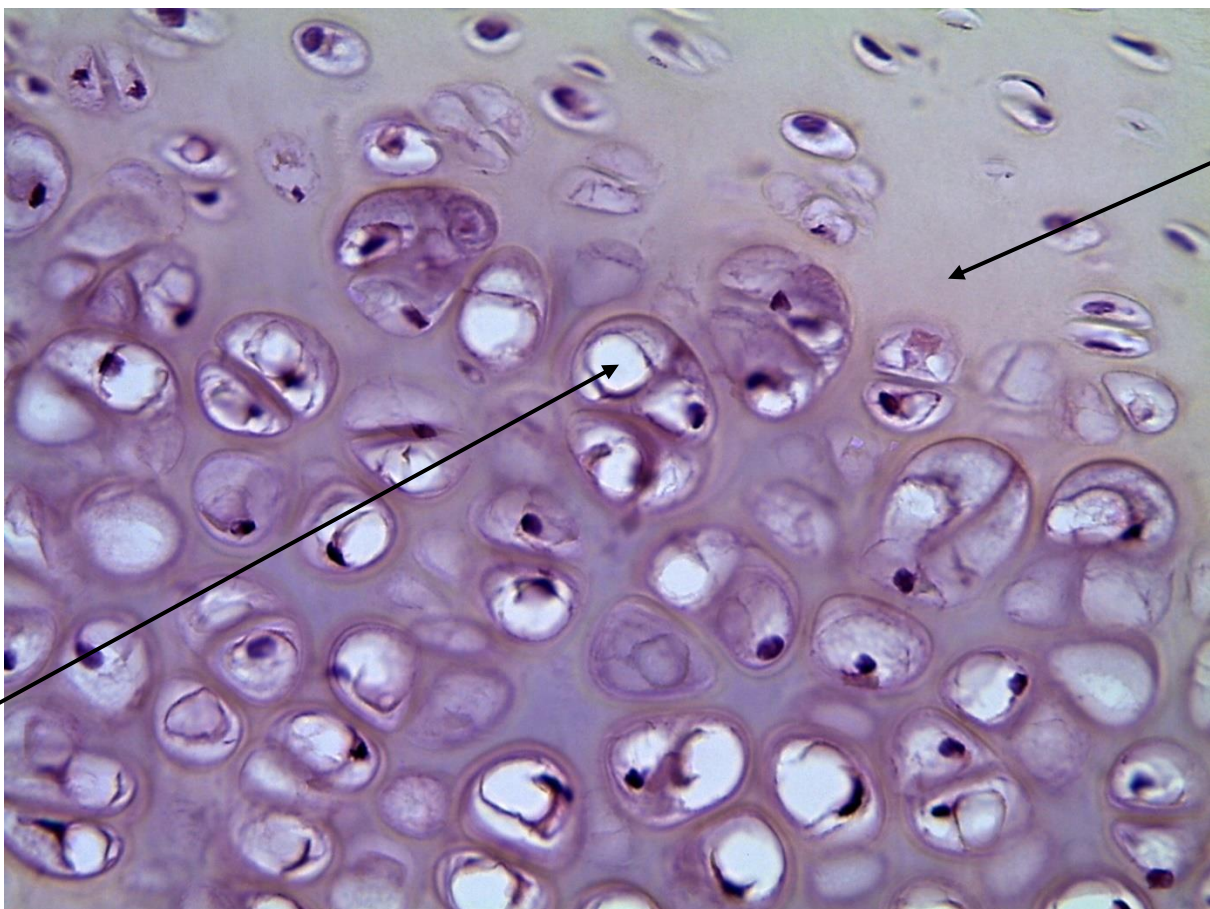
Matrix

**Chondrocytes
in Lacunae**



Function: _____

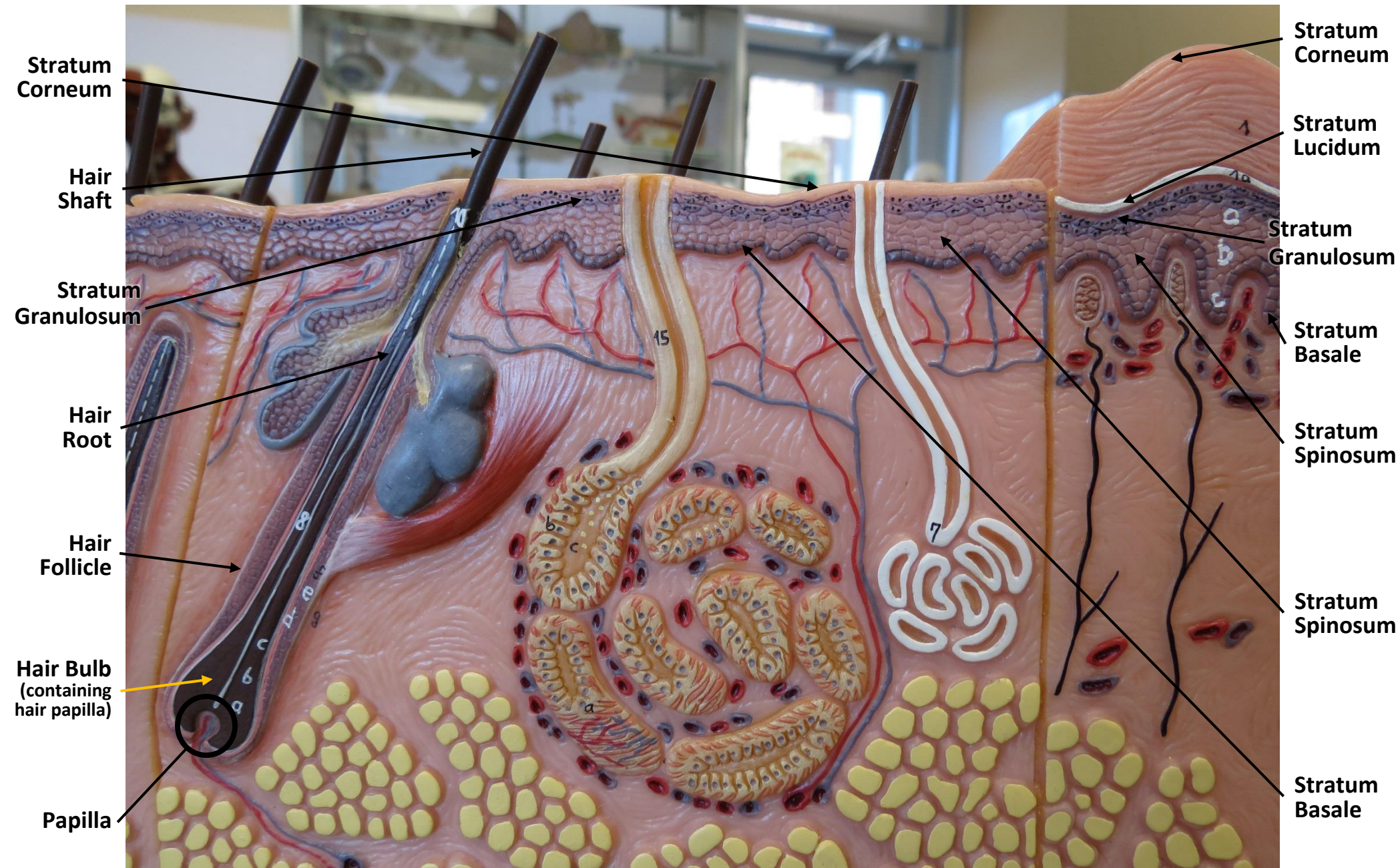
Location: _____



SKIN MODEL



SKIN MODEL



The image shows a detailed anatomical model of human skin and underlying structures, divided into three sections labeled A, B, and C. Each section shows a cross-section of the skin, revealing various layers and internal organs. Section A shows the head and neck area, with labels for the brain, eyes, nose, mouth, and throat. Section B shows the arm and hand area, with labels for the shoulder, elbow, wrist, and hand. Section C shows the torso and abdominal area, with labels for the stomach, intestines, and other organs. The model is made of plastic and includes a small anatomical figure in the background. Arrows point to specific structures in each section, and a yellow arrow points to a structure in section C.

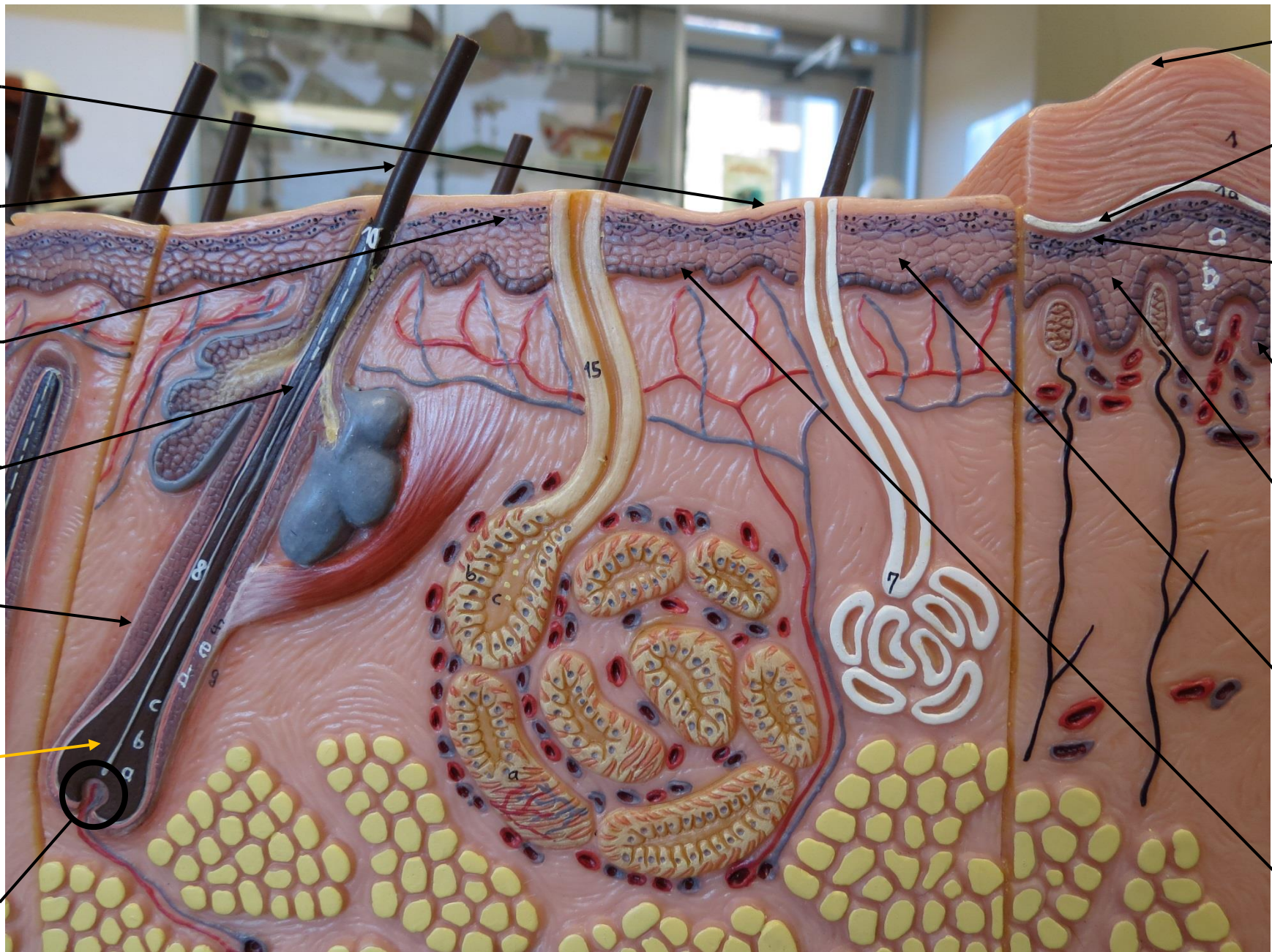
A. Die behaarte Kopfhaut
The hairy scalp
Peau chevelue du crâne
El cuero cabelludo

B. Die Haut der Achselhöhle
The skin of the arm-pit
Peau de l'aisselle
La piel de la cavidad axilar

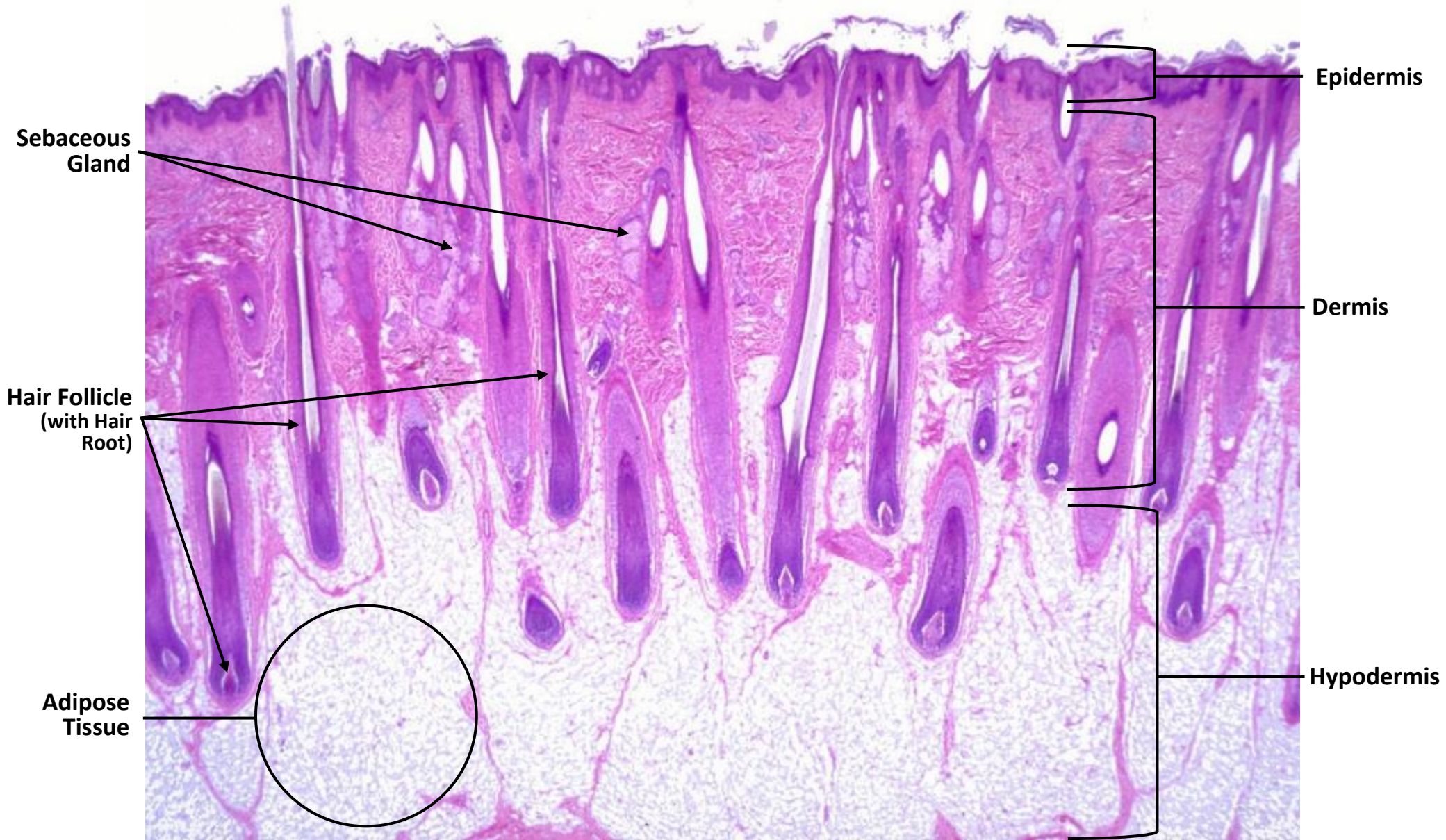
C. Die unbehairte Haut des Unterbauchs
The hairless skin of the lower part of the trunk
Ventre sans poil de la phase du sexe
La piel sin vello de la parte del que

© REMED-Modèle de peau anthropométrique par l'Institut. © Tous droits réservés pour tous les modèles REMED. © REMED modèle are copyrighted. © Prohibida la reproducción por todos los modelos REMED.

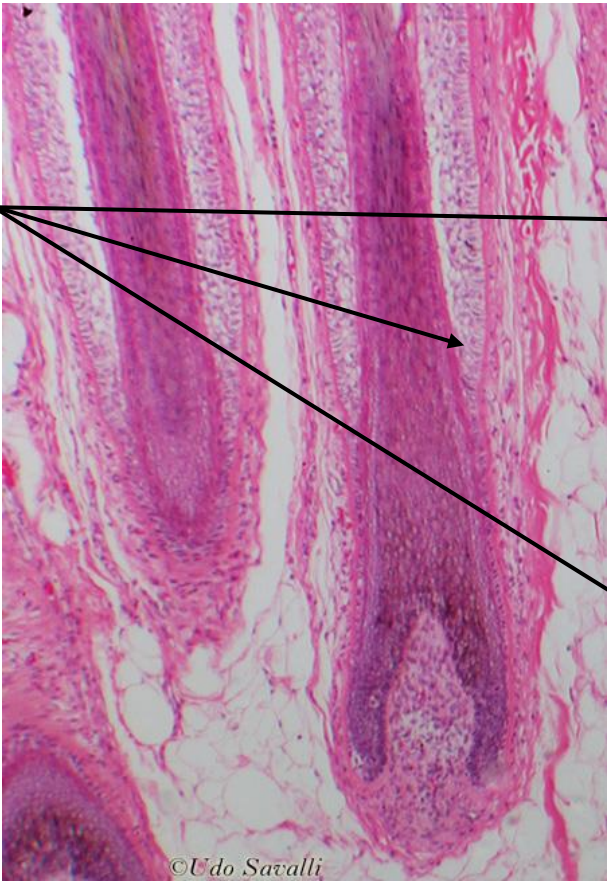
SKIN MODEL



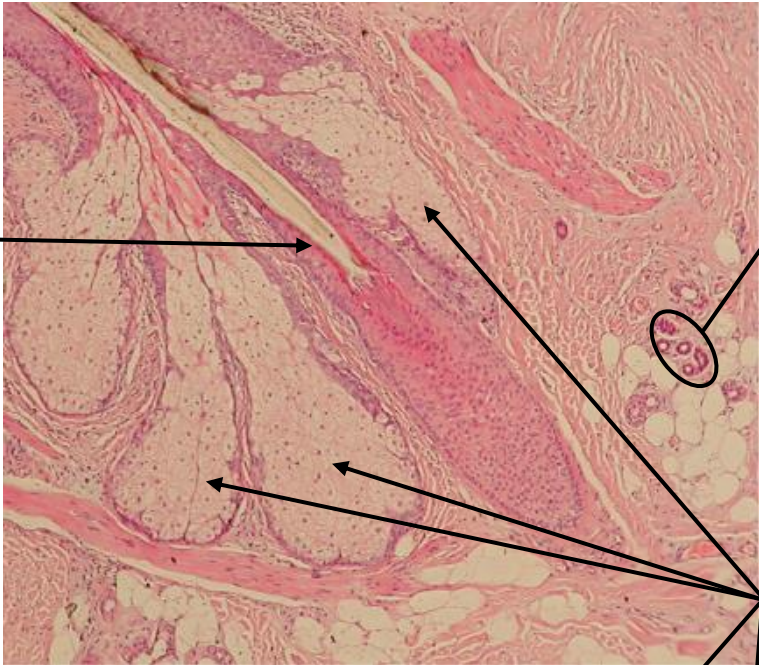
SKIN SLIDES



SKIN SLIDES

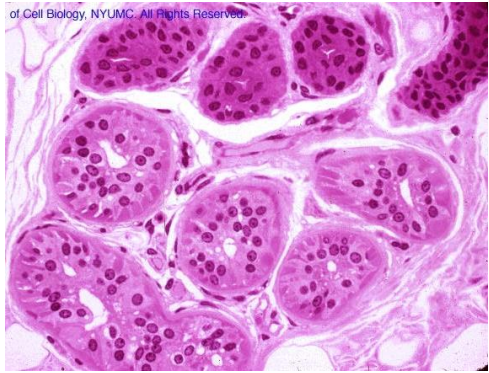


Hair Follicle
(with Hair Root)

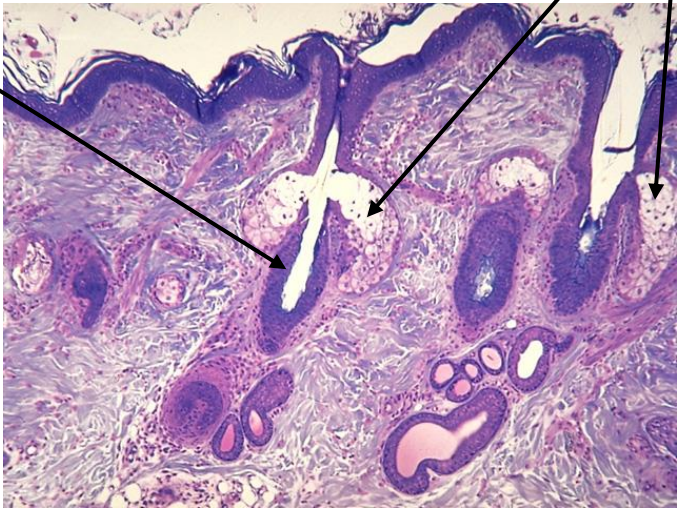


Sweat
Glands

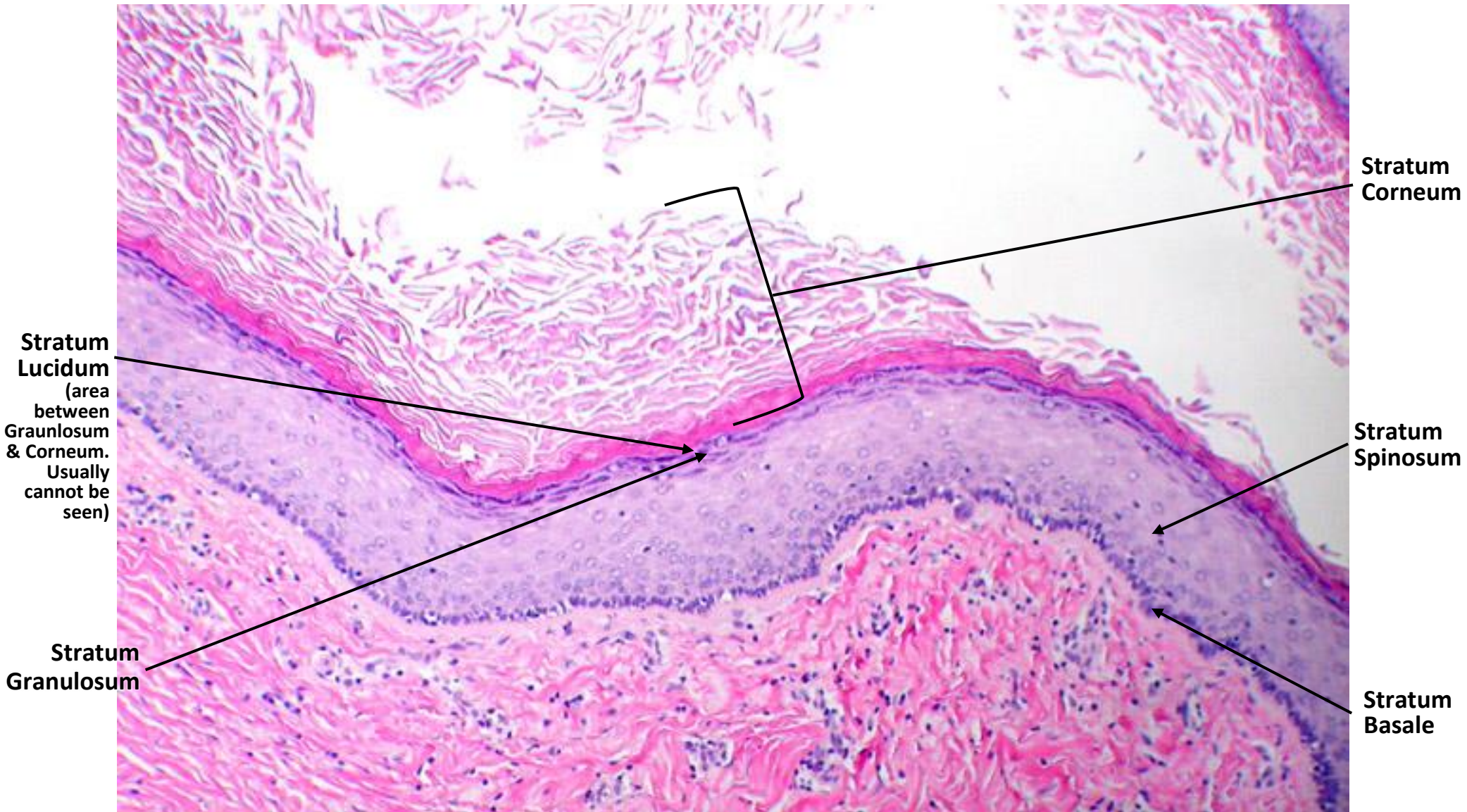
Sebaceous
Gland



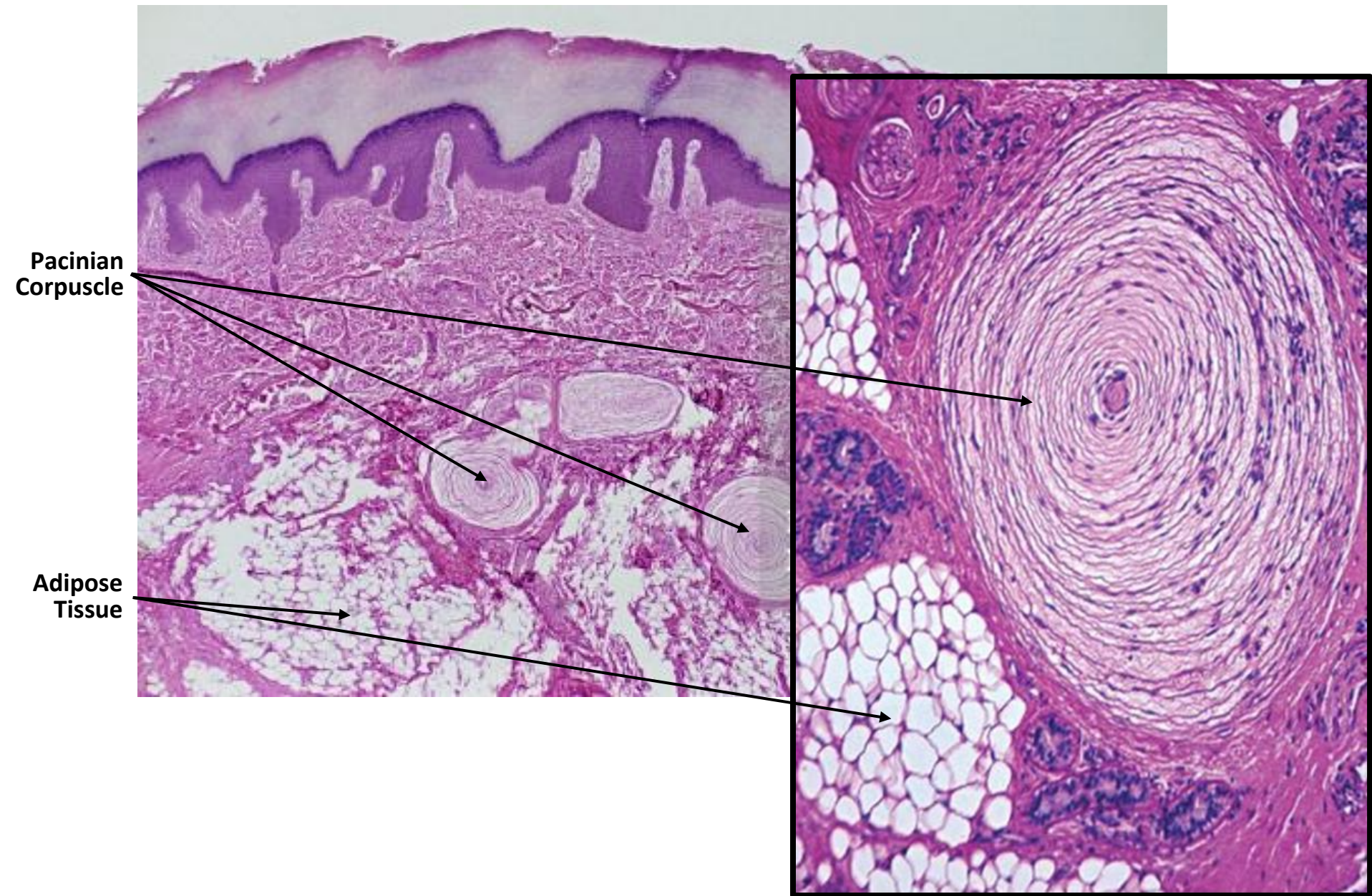
Sweat
Glands



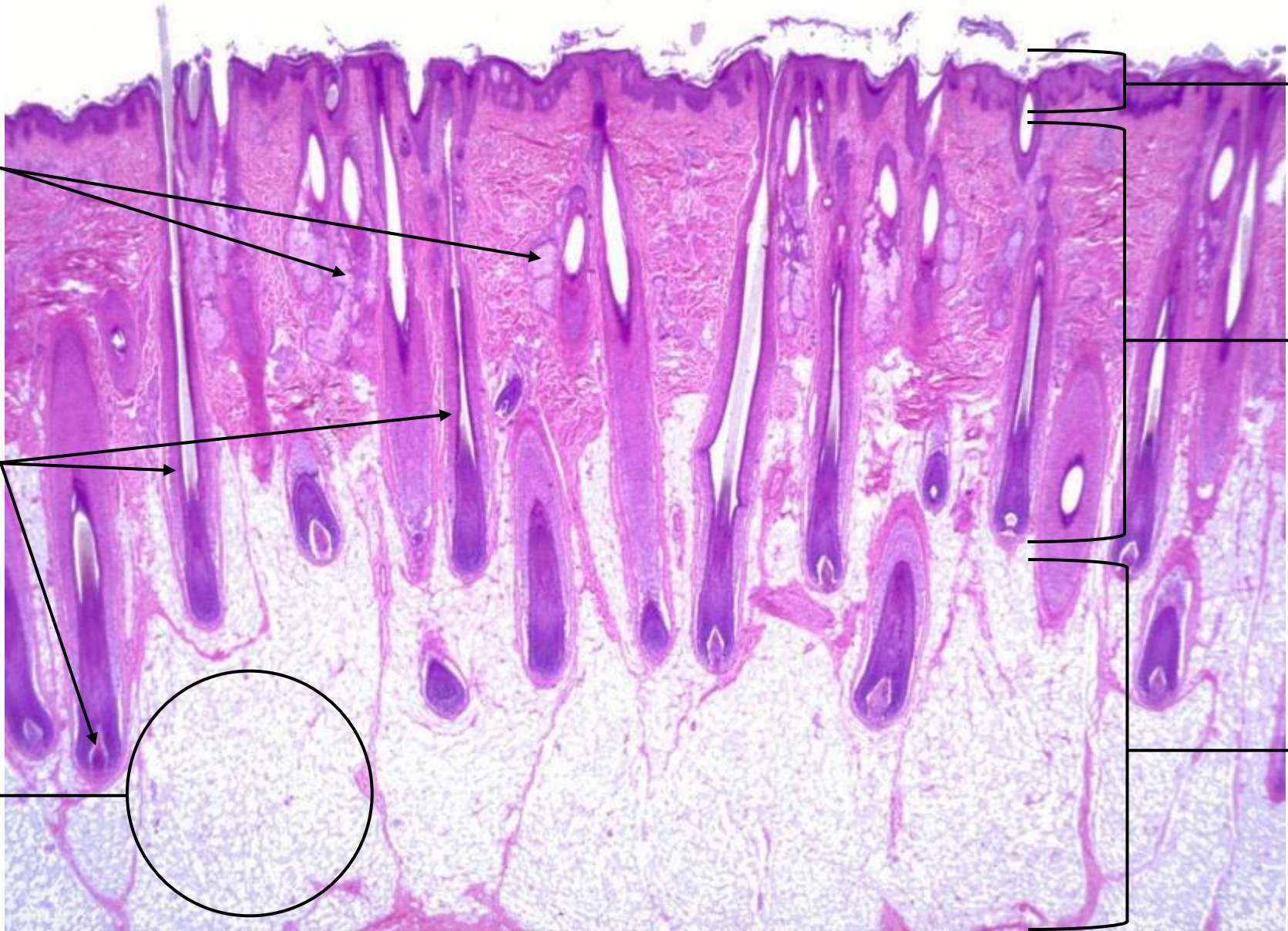
SKIN SLIDES



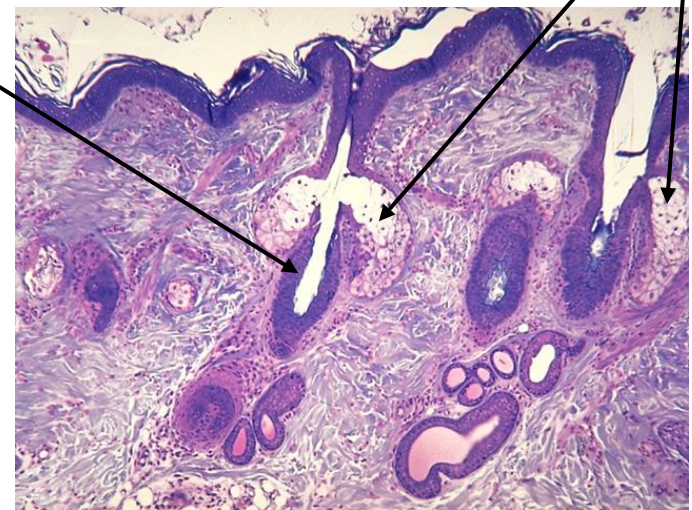
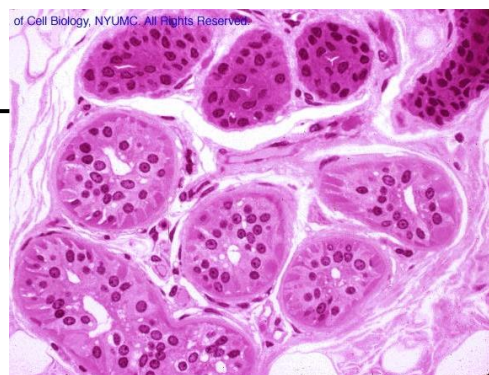
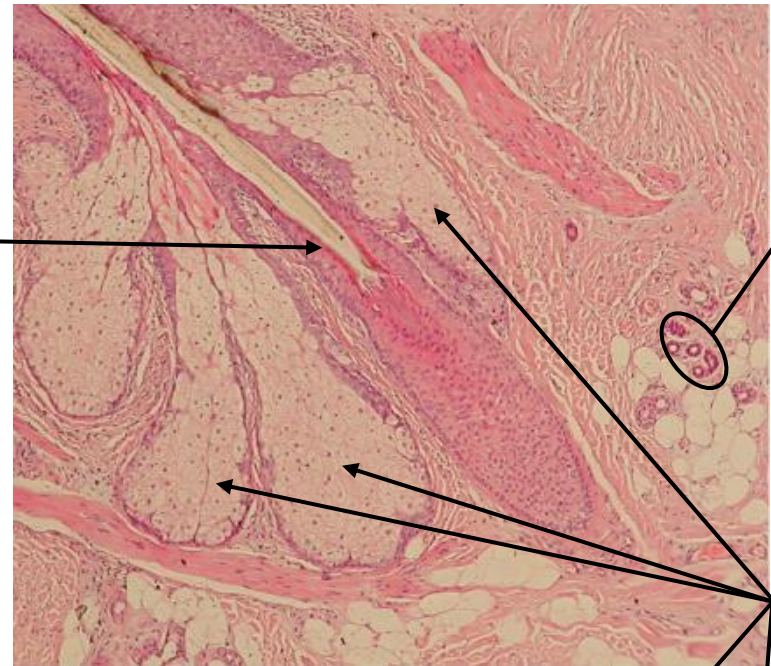
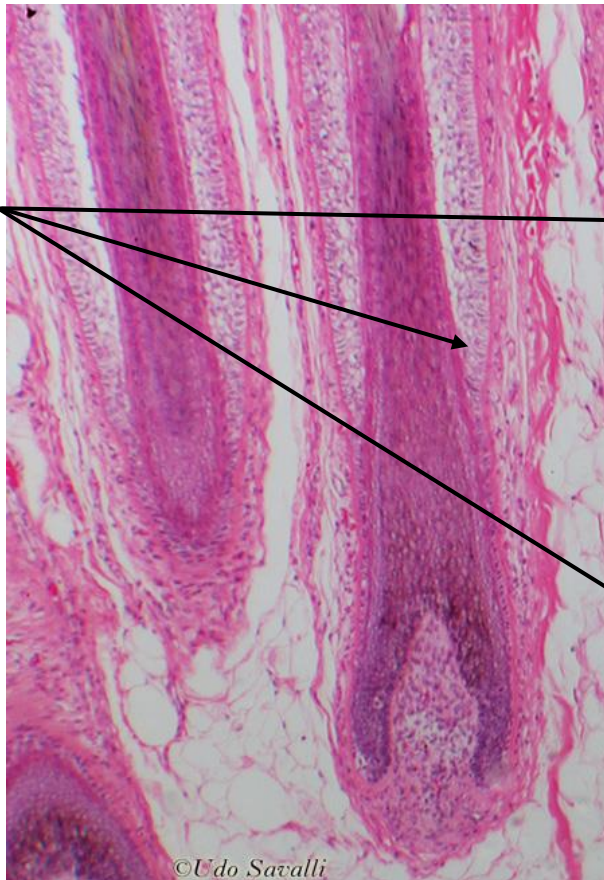
SKIN SLIDES



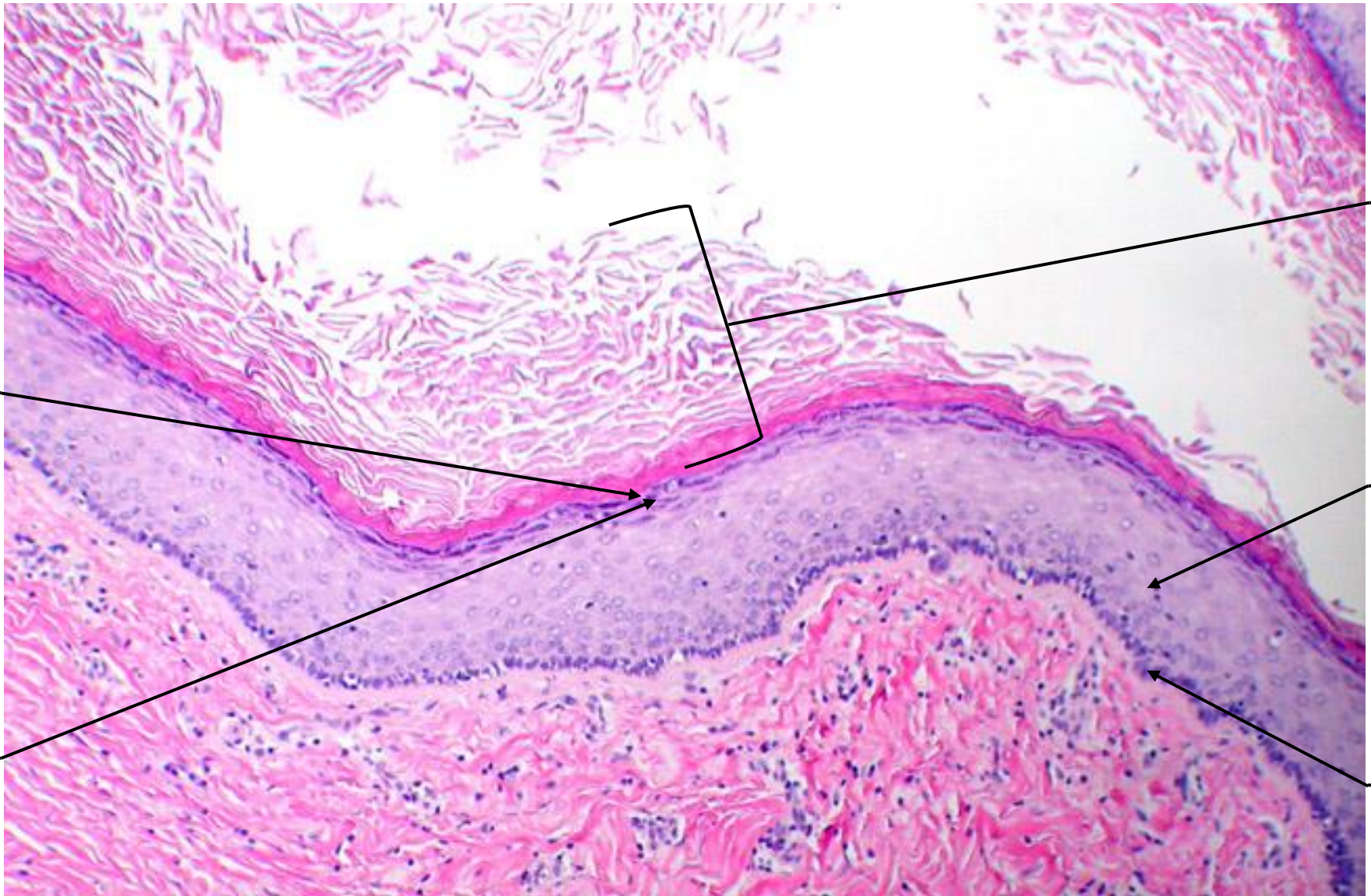
SKIN SLIDES



SKIN SLIDES



SKIN SLIDES



SKIN SLIDES

