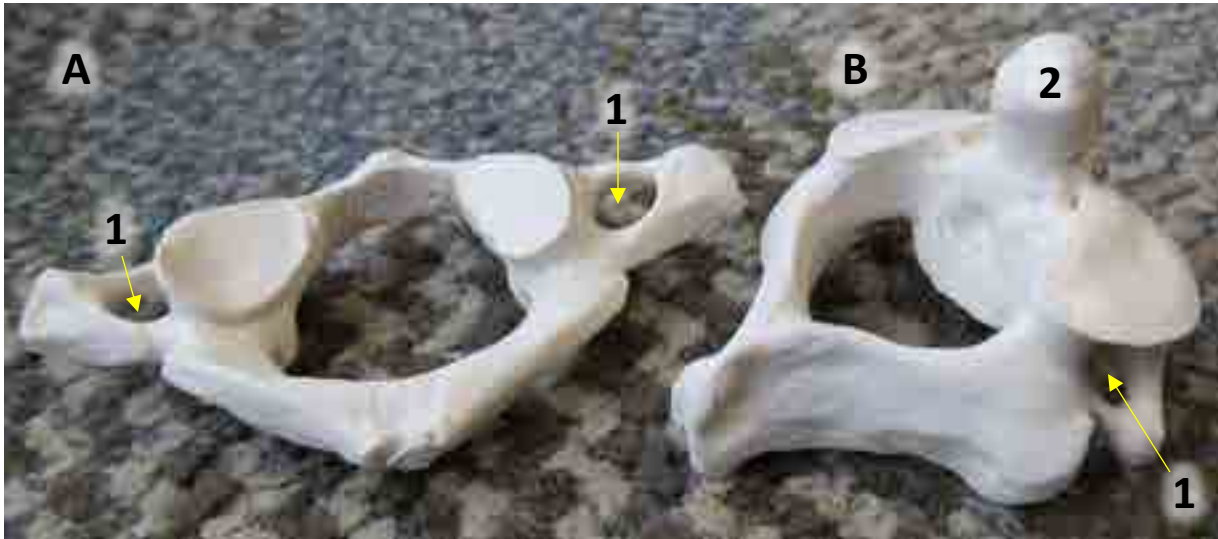


## CERVICAL VERTEBRAE

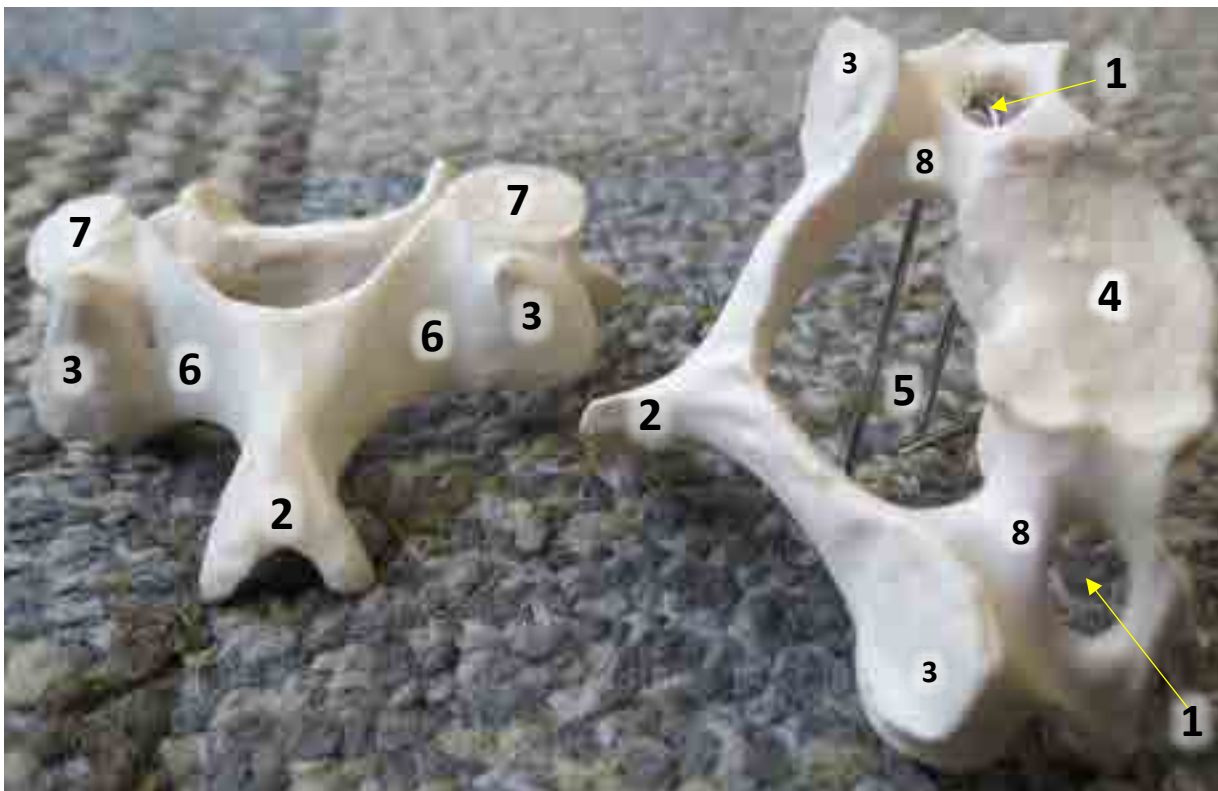

### A. Atlas

1. Transverse Foramen


### B. Axis

1. Transverse Foramen
2. Dens



1. Transverse Foramen
2. Spinous Process
3. Transverse Process
4. Body
5. Vertebral Foramen
6. Lamina
7. Superior Articular Process
8. Pedicle

## THORACIC VERTEBRAE



1. Pedicle
2. Spinous Process
3. Transverse Process
4. Body
5. Vertebral Foramen
6. Lamina
7. Superior Articular Process
8. Inferior Articular Process
9. Costal Demifacet (groove on transverse process)

\* Intervertebral Foramen shown on page labeled "Applies to all Vertebrae".

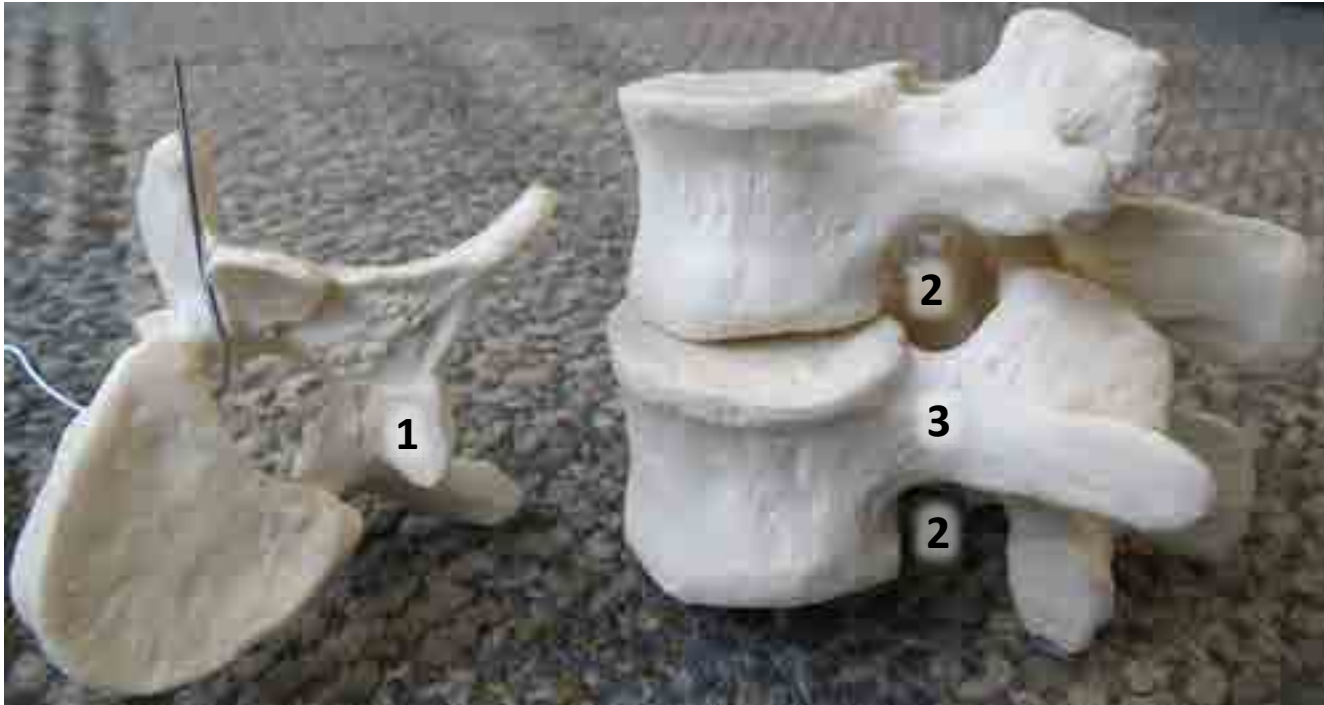## LUMBAR VERTEBRAE



1. Pedicle
2. Spinous Process
3. Transverse Process
4. Body
5. Vertebral Foramen
6. Lamina
7. Superior Articular Process
8. Inferior Articular Process

\* Intervertebral Foramen shown on page labeled "Applies to all Vertebrae".

## APPLIES TO ALL VERTEBRAE



### 1. Inferior Articular Process

- ❖ Located on the underside of the lamina

### 2. Intervertebral Foramen


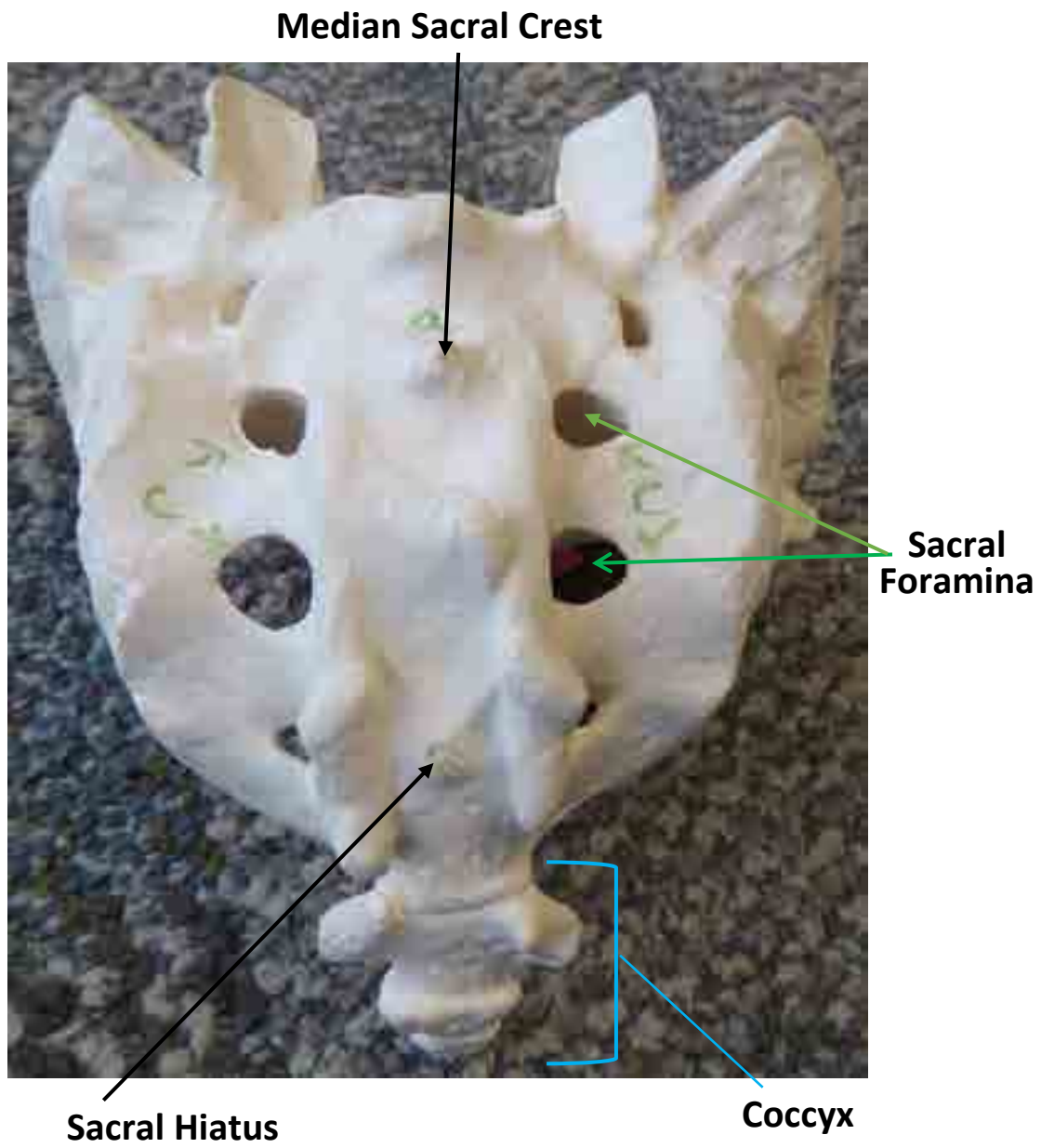
- ❖ Located between each vertebrae

### 3. Pedicle

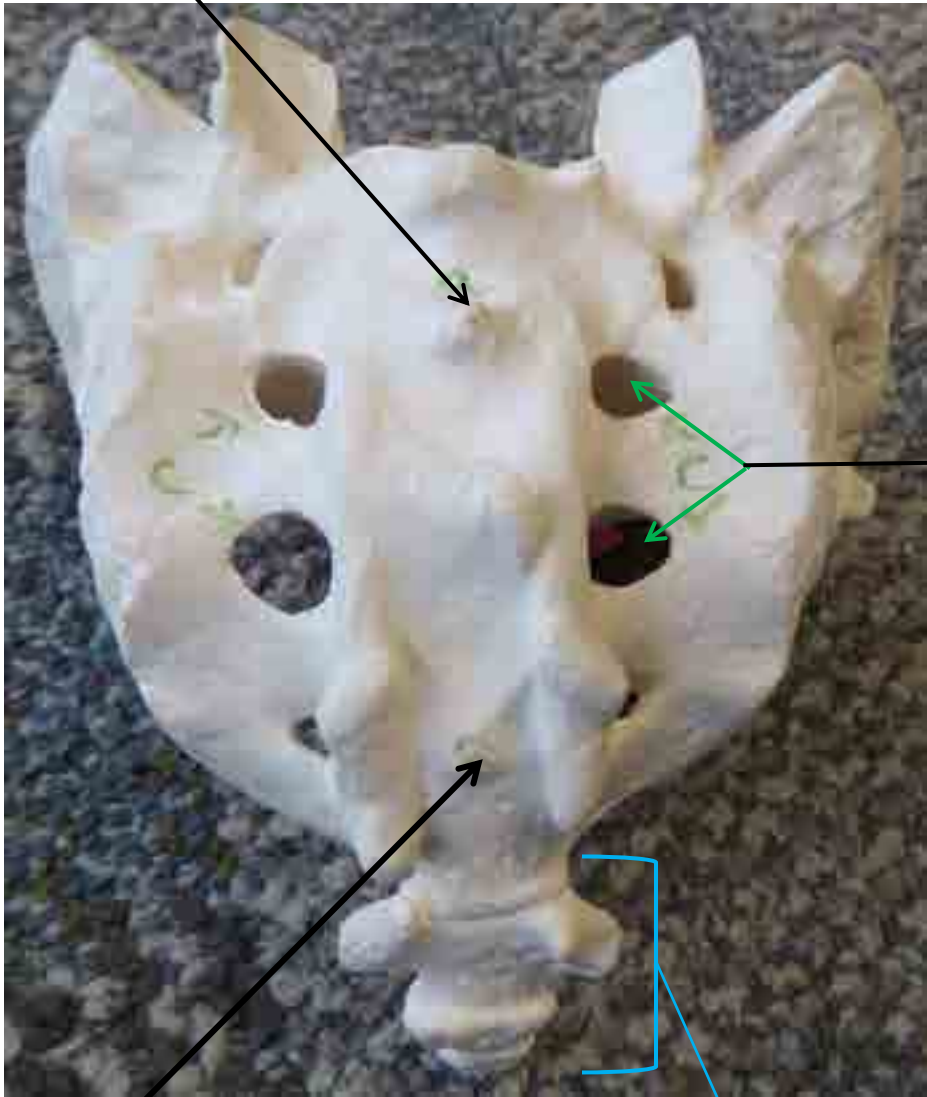
- ❖ Area between transverse process and body




# SACRUM BONE MODEL



\_\_\_\_\_



# STERNUM







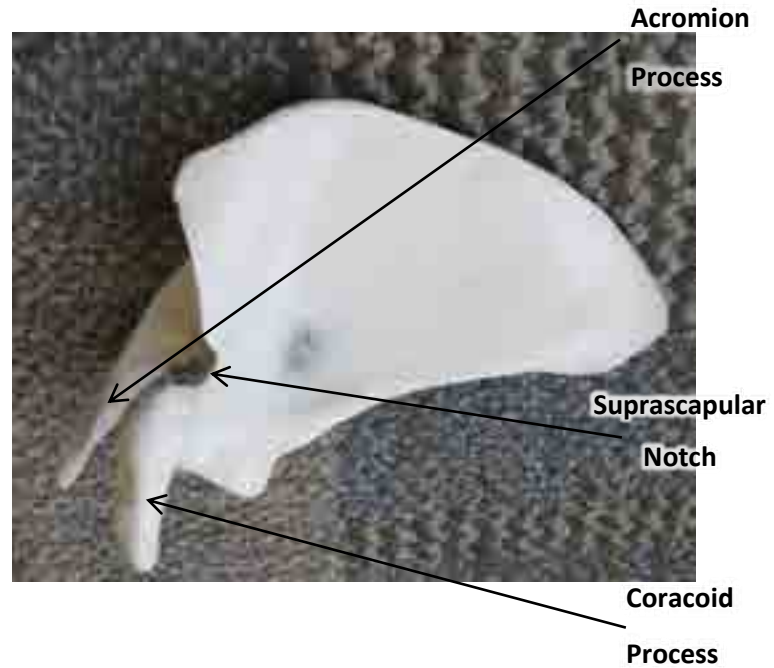



**Various  
Ribs**



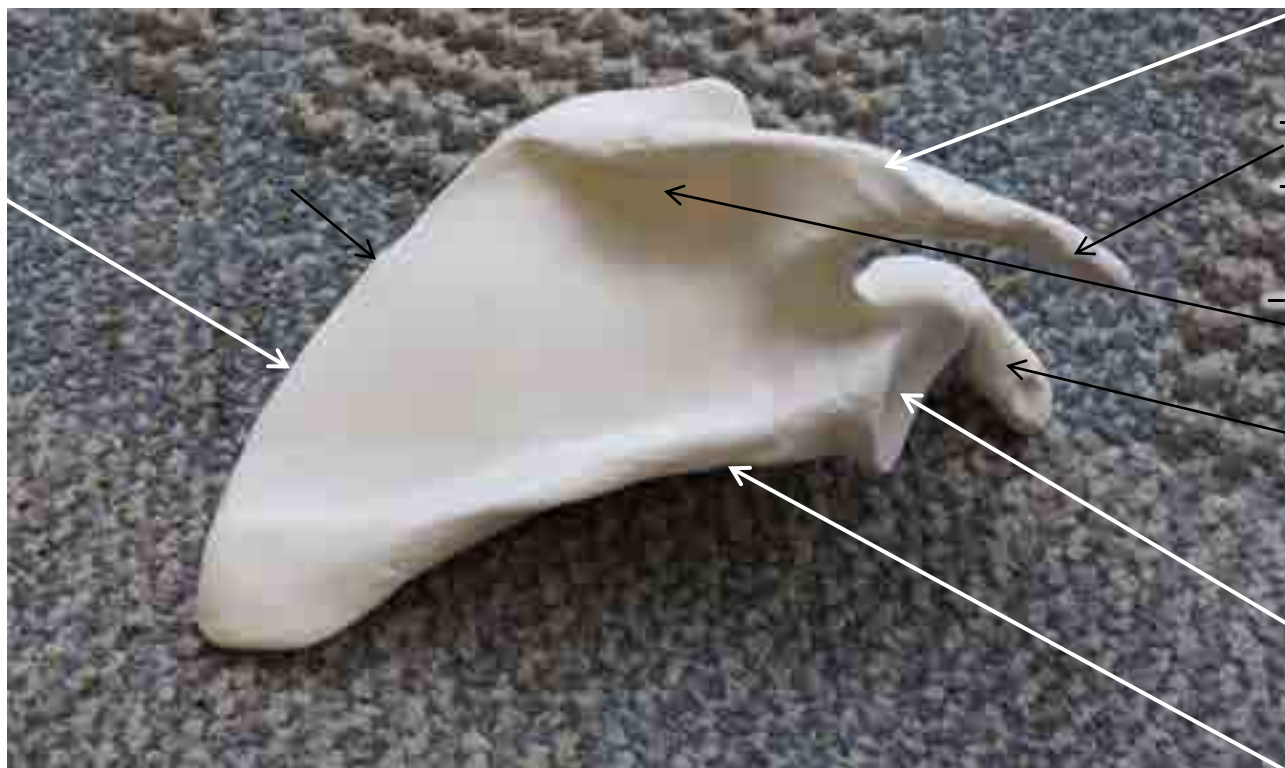
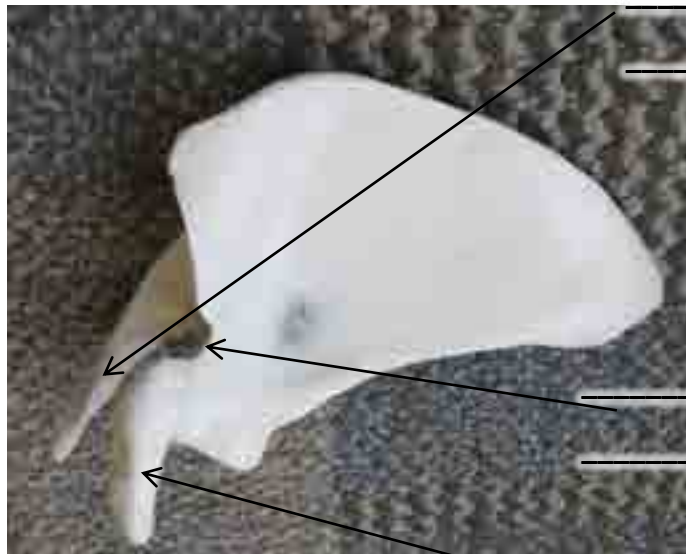



## SCAPULA MODEL

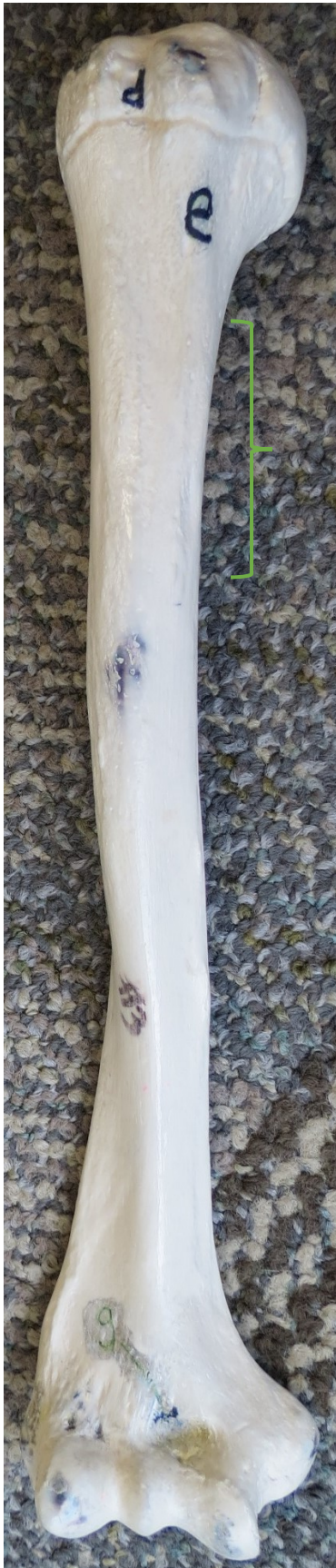



\_\_\_\_\_

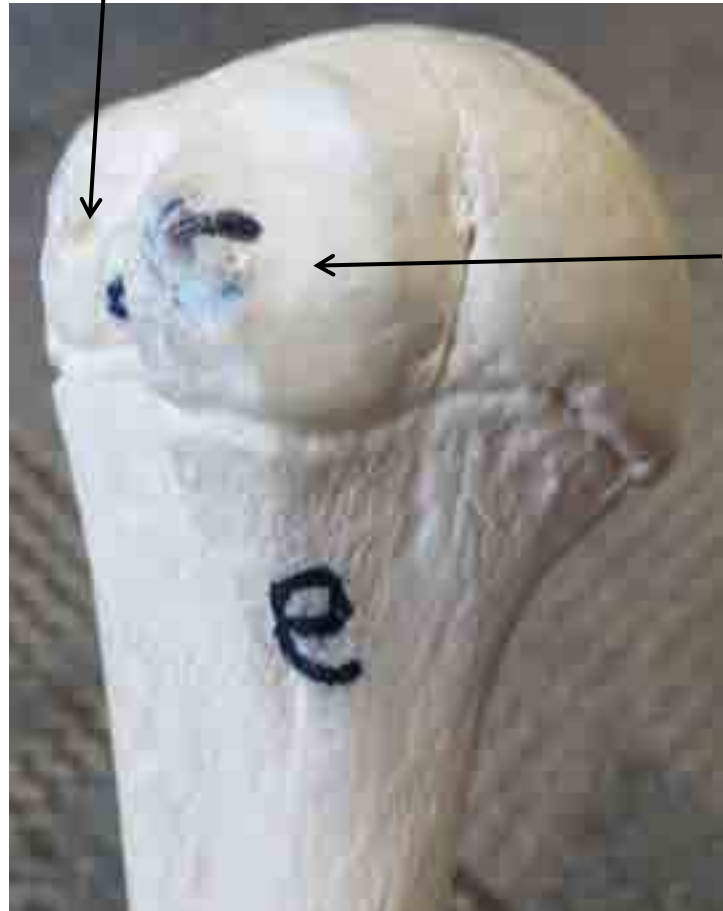


# HUMERUS



**Deltoid  
Tuberosity**  
(rough area  
of humerus)

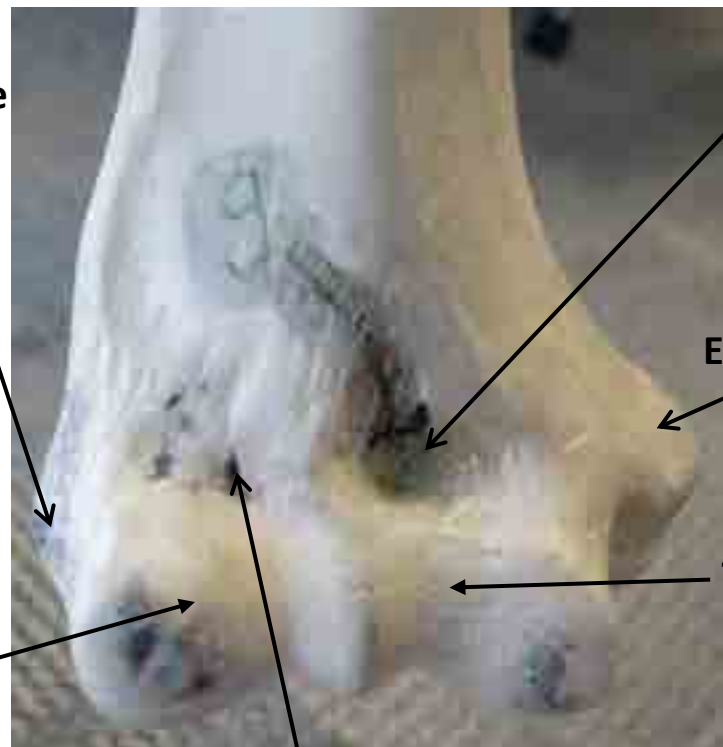
**Greater  
Tubercle**



**Lesser  
Tubercle**

**Lateral  
Epicondyle**

**Capitulum**



**Coronoid  
Fossa**

**Medial  
Epicondyle**

**Trochlea**

**Radial Fossa**



Head      Anatomical Neck

Surgical Neck

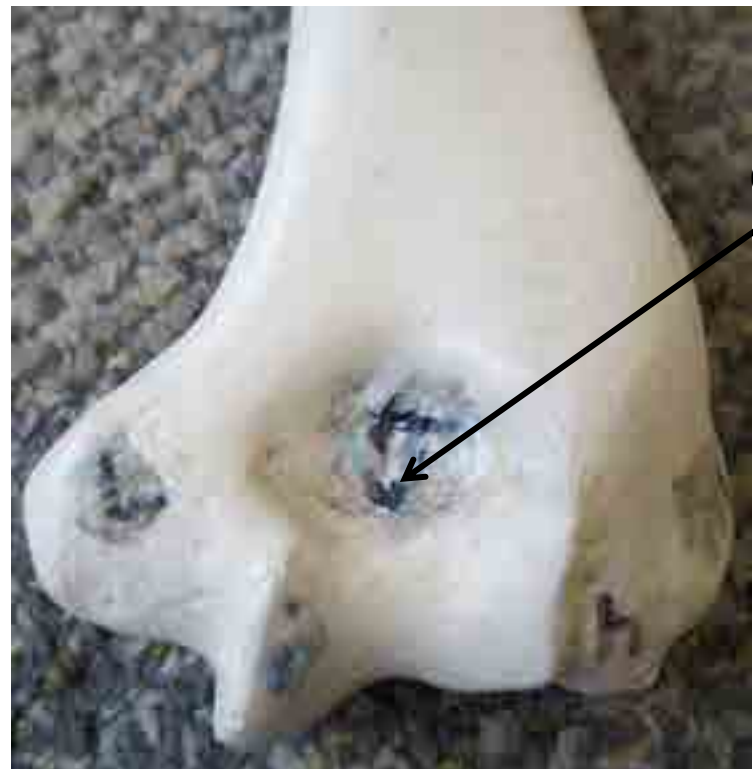


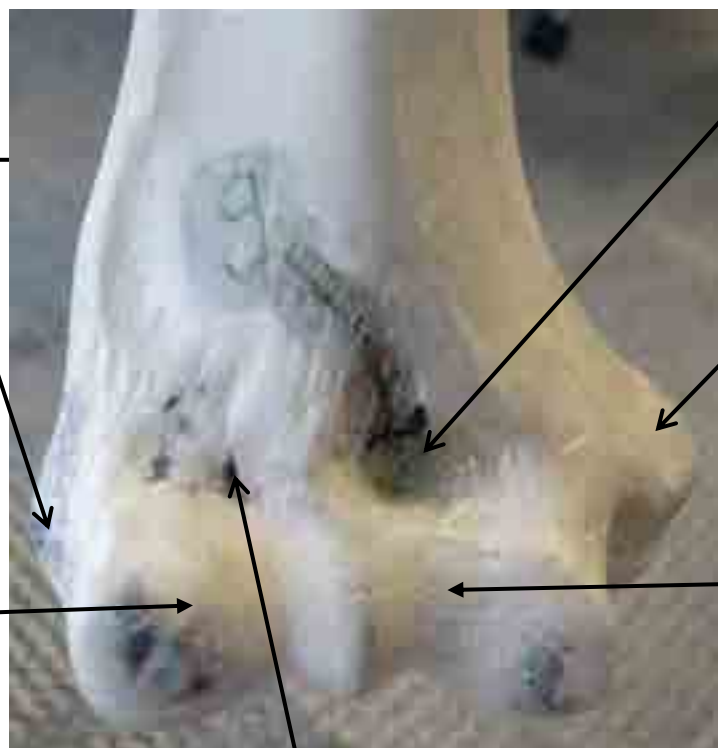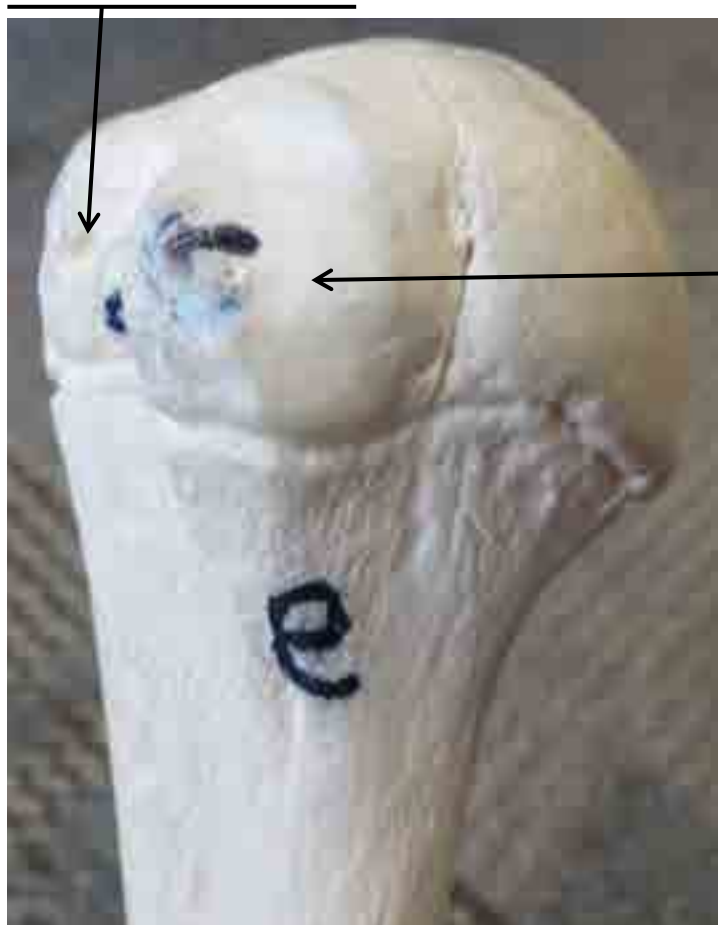
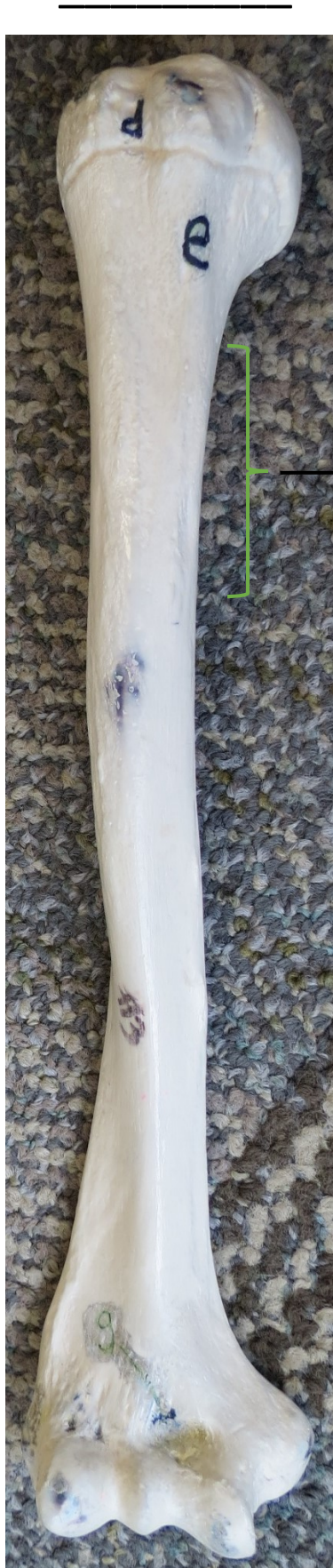Head      Anatomical Neck

Surgical Neck

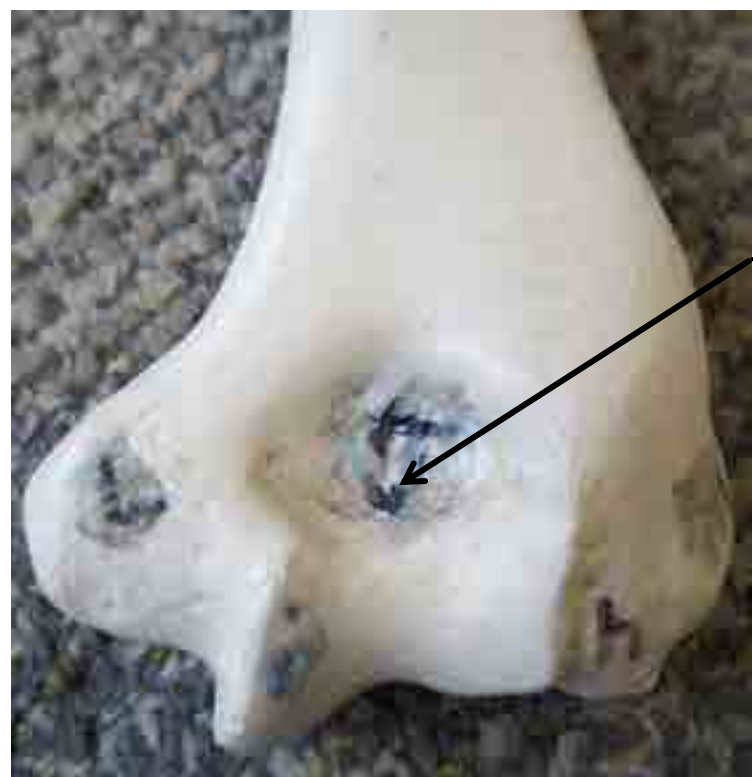



Olecranon Fossa










# Ulna Bone Model

Trochlear  
Notch



Olecranon  
Process

Coronoid  
Process


Radial  
Notch



Styloid  
Process of  
Ulna





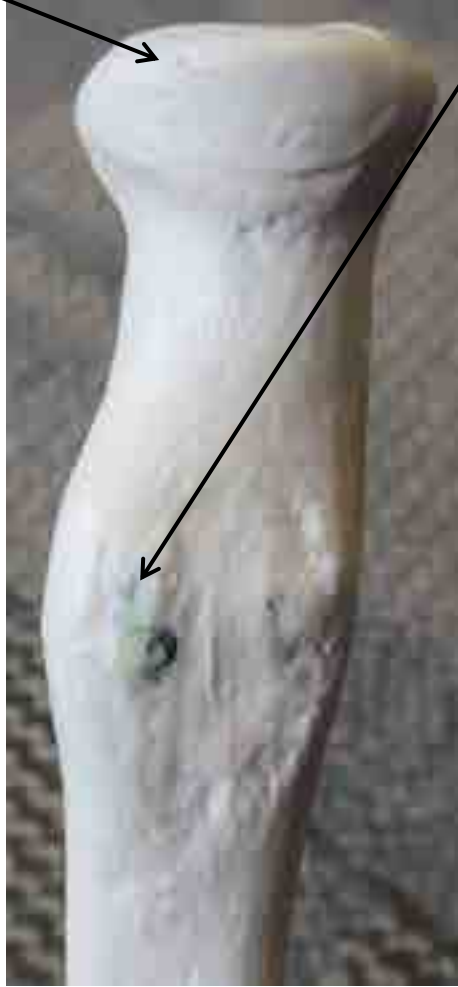



# RADIUS

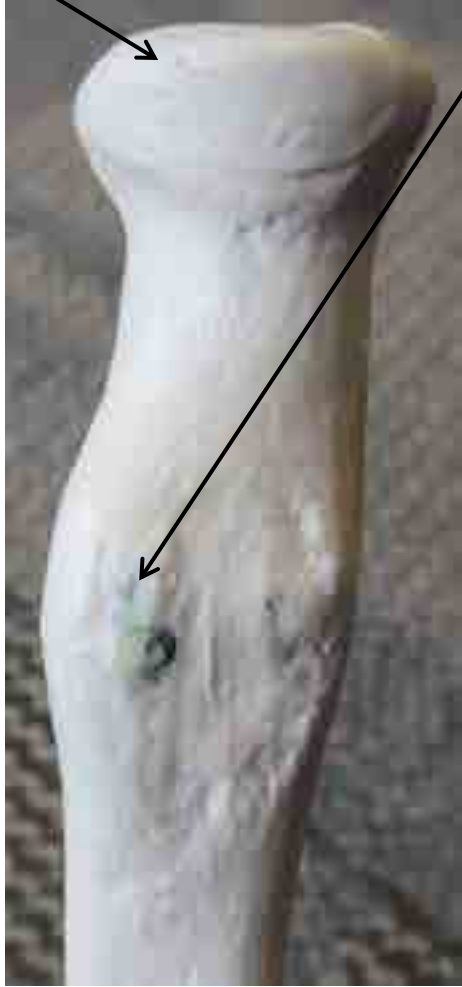Head of Radius

Radial Tuberosity

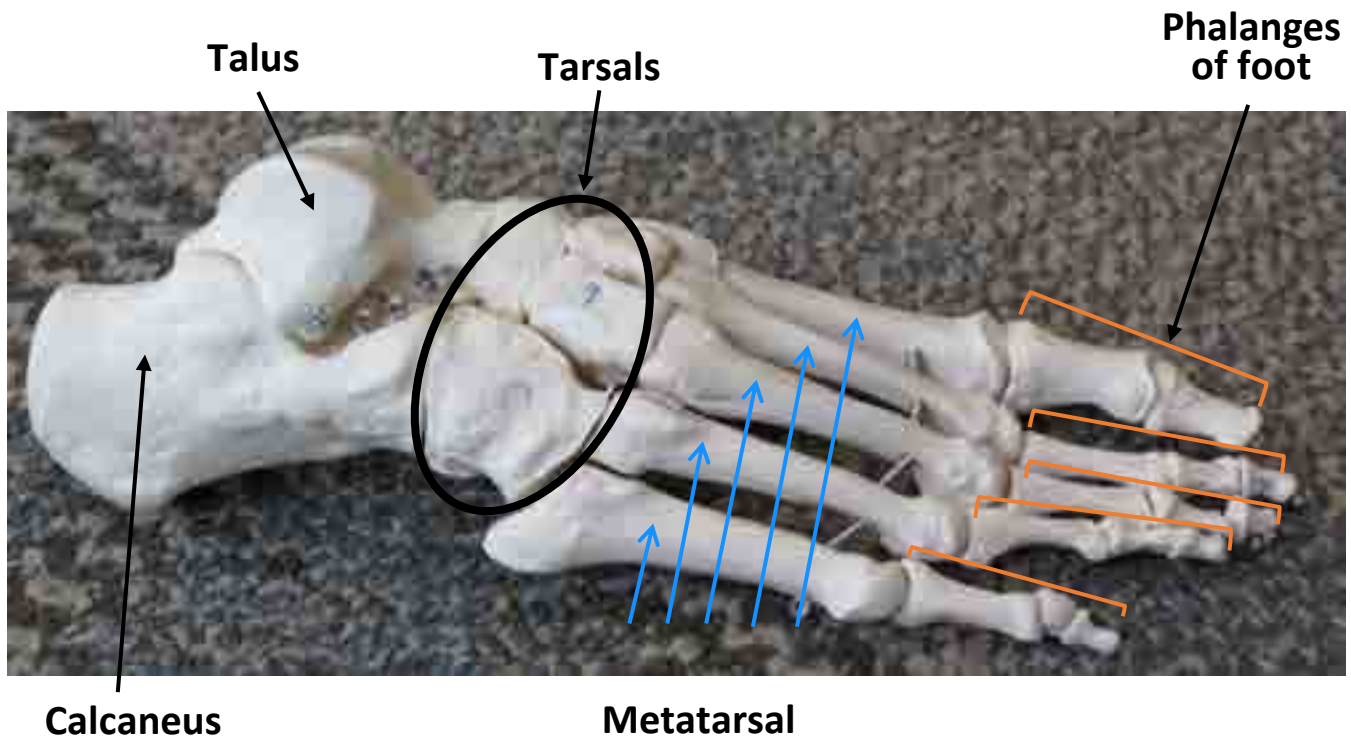
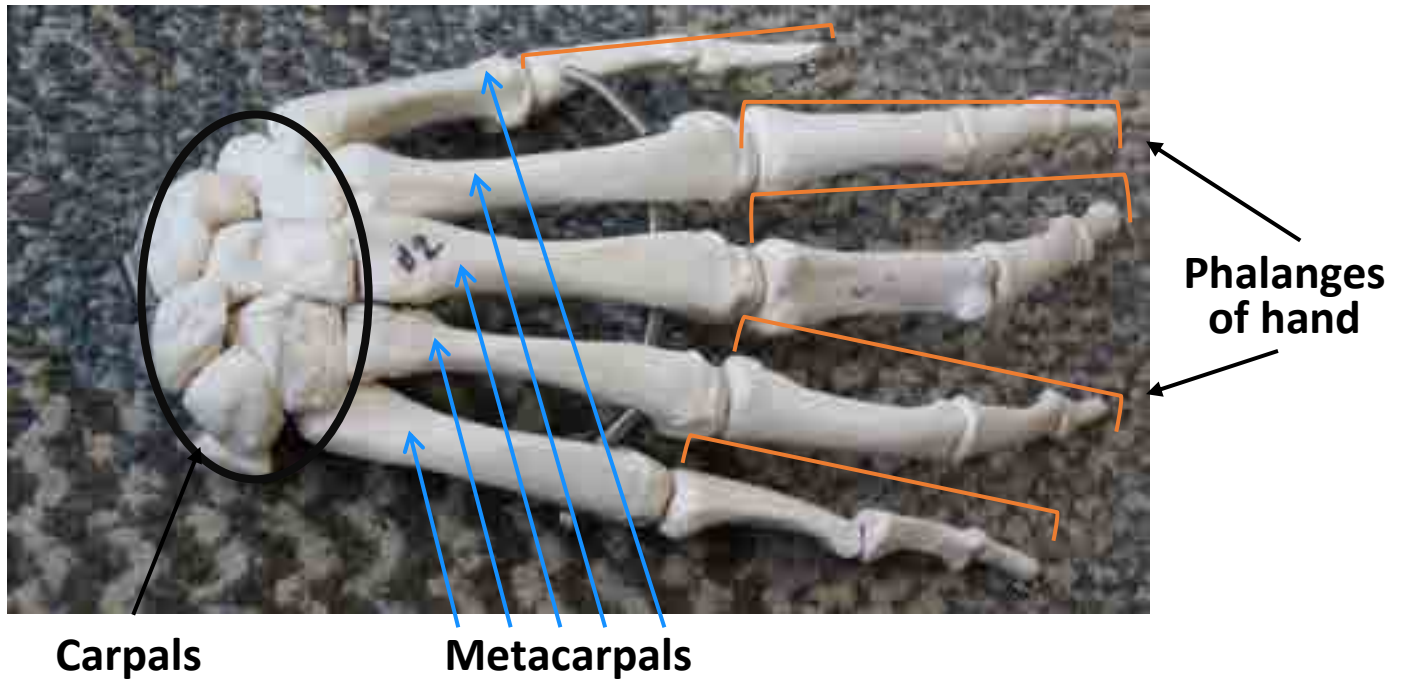


Styloid Process of Radius




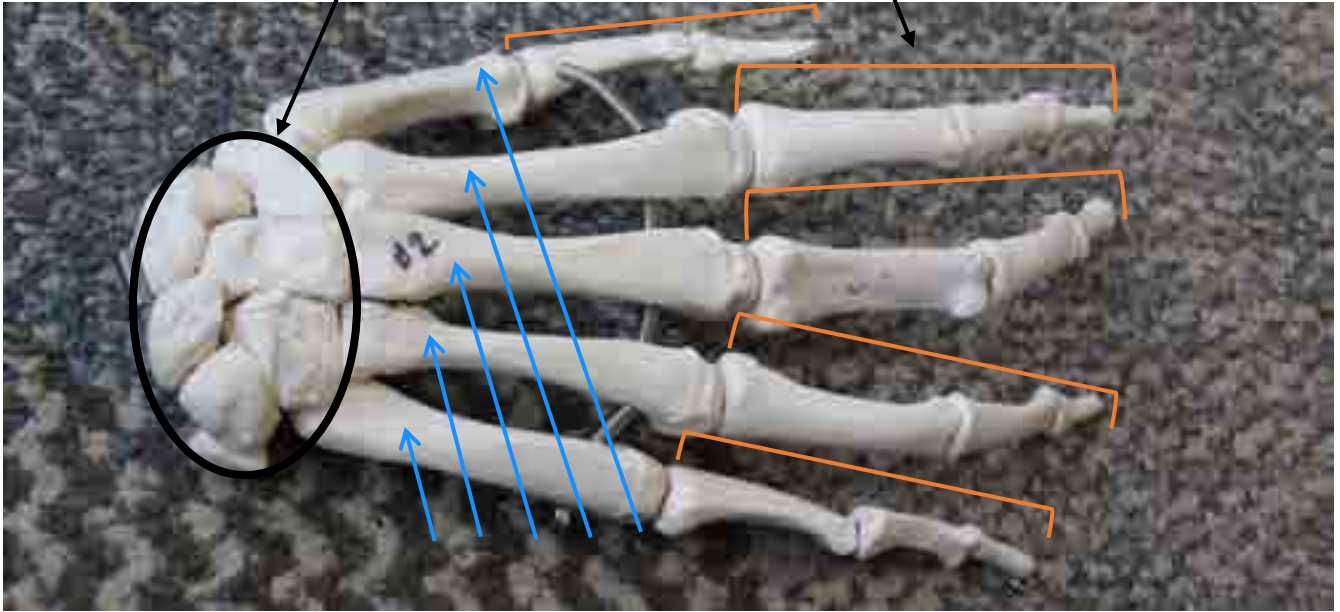

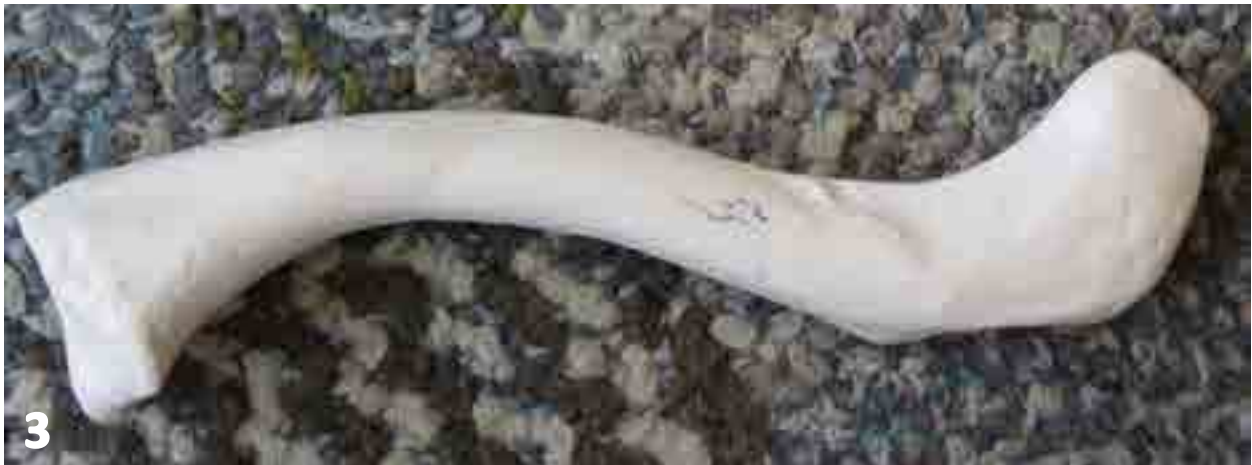
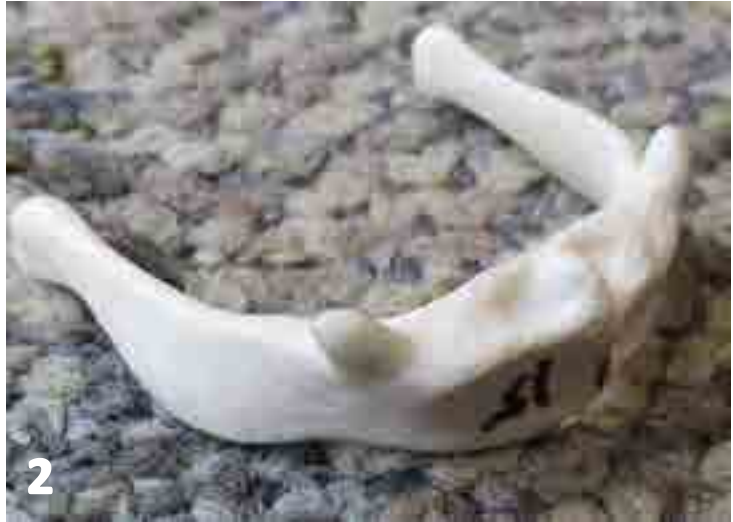# HAND



# FOOT

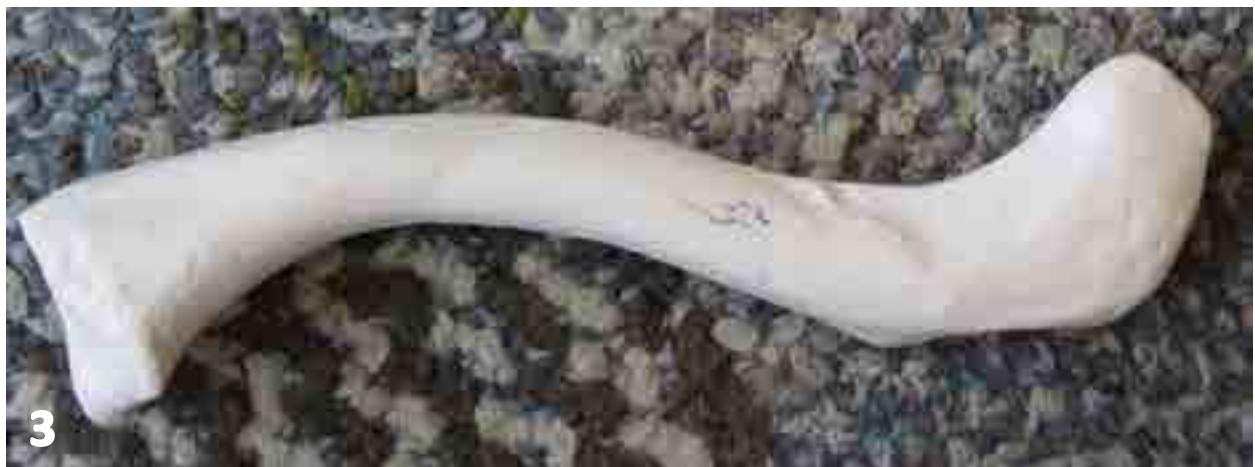
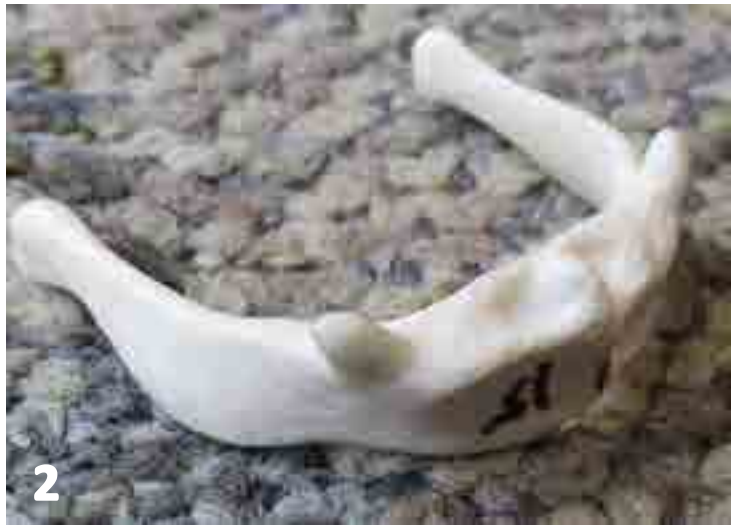




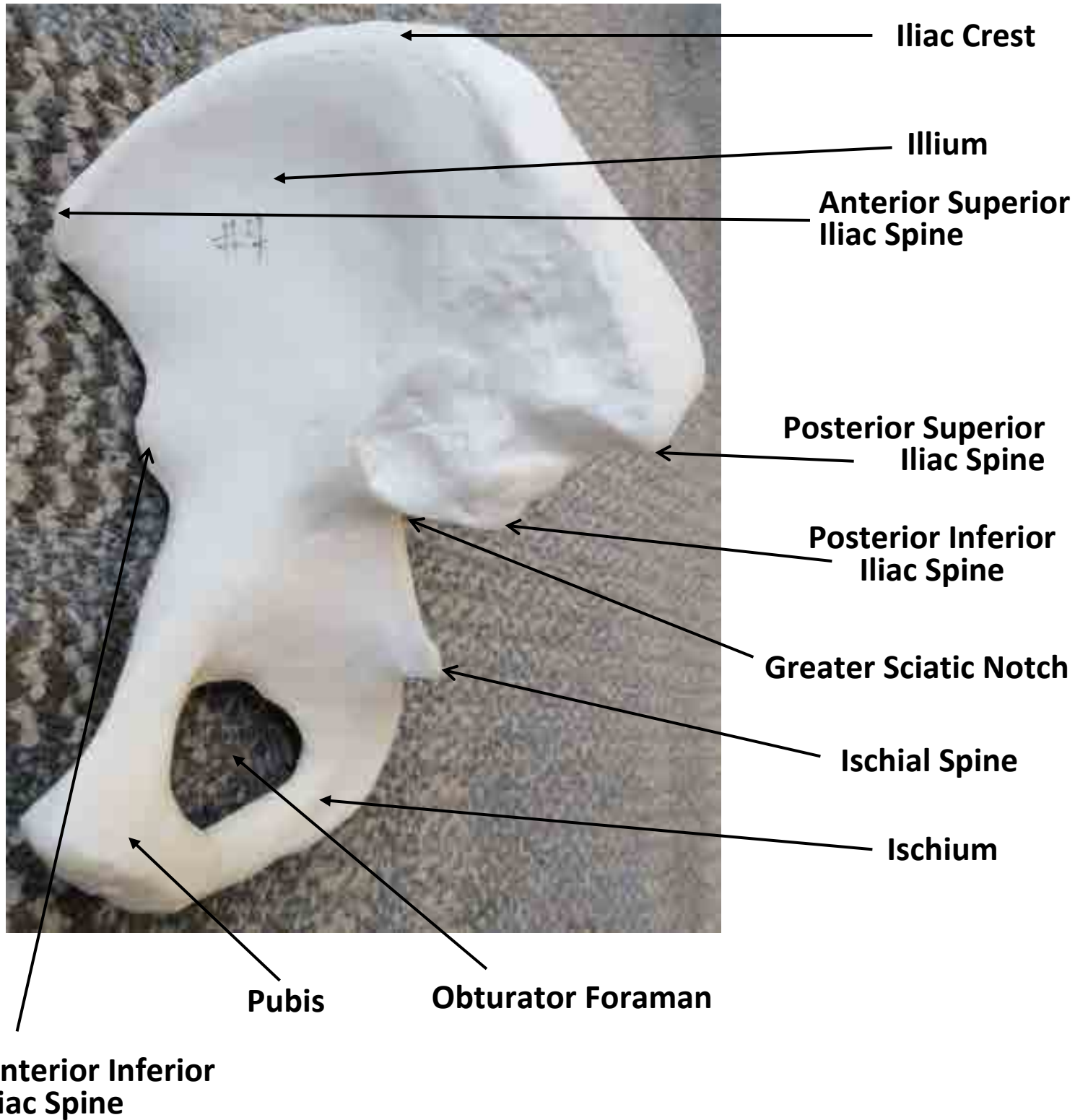
1. Patella
2. Hyoid
3. Clavicle






1. \_\_\_\_\_
2. \_\_\_\_\_
3. \_\_\_\_\_

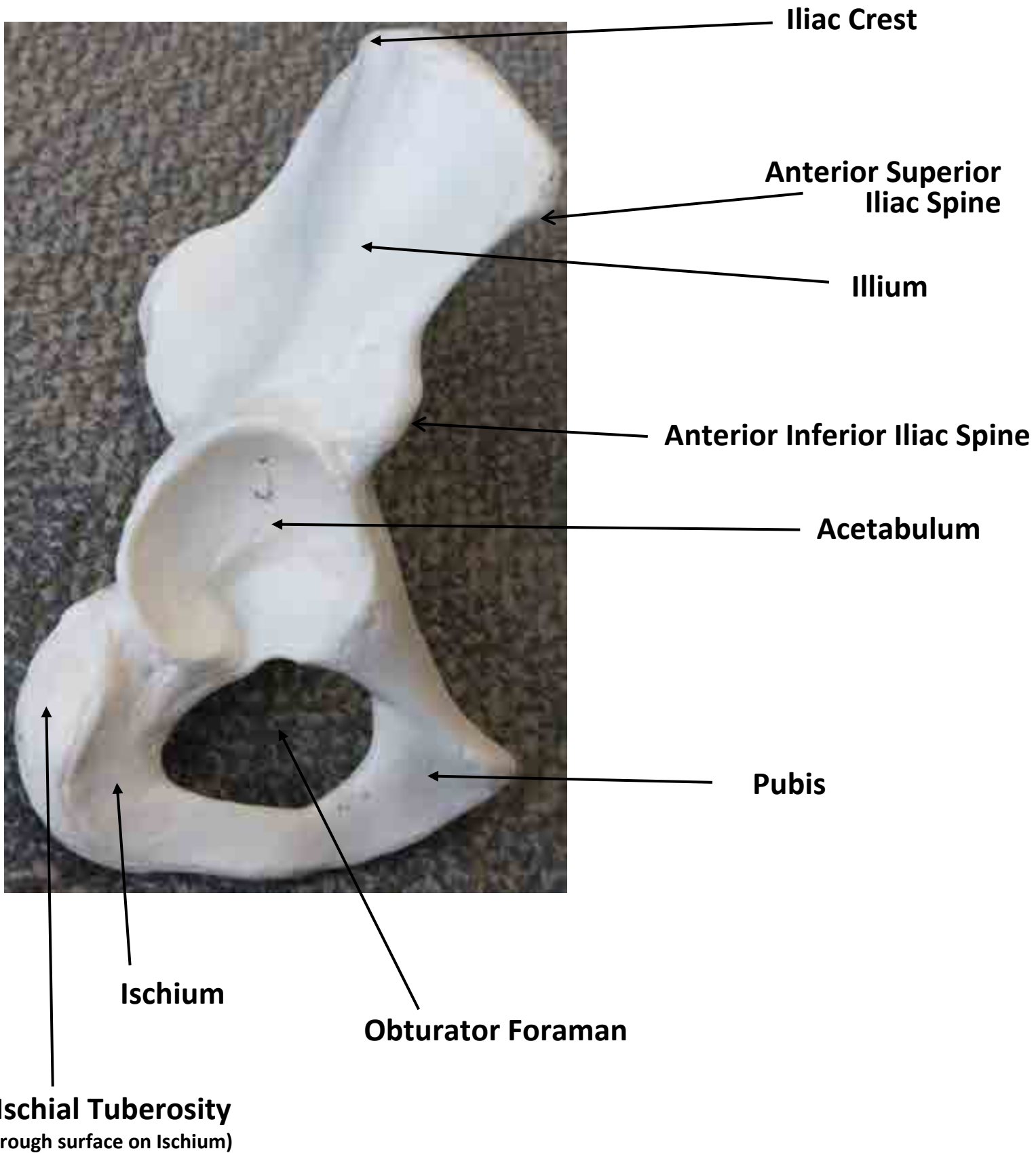
## COXAL BONE MODEL





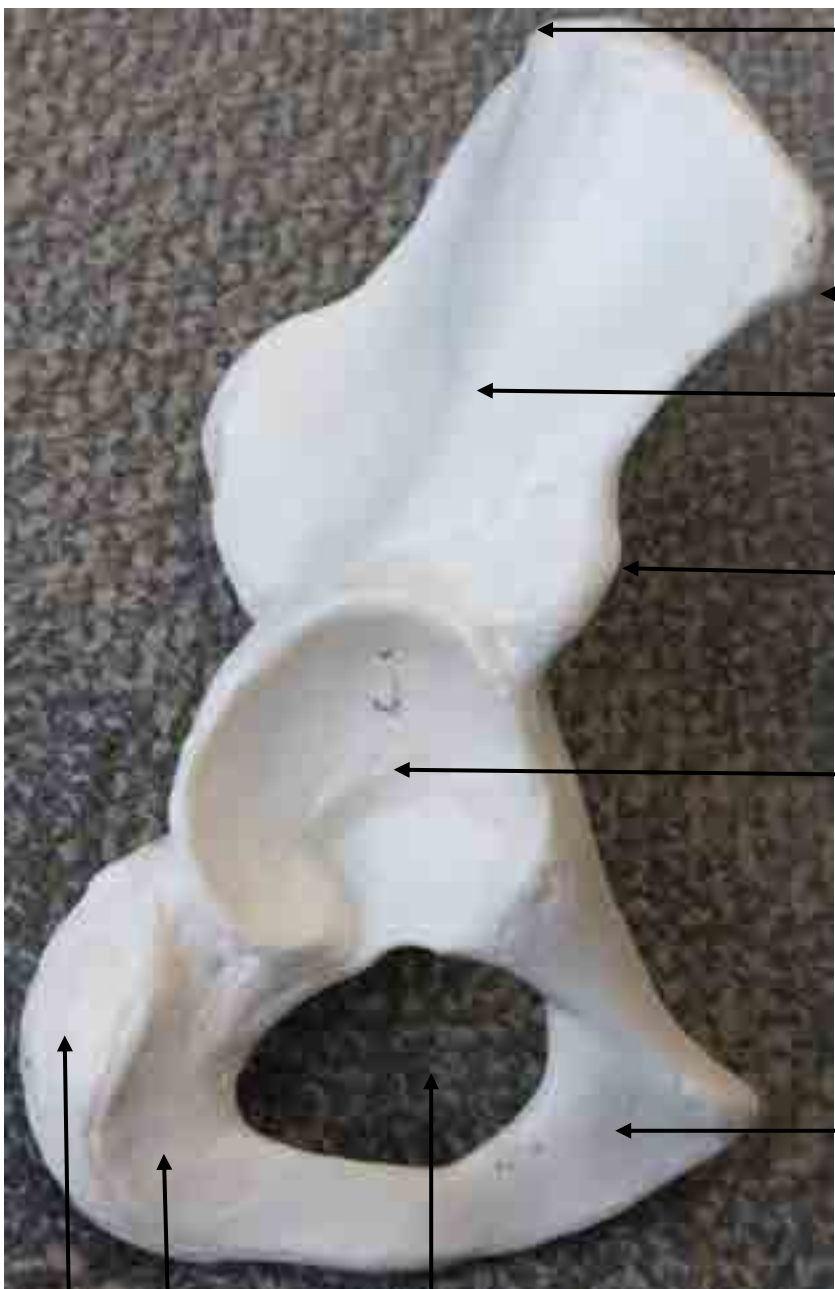


## Coxal Bone Model





\_\_\_\_\_



\_\_\_\_\_

\_\_\_\_\_

\_\_\_\_\_

\_\_\_\_\_

\_\_\_\_\_

\_\_\_\_\_

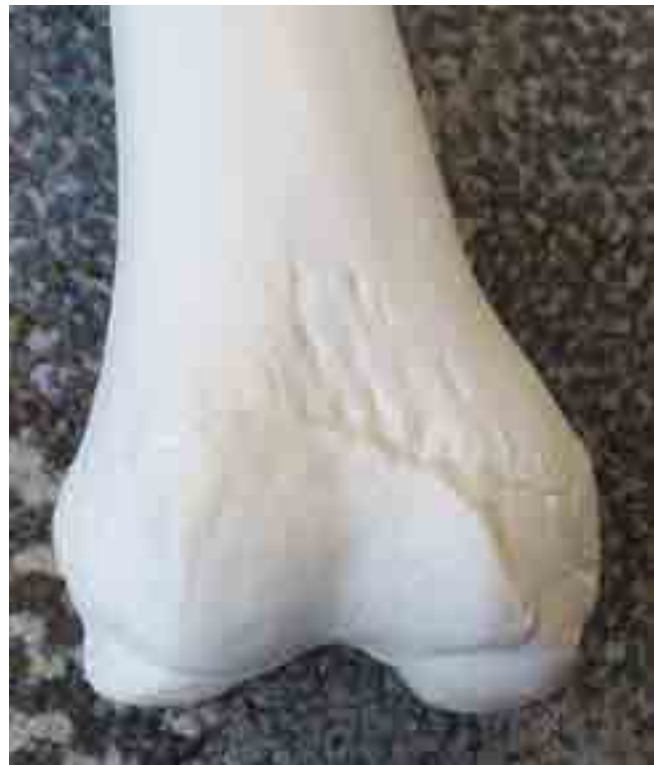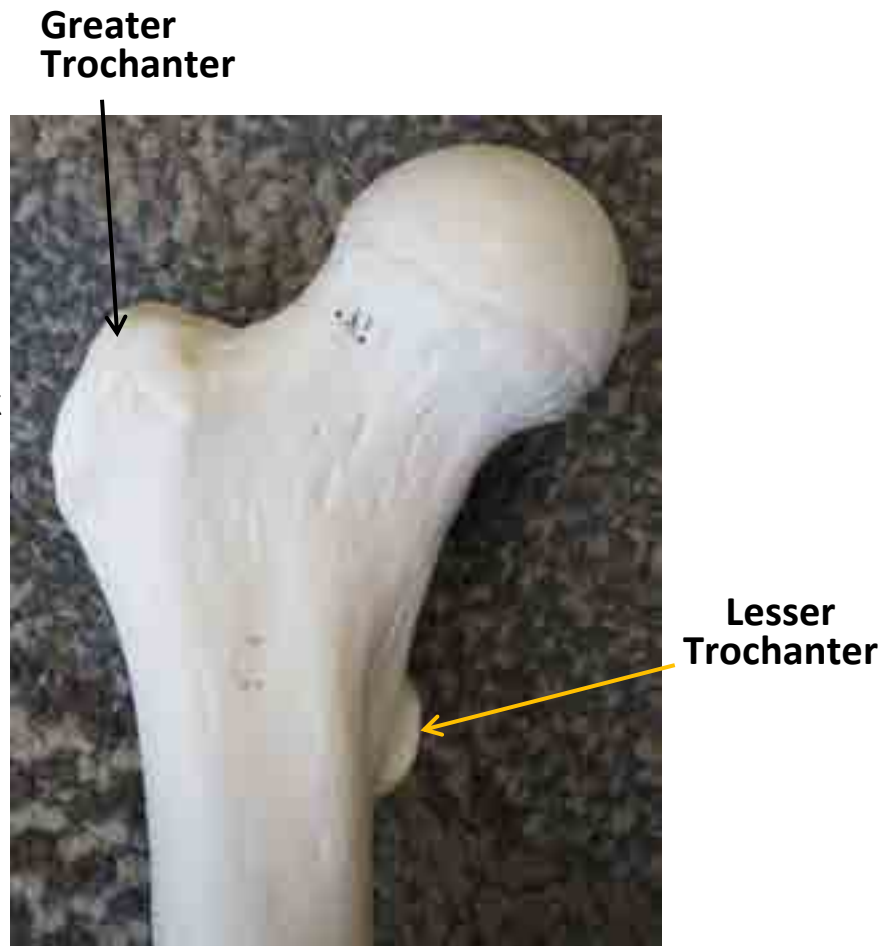
\_\_\_\_\_

\_\_\_\_\_

\_\_\_\_\_

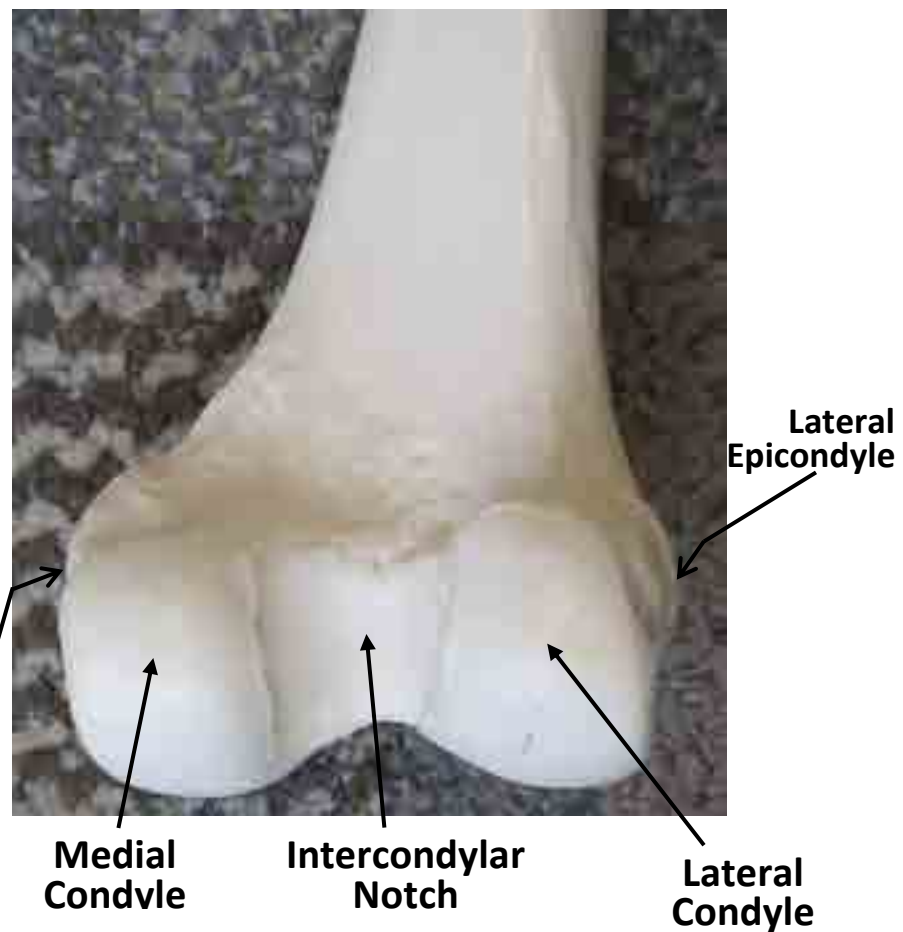
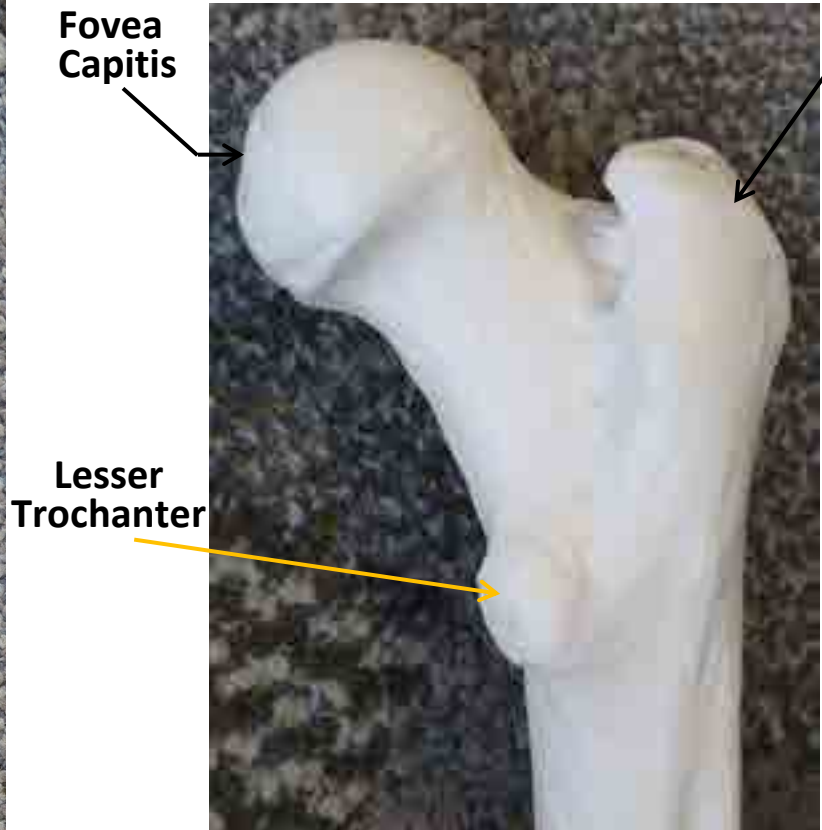

\_\_\_\_\_

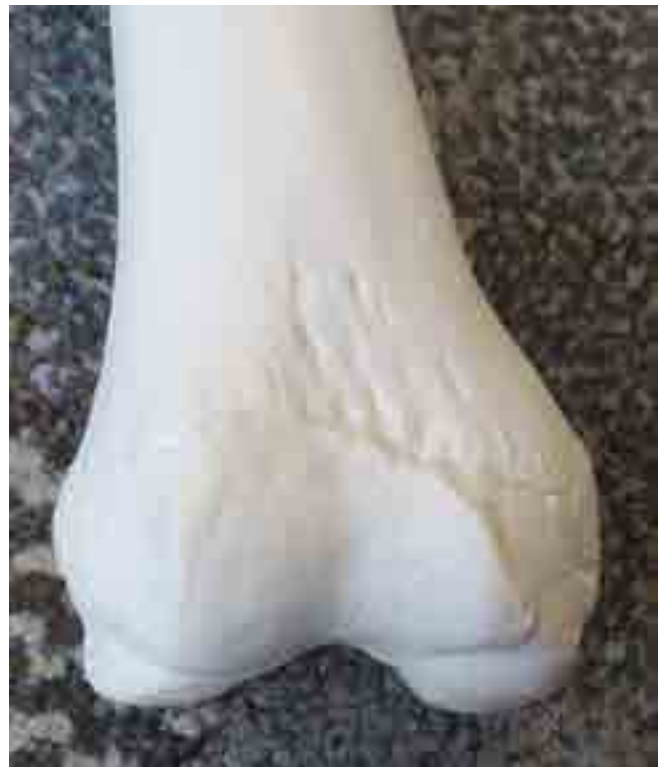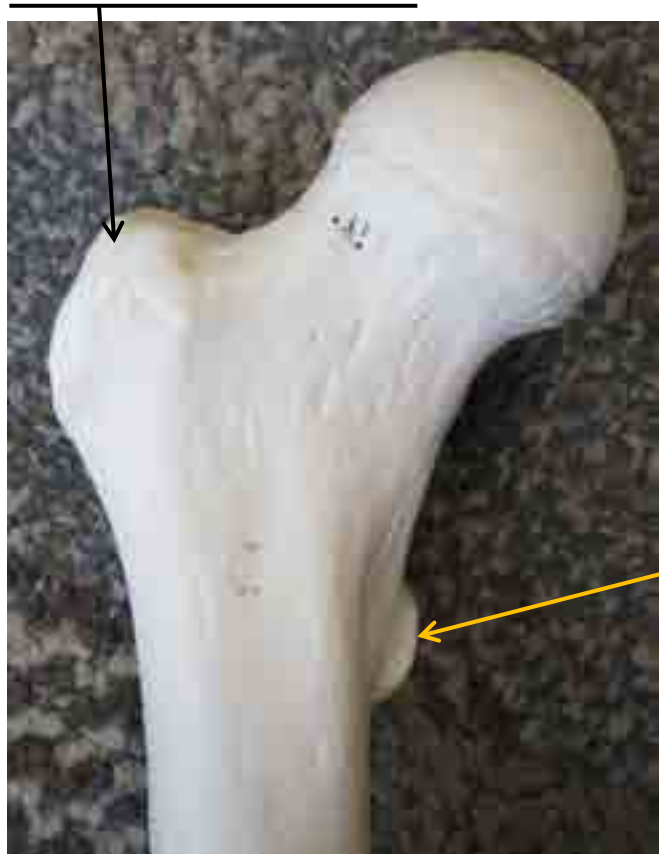## Femur Anterior View



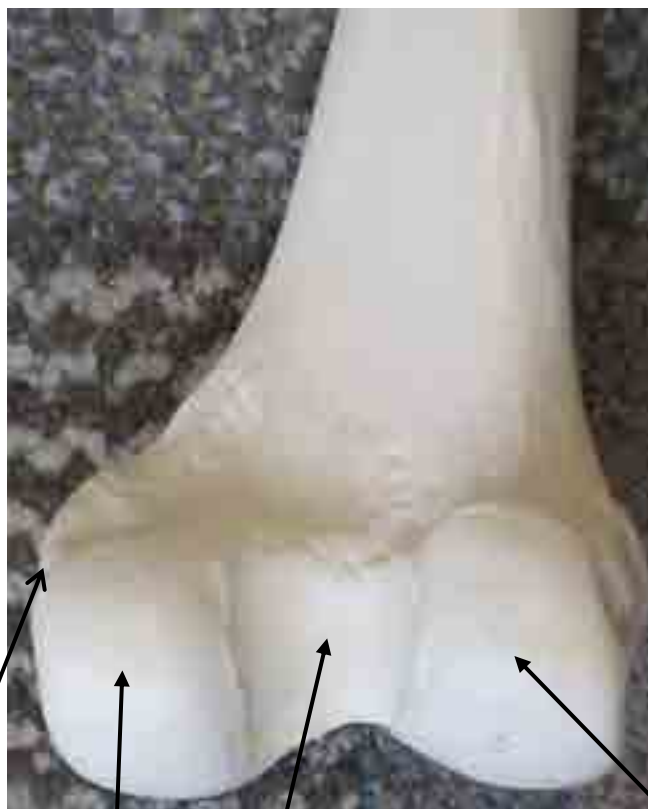
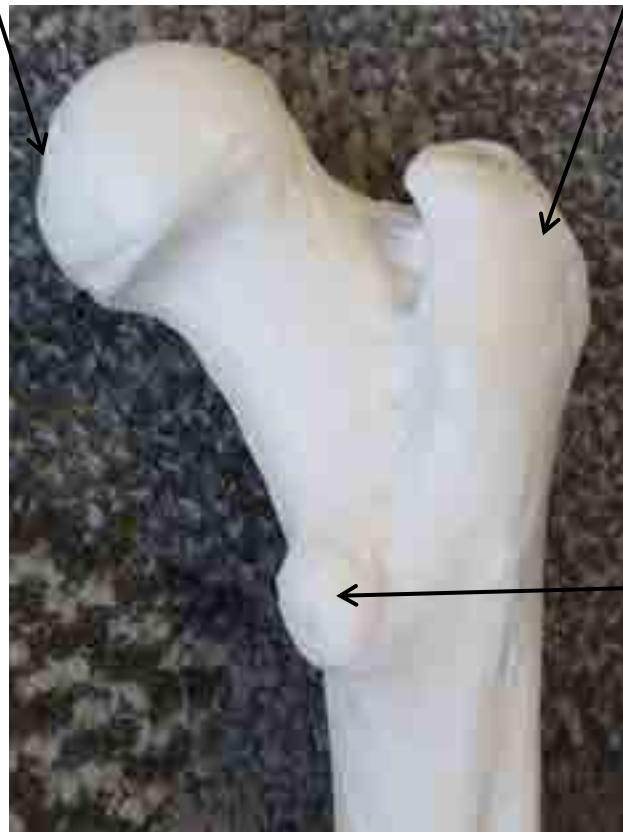



## Femur Posterior View









**Fibula**



**Tibia**




**Top of Tibia**

**Lateral  
Condyle**

**Intercondylar  
Eminence**

**Medial  
Condyle**




**Tibial  
Tuberosity**

**Lateral  
Malleolus**

**Medial  
Malleolus**







# HIP JOINT MODEL

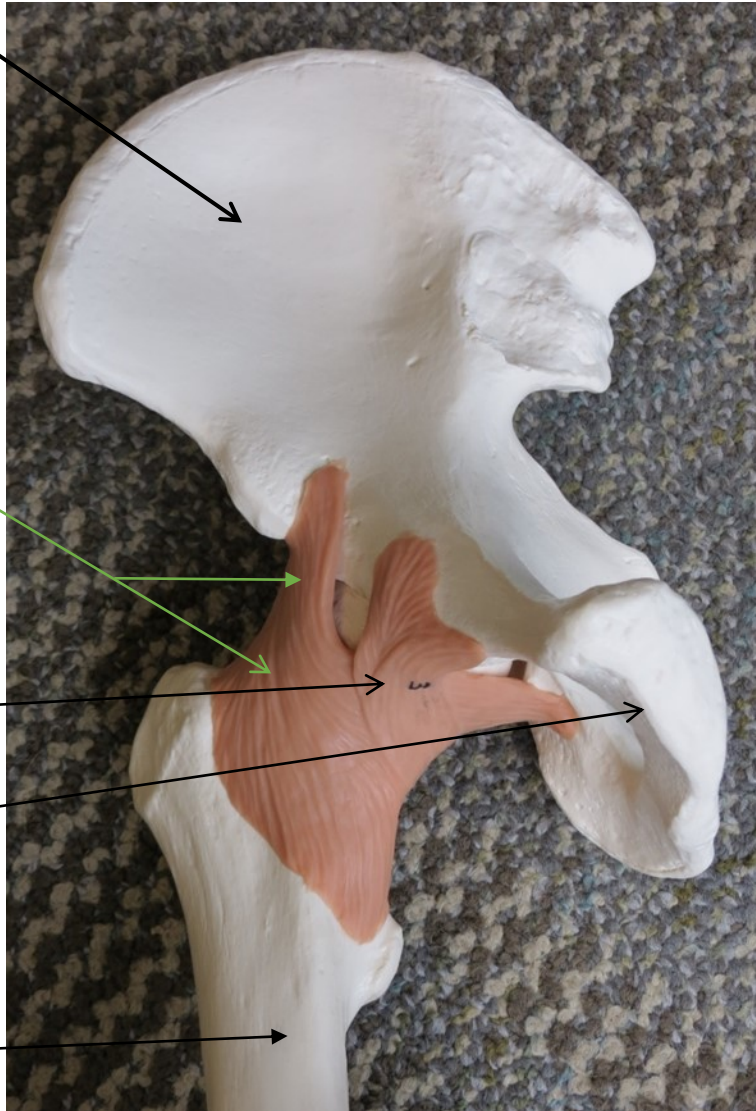
Ilium

Iliofemoral Ligament

Pubofemoral Ligament

Pubis

Femur



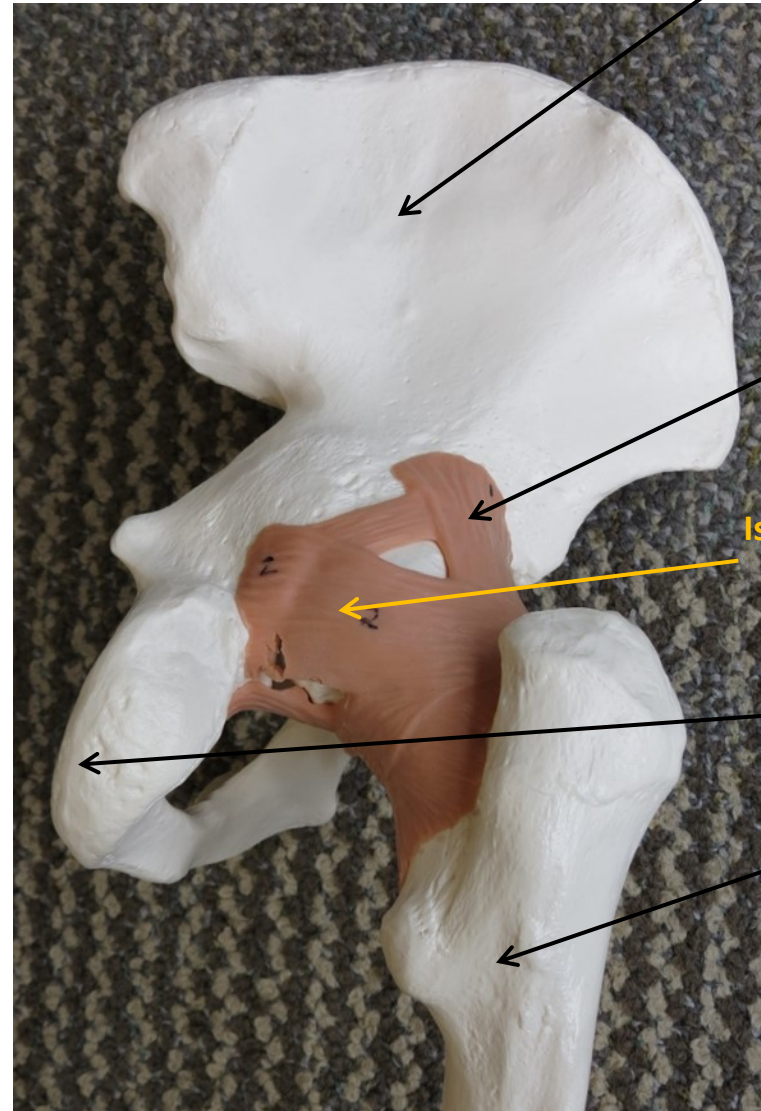
Ilium

Iliofemoral Ligament

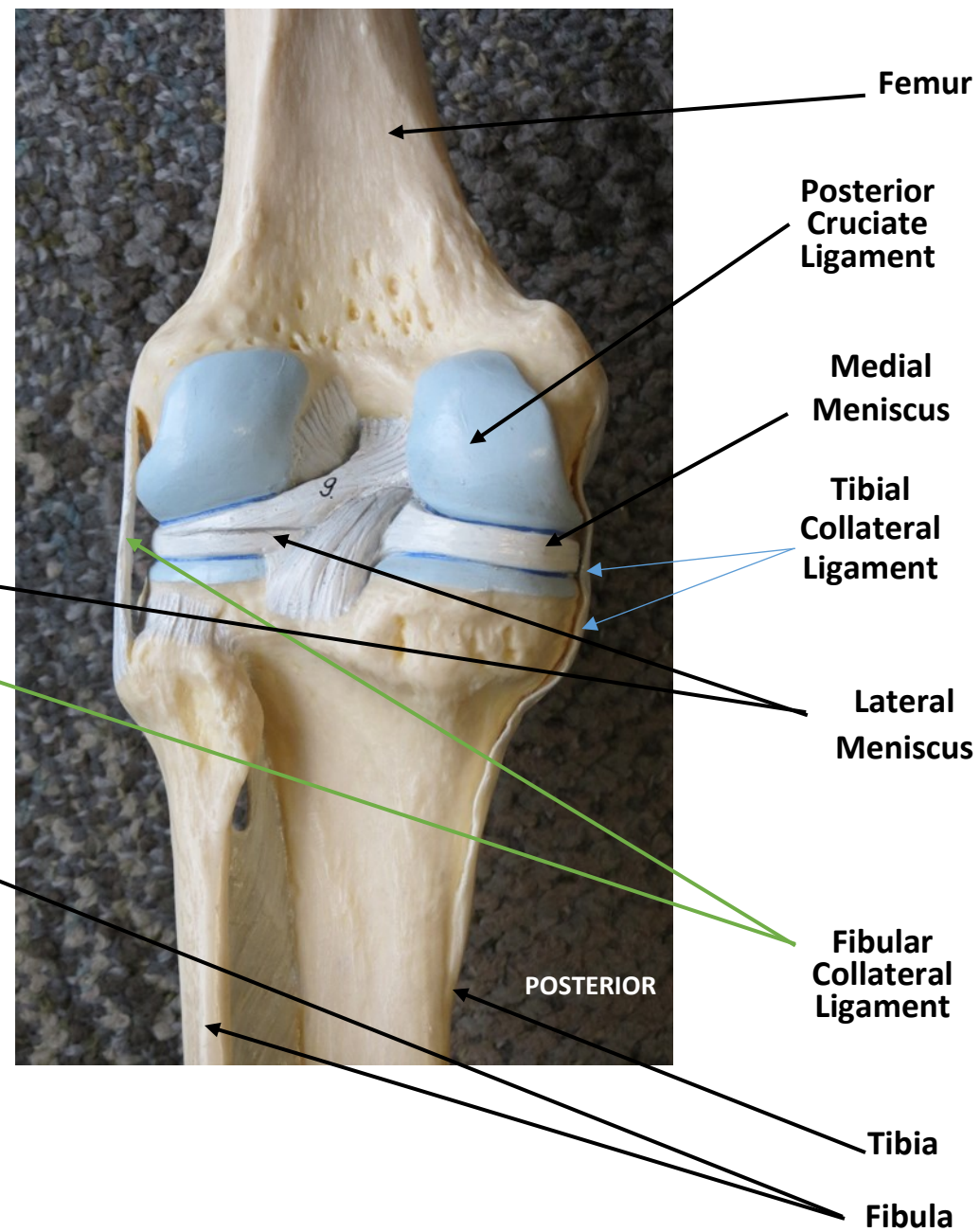
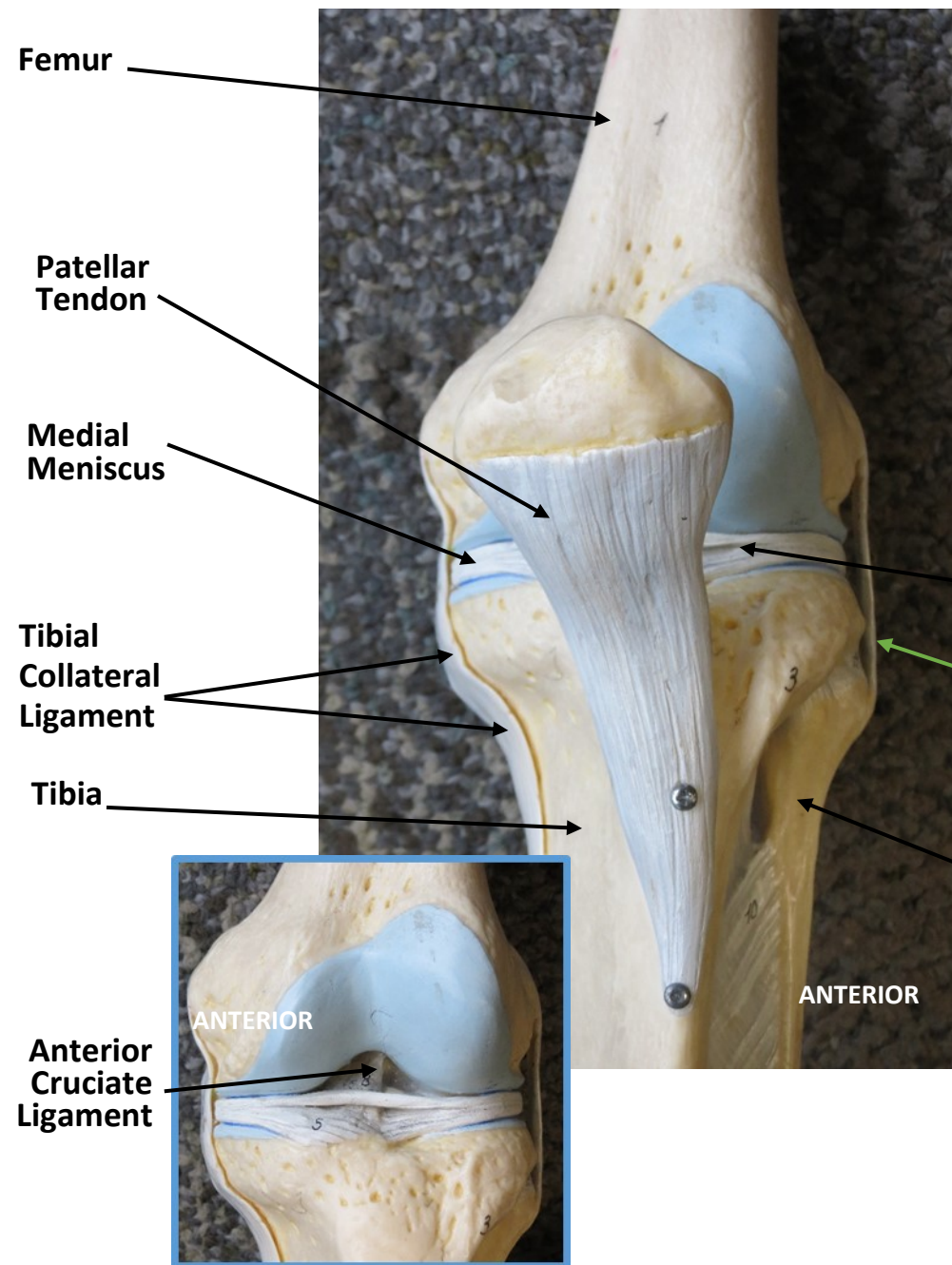
Ischiofemoral Ligament

Ischium

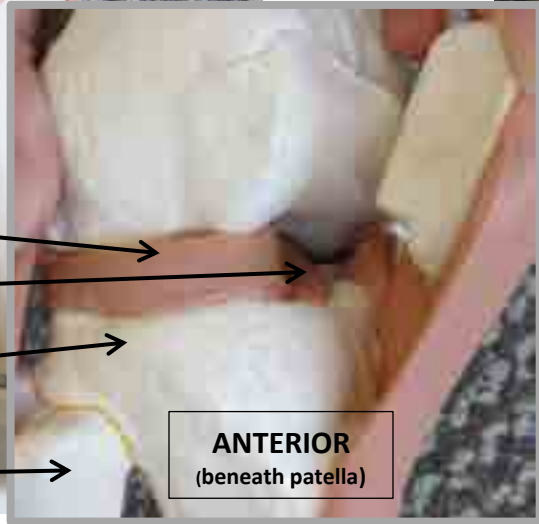
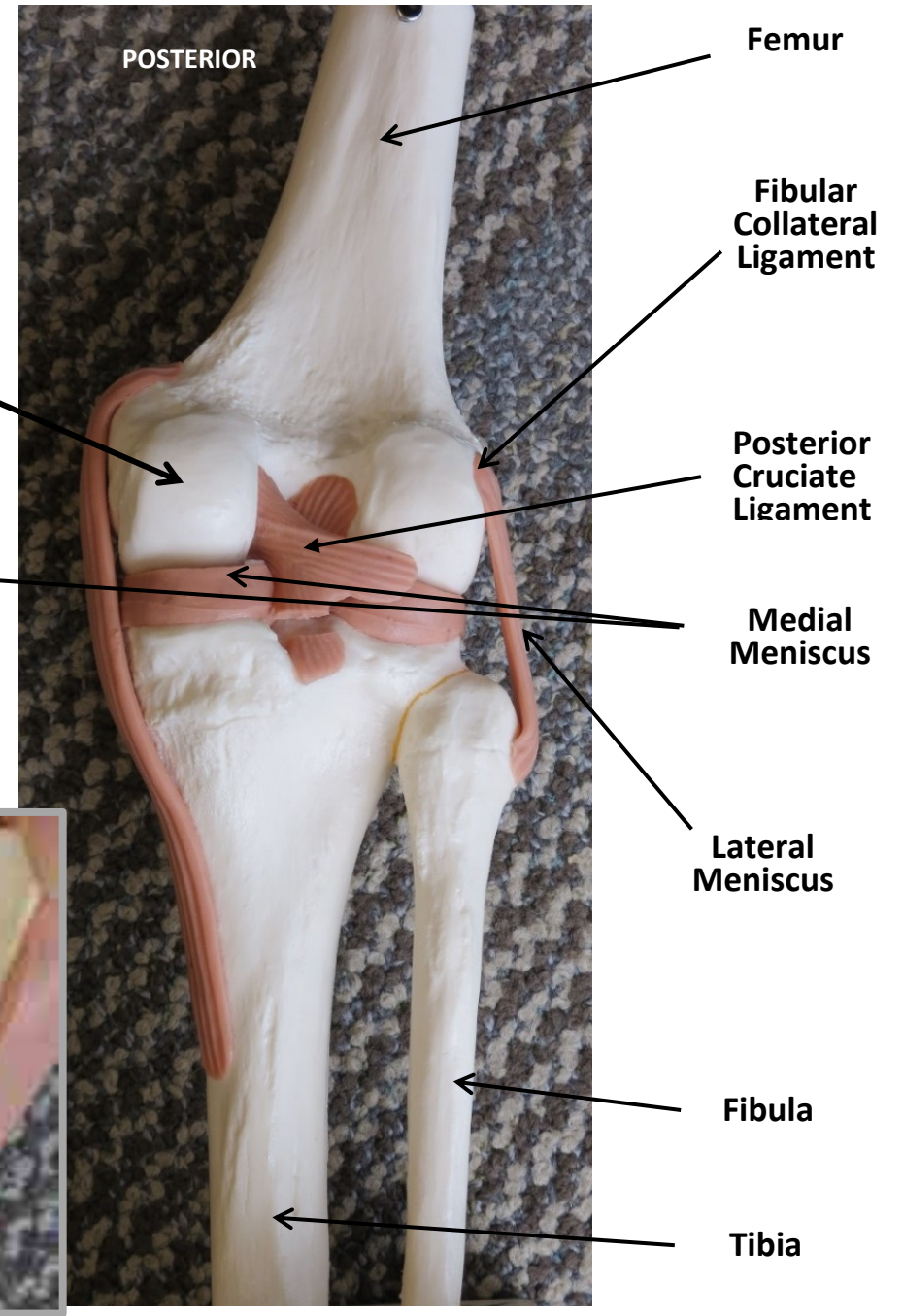
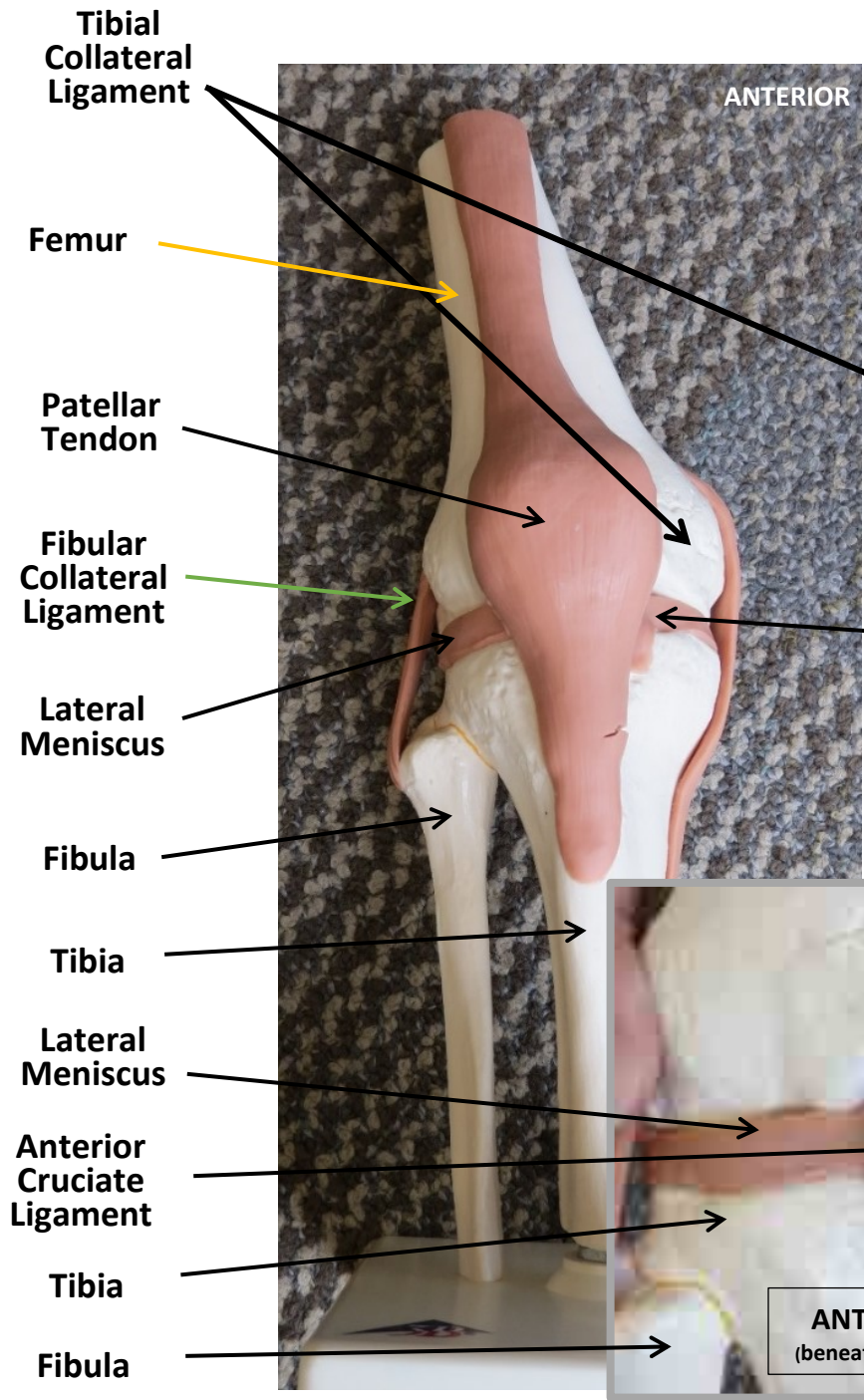
Femur



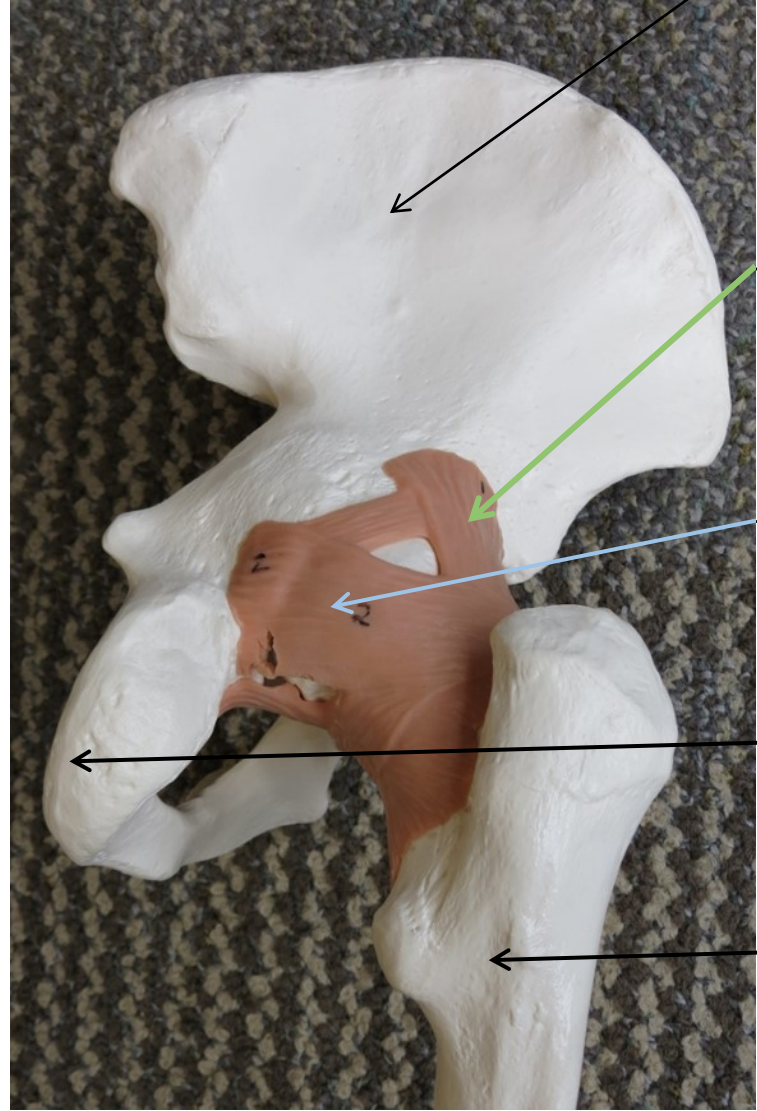
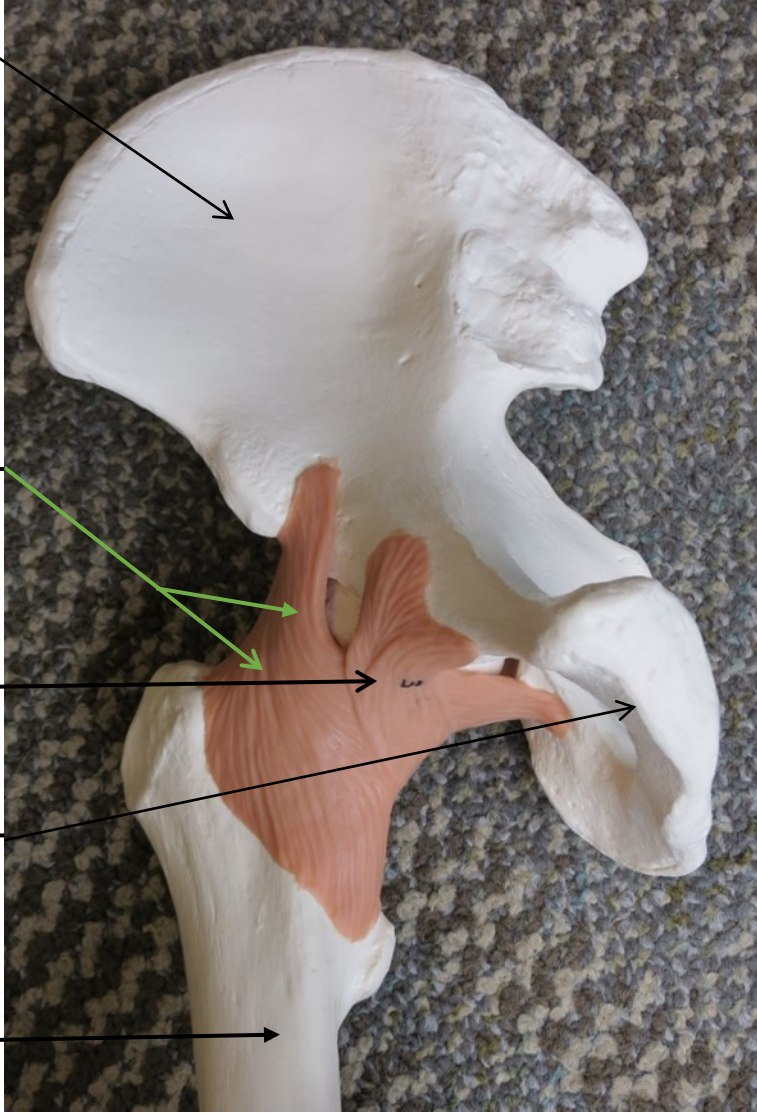


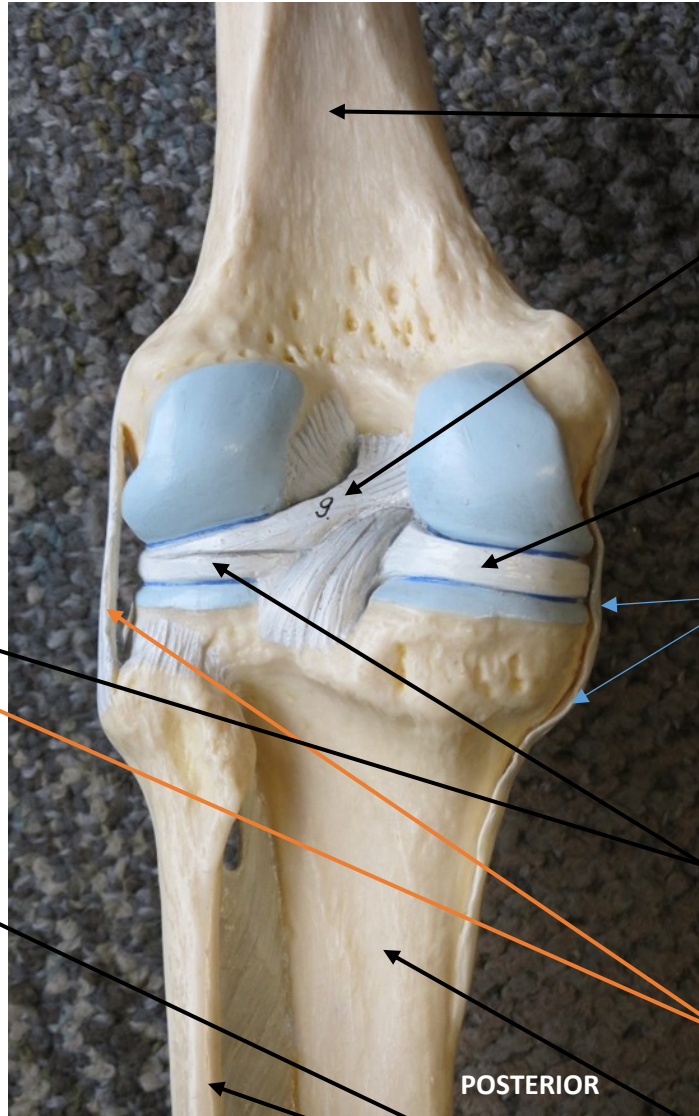
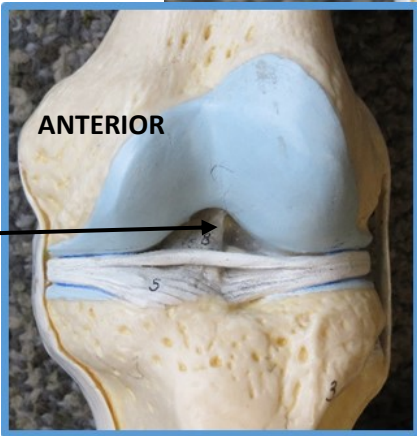
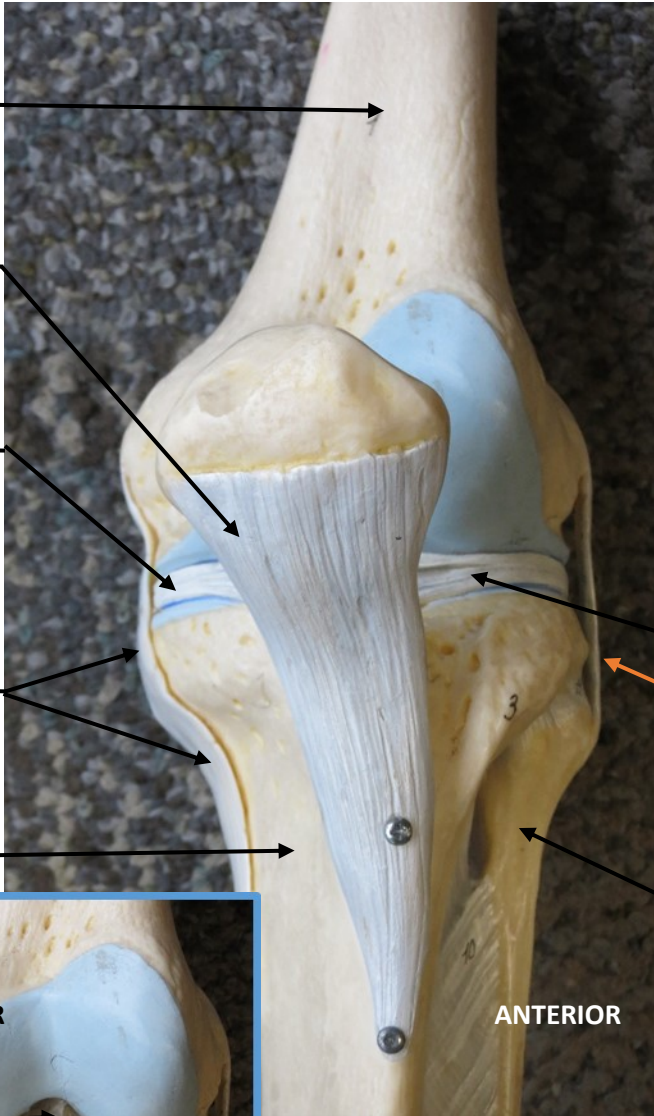




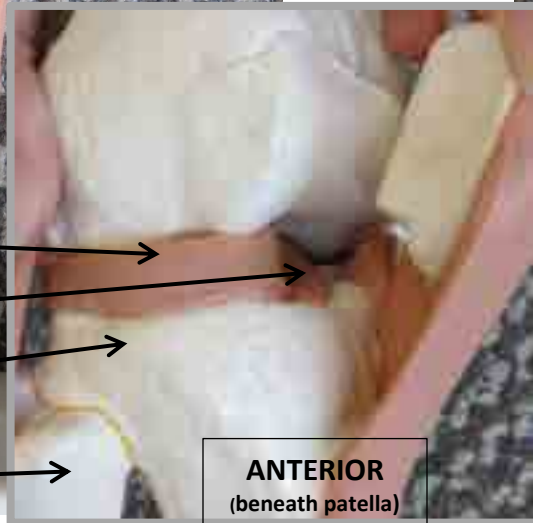
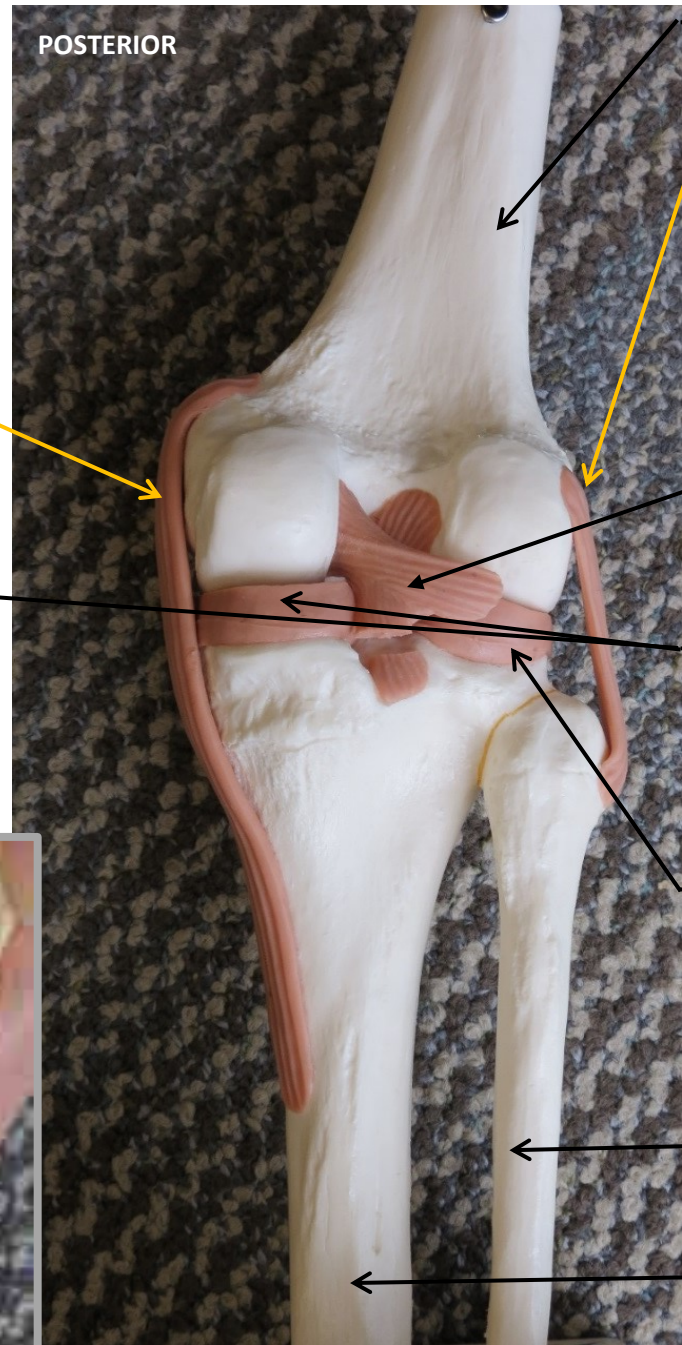
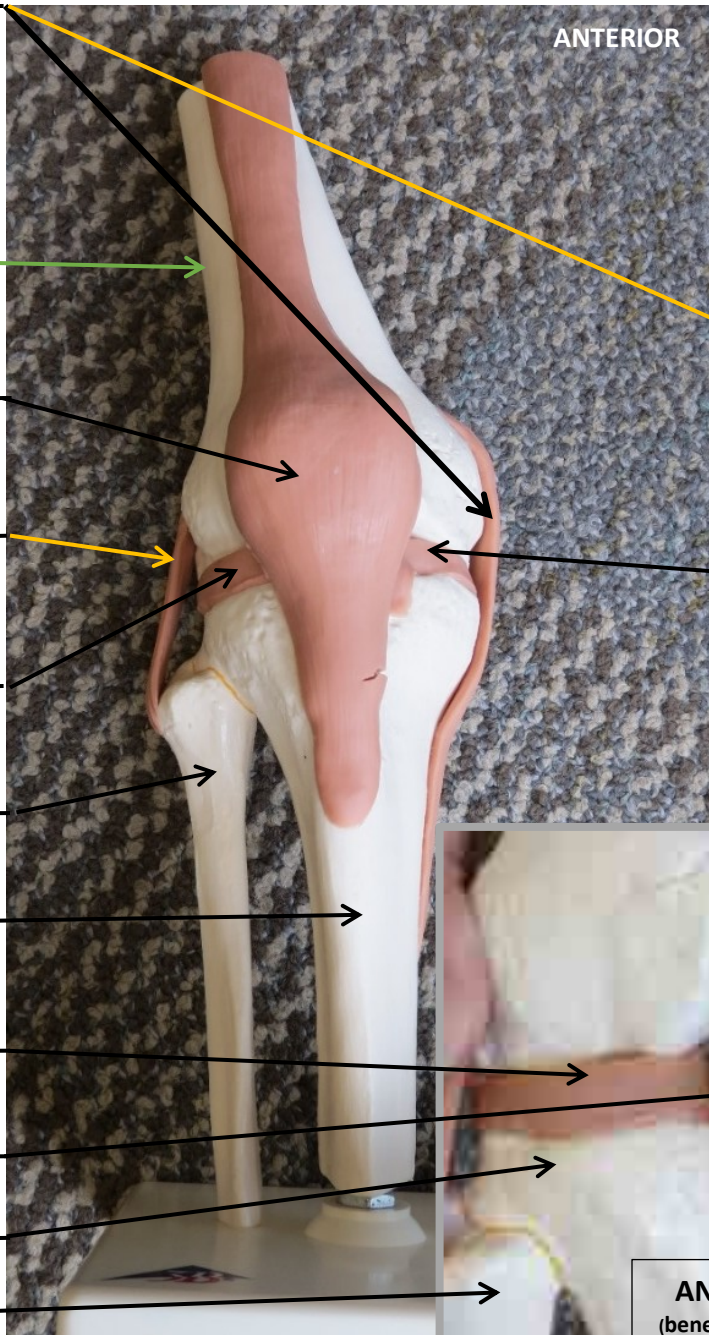














Scapula

Ribs

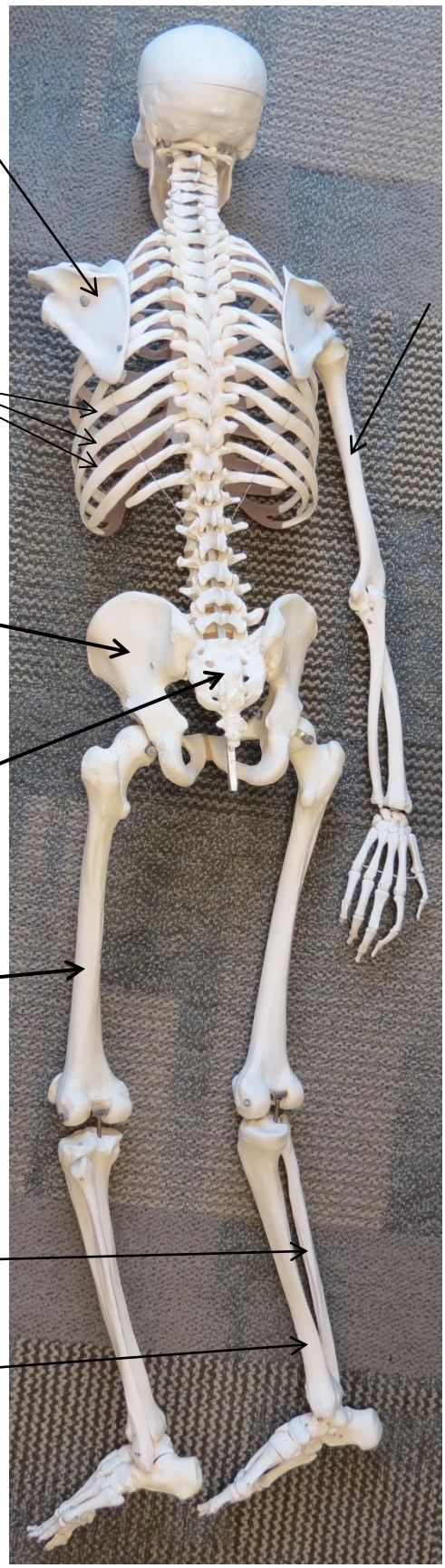
Coxal  
Bone

Sacrum

Femur

Fibula

Tibia



Skull

Maxilla

Mandible

Clavicle

Sternum

Humerus

Ulna

Radius

Coxal  
Bone

Patella

